HPB, 2005; 7: 244–251

Taylor & Francis
Taylor & Francis Group

REVIEW ARTICLES

Hilar cholangiocarcinoma: diagnosis and staging

WILLIAM JARNAGIN[1] & CORINNE WINSTON[2]

Departments of [1]Surgery and [2]Radiology, Memorial Sloan-Kettering Cancer Center, New York, NY, USA

Abstract

Cancer arising from the proximal biliary tree, or hilar cholangiocarcinoma, remains a difficult clinical problem. Significant experience with these uncommon tumors has been limited to a small number of centers, which has greatly hindered progress. Complete resection of hilar cholangiocarcinoma is the most effective and only potentially curative therapy, and it now clear that concomitant hepatic resection is required in most cases. Simply stated, long-term survival is generally possible only with an *en bloc* resection of the liver with the extrahepatic biliary apparatus, leaving behind a well perfused liver remnant with adequate biliary-enteric drainage. Preoperative imaging studies should aim to assess this possibility and must evaluate a number of tumor-related factors that influence resectability. Advances in imaging technology have improved patient selection, but a large proportion of patients are found to have unresectable disease only at the time of exploration. Staging laparoscopy and ^{13}fluoro-deoxyglucose positron emission tomography (FDG-PET) may help to identify some patients with advanced disease; however, local tumor extent, an equally critical determinant of resectability, may be underestimated on preoperative studies. This paper reviews issues pertaining to diagnosis and preoperative evaluation of patients with hilar biliary obstruction. Knowledge of the imaging features of hilar tumors, particularly as they pertain to resectability, is of obvious importance for clinicians managing these patients.

Demographics

Biliary tract cancer affects approximately 7500 Americans each year. Tumors arising from the gallbladder are the most common while those of bile duct origin are less frequently encountered, constituting about 2% of all reported cancers. The advent of new diagnostic methods has led to the preoperative discovery of many more of these lesions, almost certainly misdiagnosed in the past. The majority of patients are greater than 65 years of age, and the peak incidence occurs in the eighth decade of life.

Cholangiocarcinoma may arise anywhere within the biliary tree but tumors involving the biliary confluence (hilar cholangiocarcinoma) are the most common. In several large series published over the past three decades, the proportion of patients with hilar tumors has remained fairly constant at 40–60%, with the remainder arising from intrahepatic biliary radicles or the distal bile duct.

The majority of patients with unresectable bile duct cancer die within 12 months of diagnosis, often from hepatic failure or infectious complications secondary to biliary obstruction. The prognosis has been considered worse for lesions involving the biliary confluence compared with that for distal lesions. This probably reflects differences in resectability and delay often associated with initiating effective therapy for proximal lesions rather than a difference in biologic behavior. Indeed, the available data would suggest that location within the biliary tree (proximal versus distal) does not impact survival, provided that complete resection is achieved [1].

Etiology

Most cases of cholangiocarcinoma are sporadic and the etiology is unclear, especially in Western countries, but several conditions confer an increased risk. Perhaps the most common of these is primary sclerosing cholangitis (PSC), an autoimmune disease characterized by periductal inflammation, ultimately resulting in multifocal strictures of the intrahepatic and extrahepatic bile ducts. Seventy to 80% of patients have associated ulcerative colitis; by contrast only a minority of those with ulcerative colitis develop PSC. The natural history of PSC is variable, and the true incidence of cholangiocarcinoma is unclear. In a series of 305 patients with long-term follow-up, 8% eventually developed cancer [2]. By contrast, occult cholangiocarcinoma has been reported in up to 40% of autopsy specimens and up to 36% of liver explants from patients with PSC. PSC patients appear to be at

Correspondence: William R. Jarnagin, MD, FACS, Department of Surgery, Memorial Sloan-Kettering Cancer Center, 1275 York Avenue, New York, NY 10021, USA. Tel: +1 212 639 7601. E-mail: jarnagiw@mskcc.org

ISSN 1365-182X print/ISSN 1477-2574 online © 2005 Taylor & Francis
DOI: 10.1080/13651820500372533

greater risk for multifocal disease that is not amenable to resection and often have significant underlying hepatic dysfunction that precludes major partial hepatectomy. Distinguishing benign from malignant strictures is particularly challenging in the setting of PSC.

The increased risk of cholangiocarcinoma in patients with congenital biliary cystic disease (choledochal cysts, Caroli's disease) is well described. Malignant degeneration, uncommon in choledochal cysts excised early in life, increases substantially (approximately 15–20%) in patients who are not treated until after the age of 20 years or in those previously treated by cyst drainage. The reason for the high incidence of cancer in patients with cystic diseases is not clear but may be related to an abnormal choledochopancreatic duct junction, predisposing to reflux of pancreatic secretions into the biliary tree, chronic inflammation and bacterial contamination. A similar mechanism may also explain the increased incidence of cholangiocarcinoma after transduodenal sphincteroplasty. In a cohort of 119 patients subjected to this procedure for benign conditions, Hakamada *et al.* found a 7.4% incidence of cholangiocarcinoma over a period of 18 years [3]. There is also evidence to suggest that endoscopic sphincterotomy confers a similar increased risk.

Hepatolithiasis, or recurrent pyogenic cholangiohepatitis, is prevalent in Japan and parts of Southeast Asia and is thought to result from chronic portal bacteremia and portal phlebitis, giving rise to intrahepatic pigment stone formation. Obstruction of intrahepatic ducts leads to chronic, recurrent episodes of cholangitis and stricture formation. Although sepsis is the major threat to life in these patients, approximately 10% will develop cholangiocarcinoma. Biliary parasites (*Clonorchis sinensis, Opisthorchis viverrini*), also prevalent in parts of Asia, are similarly associated with an increased risk of cholangiocarcinoma. In Thailand, where approximately 7 million people are infested with *Opisthorchis*, the annual incidence of cholangiocarcinoma is 87 per 100 000.

Pathological considerations

Knowledge of some of the unique pathologic features of hilar cholangiocarcinoma is important when assessing patients for subsequent therapy. The overwhelming majority are adenocarcinomas, although rarely other malignant cell types may arise primarily in the biliary tree (e.g. carcinoid tumors). It has been suggested that the hilar cholangiocarcinoma is a relatively slow-growing, predominantly locally invasive tumor. However, metastatic disease is not uncommon and disease progression can be rapid in some patients [4]. The liver is a common site of metastasis, but distant spread to other organs at initial presentation, particularly extra-abdominal sites, is atypical. On the other hand, nodal metastases are seen in up to one-third of cases. Following a complete resection, the impact of metastatic disease to hepatoduodenal ligament lymph nodes is unclear, as not all studies have uniformly found an adverse impact on outcome. By contrast, metastatic spread to more distant nodal basins, which can occur in the absence of more proximate nodal involvement, is associated with reduced survival.

By virtue of their location, hilar tumors often invade the liver or perihepatic structures, such as the portal vein or hepatic artery. Given this feature, along with frequent tumor extension to second order biliary radicles, it is not difficult to understand why hepatic resection is usually required for complete tumor clearance [5]. Additionally, concomitant involvement of either the right or left portal vein often results in lobar atrophy, which has important clinical implications, not only for operative planning but also when considering biliary drainage in patients with unresectable disease. Such vascular involvement and lobar atrophy does not always translate into irresectability but it mandates a concomitant partial hepatectomy if resectable and suggests a more locally advanced lesion with an apparent higher likelihood of associated metastatic disease [4,5].

Other characteristics of cholangiocarcinoma include invasive spread with neural, perineural and lymphatic involvement and subepithelial extension. Longitudinal spread along the duct wall and periductal tissues is an important pathologic feature of cholangiocarcinomas. There may be substantial extension of tumor beneath an intact epithelial lining, as much as 2 cm proximally and 1 cm distally. The full tumor extent may thus be underestimated by radiographic studies and may not be appreciated on palpation, underscoring the importance of frozen section analysis of the duct margins during operation to ensure a complete resection.

Grossly, three macroscopic subtypes have been described: sclerosing, nodular and papillary [6]. Sclerosing tumors, the most common, are very firm and cause an annular thickening of the bile duct, often with diffuse infiltration and fibrosis of the periductal tissues. Nodular tumors are characterized by a firm, irregular nodule of tumor that projects into the lumen of the duct. Features of both types are often seen, hence the frequently used descriptor 'nodular-sclerosing'. The papillary variant accounts for approximately 10% of all cholangiocarcinomas, and while occasionally seen at the hilus, is more common in the distal bile duct. These tumors are soft and friable, and may be associated with little transmural invasion. A polypoid mass that expands rather than contracts the duct is a characteristic feature. Although papillary tumors may grow to significant size, they often arise from a well-defined stalk and may be mobile within the bile duct (Figure 1). Recognition of this variant is important since they are more often resectable and less invasive, although it remains to be determined if they have a better prognosis.

Figure 1. (a) PTC image showing hilar biliary ductal obstruction with a large filling defect. Note that the duct is expanded rather than contracted, characteristic of a papillary tumor. (b) Axial CT image showing a well-circumscribed tumor at the biliary confluence (arrows), without apparent invasion of the underlying portal vein. (c) Low power, hematoxylin/eosin-stained section of the resected tumor showing little invasion of the bile duct wall. Reprinted from Annals of Surgery 2005; 241: 703–14, Jarmagin WR et al. Copyright 2005, with permission from Elsevier.

Clinical presentation

The early symptoms of hilar cholangiocarcinoma are often non-specific. Abdominal pain or discomfort, anorexia, weight loss and pruritus are the most common but are seen only in about one-third of patients. Most patients have few symptoms and come to attention because of jaundice or abnormalities on routine blood testing. Although most patients eventually become jaundiced, this finding is not present initially in cases of incomplete biliary obstruction (i.e. right or left hepatic duct). Unilateral obstruction of the proximal right or left hepatic duct may go unrecognized for months, resulting in ipsilateral lobar atrophy without overt jaundice. These patients are often further evaluated and found to have an elevated alkaline phosphatase or gamma glutamyltransferase. In some patients, pruritus precedes jaundice by some weeks, and this symptom should prompt an evaluation, especially if associated with abnormal liver function tests. Patients with papillary tumors may give a history of intermittent jaundice, likely resulting from loose fragments that detach from a friable papillary tumor of the right or left hepatic duct and pass into the common hepatic duct (Figure 1). Alternatively, the main tumor itself, if mobile within the lumen, may cause a ball-valve effect at the hepatic duct confluence. In the absence of previous biliary intervention, cholangitis is uncommon at initial presentation, despite a 30% incidence of bacterial contamination (bacterbilia). On the other hand, the incidence of bacterbilia is nearly 100% after biliary intubation, and cholangitis is more common [7].

The physical findings are often nonspecific but may provide some useful information. Jaundice will usually be obvious. Patients with pruritus often have multiple excoriations of the skin. The liver may be enlarged and firm as a result of biliary tract obstruction. The gallbladder is usually decompressed and nonpalpable with hilar obstruction. Thus, a palpable gallbladder suggests a more distal obstruction or an alternative diagnosis. Rarely, patients with long-standing biliary obstruction and/or portal vein involvement may have findings consistent with portal hypertension.

Diagnosis

The diagnosis of hilar cholangiocarcinoma is usually made on evaluation of obstructive jaundice or elevated liver enzymes. Although a small number of patients are diagnosed before the serum bilirubin rises to clinically apparent levels, progressive and unremitting jaundice is the predominant clinical feature in most cases, and diagnostic investigations are largely related to elucidation of the cause of biliary tract obstruction. Some patients will present with abdominal pain mistakenly attributed to gallstone disease. It is important to remember that gallstones or even common bile duct stones may coexist with bile duct cancer. However, in the absence of certain predisposing conditions, choledocholithiasis infrequently causes obstruction at the biliary confluence. It is therefore imperative to fully investigate and delineate the level and nature of any obstructing lesion causing jaundice to avoid missing the diagnosis of carcinoma.

Most patients are referred after having had some studies done elsewhere, usually a computed tomography (CT) scan and some form of direct cholangiography (PTC or ERCP). These studies are often inadequate for full assessment of the tumor extent. Many patients will have been surgically explored prior to referral, often without reaching a definitive diagnosis. In the absence of previous biliary tract surgery, the finding of a focal stricture involving the proximal biliary tree combined with the appropriate clinical presentation are sufficient for a presumptive diagnosis of hilar cholangiocarcinoma, which is correct in most instances. In a patient with a potentially resectable lesion, histologic confirmation of malignancy should not be considered mandatory prior to exploration (see below).

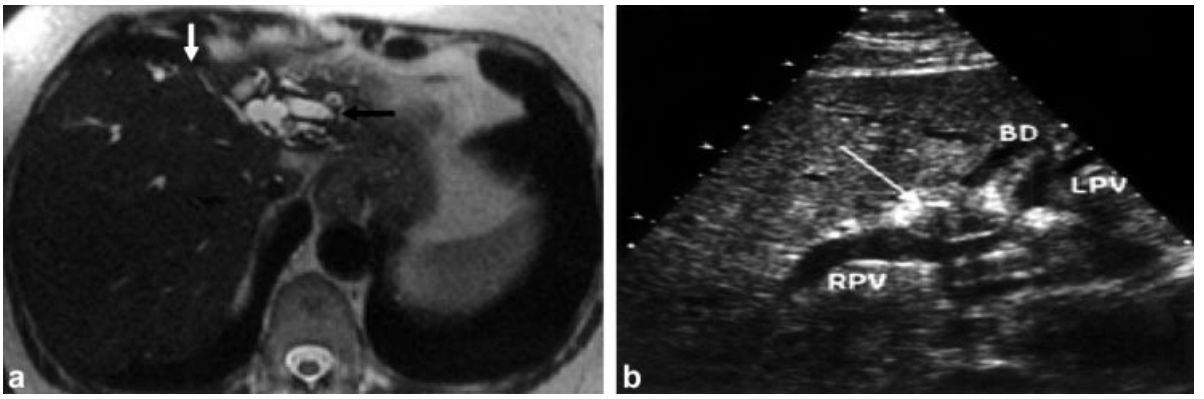

Figure 2. (a) Axial MRCP image of a patient with hilar cholangiocarcinoma and left lobe atrophy. The bile ducts appear white in this image (black arrow). The left liver is shrunken (white arrow), with crowding and dilatation of the bile ducts. (b) Ultrasound image showing the tumor at the biliary confluence (arrow) with severe narrowing of the left portal vein.

Imaging studies

Imaging studies play a critical role in evaluating patients with biliary obstruction and should be directed at fully assessing the extent of disease with a view towards possible resection. In patients with hilar cholangiocarcinoma, evaluation must address four critical components of resectability: (1) level and extent of tumor within the biliary tree; (2) vascular invasion; (3) hepatic lobar atrophy; (4) distant metastatic disease. A combination of studies providing complementary information is typically required to fully assess disease extent. Previously, direct cholangiography and angiography were considered essential studies; however, advances in imaging technology have made it possible to obtain the same information without the need for invasive procedures.

Because of its wide availability, CT is often one of the first studies obtained in patients with suspected biliary tract obstruction. A high-resolution, thin cut CT scan can provide valuable information regarding the level and cause of biliary obstruction and the presence of lobar atrophy and metastatic disease, and can therefore help guide the subsequent evaluation. Also, image interpretation on a PACS (Picture Archive and Communication System) workstation allows consecutive slices to be viewed in cine mode in order to better visualize dilated bile ducts coursing in different planes. In addition, CT angiography has now evolved to the point that assessment of the hilar vascular structures can be done without the need for invasive, direct angiography.

Ultrasonography is frequently overlooked as a useful investigative tool for hilar cholangiocarcinoma; however, in experienced hands, this non-invasive study will demonstrate the level and extent of biliary involvement and also provide information regarding tumor invasion of the periductal tissues. Furthermore, duplex ultrasonography is a highly accurate predictor of vascular involvement and resectability (Figure 2). In patients with malignant hilar obstruction, Hann *et al.* showed that ultrasonography with color spectral Doppler technique was equivalent to angiography and CT portography in diagnosing lobar atrophy, level of biliary obstruction, hepatic parenchymal involvement, and venous invasion [8]. Duplex ultrasonography is particularly useful for assessing portal venous invasion. In a series of 63 consecutive patients from the Memorial Sloan-Kettering Cancer Center, duplex ultrasonography predicted portal vein involvement in 93% of the cases with a specificity of 99% and a 97% positive predictive value. In the same series angiography with CT angio-portography had a 90% sensitivity, 99% specificity and a 95% positive predictive value [9].

Cholangiography is essential for full clarification of disease extent within the biliary tree, clearly critical for surgical planning. Although endoscopic retrograde cholangiography (ERC) may provide some helpful information, percutaneous transhepatic cholangiography (PTC) displays the intrahepatic bile ducts more reliably and is the preferred direct cholangiographic study. More recently, however, magnetic resonance cholangiopancreatography (MRCP) has emerged as a powerful investigative tool. Several studies have demonstrated the utility of MRCP in evaluating patients with biliary obstruction. MRCP may not only identify the tumor and the level of biliary obstruction but may also reveal obstructed and isolated ducts not appreciated on endoscopic or percutaneous studies. MRCP also provides information regarding the presence of metastases and lobar atrophy (Figure 2) and, when combined with MR angiography, can assess involvement of hilar vascular structures [10,11]. Thus, a single imaging modality may provide all of the necessary diagnostic information that previously required multiple studies (Figure 3). Furthermore, since MRCP does not require biliary instrumentation, bacterbilia and its consequent potential for greater perioperative morbidity may be avoided.

Lobar atrophy

Lobar atrophy is not uncommon in patients with hilar cholangiocarcinoma, and its importance cannot be overemphasized, since it often influences therapy [4]. Long-standing biliary obstruction alone may cause

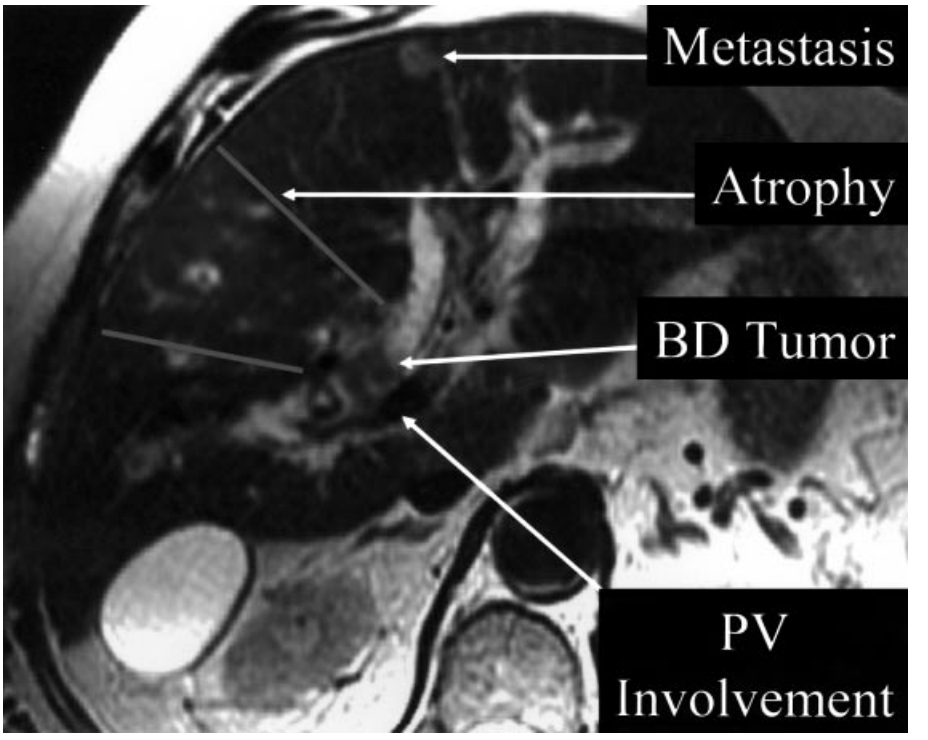

Figure 3. Axial MRCP image of a patient with hilar cholangiocarcinoma. Note that the bile ducts appear white in this image. The tumor in the bile duct is shown, with evidence of portal vein involvement and atrophy of the anterior sector of the right liver (delineated by the two unlabelled lines). An intrahepatic metastasis is also shown.

moderate atrophy, whereas concomitant portal venous compromise induces rapid and severe atrophy of the involved segments. On cross-sectional imaging, atrophy is characterized by a small, often hypoperfused lobe with crowding of the dilated intrahepatic ducts (Figure 2). Lobar atrophy is most often associated with portal venous involvement and generally mandates hepatic resection, if the tumor is resectable. Atrophy is equally important when planning biliary decompression in patients who are not candidates for resection. Drainage of an atrophic, essentially nonfunctional lobe, whether surgical or radiological, will not relieve jaundice and should be avoided unless it is done to control biliary sepsis.

Alternative diagnoses

The vast majority of patients with hilar strictures and jaundice have cholangiocarcinoma. However, alternative diagnoses are possible and can be expected in 10–15% of patients [12]. The most common of these are gallbladder carcinoma, Mirizzi syndrome and idiopathic benign focal stenosis (malignant masquerade). A thickened, irregular and distended gallbladder is typical of gallbladder cancer, which is in contrast to a typically shrunken gallbladder seen with hilar obstruction. Gallbladder carcinoma is also suggested by infiltration into segment IV and V of the liver, selective involvement of the right portal pedicle, or obstruction of the common hepatic duct with occlusion of the cystic duct. Mirizzi syndrome is a benign condition resulting from a large gallstone impacted in the neck of the gallbladder (Figure 4). The ensuing pericholecystic and periductal inflammation and fibrosis can obstruct the proximal bile duct, which is often

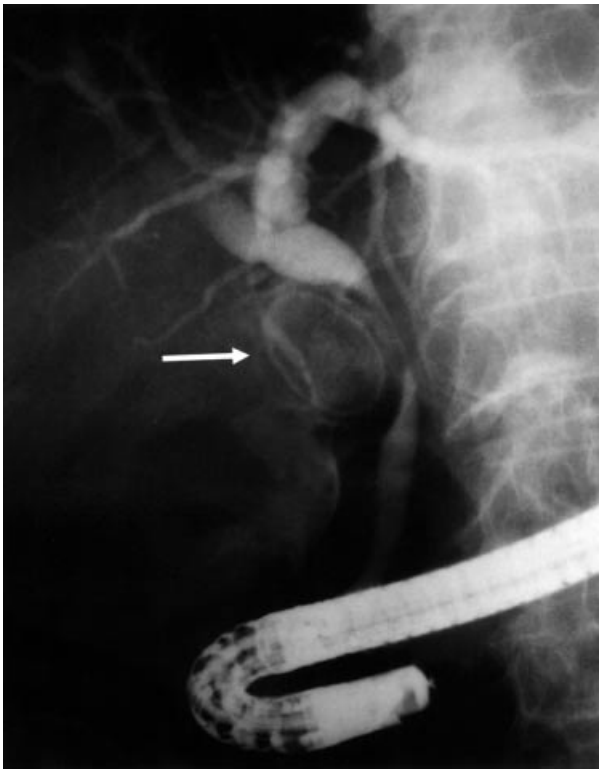

Figure 4. ERCP image of a patient with Mirizzi's syndrome. A gallstone is impacted in the neck of the gallbladder (arrow), causing biliary obstruction.

Table I. Proposed clinical T-stage criteria for hilar cholangiocarcinoma

Clinical stage	Criteria
T1	Tumor involving biliary confluence +/− unilateral extension to secondary biliary radicles
T2	Tumor involving biliary confluence +/− unilateral extension to secondary biliary radicles AND *ipsilateral* portal vein involvement +/− *ipsilateral* hepatic lobar atrophy
T3	Tumor involving biliary confluence + bilateral extension to secondary biliary radicles; OR unilateral extension to secondary biliary radicles with *contralateral* portal vein involvement; OR unilateral extension to secondary biliary radicles with *contralateral* hepatic lobar atrophy; OR main portal vein involvement

Reprinted from ref. no. 4 by permission of the publisher.

difficult to distinguish from a malignant cause; also, it must be recognized that gallbladder cancer can coexist with Mirizzi syndrome.

Benign focal strictures (malignant masquerade) can occur at the hepatic duct confluence but are uncommon. A smooth, tapered stricture on cholangiography suggests a benign stricture but this is by no means diagnostic, and hilar cholangiocarcinoma must remain the leading diagnosis until definitively disproved. In most cases, this cannot be done without exploration. In fact, the alternative conditions that one may encounter are best assessed and treated at operation. Relying on the results of percutaneous needle biopsy or biliary brush cytology is dangerous, since they are often misleading and the opportunity to resect an early cancer may be missed. In the absence of clear contraindications, exploration is indicated in all patients with suspicious hilar lesions.

Preoperative evaluation, staging, assessment of resectability

Evaluation of patients with hilar cholangiocarcinoma is principally an assessment of resectability, since resection is the only effective therapy. First and foremost, the surgeon must assess the patient's general condition and fitness for a major operation that usually includes partial hepatectomy. The presence of significant comorbid conditions, chronic liver disease and/or portal hypertension generally precludes resection. In these patients, biliary drainage and histological confirmation of the diagnosis are most appropriate if non-operative treatment is anticipated (i.e. chemotherapy, radiation therapy). Patients with potentially resectable tumors occasionally present with biliary tract sepsis, most commonly after prior intubation of the biliary tree. These patients require resuscitation and treatment of infection before surgery can be considered; this often requires placement of additional biliary catheters to drain contaminated, isolated liver segments.

Currently, there is no clinical staging system available that stratifies patients preoperatively into subgroups based on potential for resection. The modified Bismuth–Corlette classification [5] stratifies patients based only on the extent of biliary involvement by tumor, and the AJCC staging system is based largely on pathological criteria and has little applicability for preoperative staging. Neither is useful for predicting resectability and survival. Recently, the authors have proposed a preoperative staging system, using data from preoperative imaging studies, based on local, tumor-related factors that determine resectability: biliary ductal involvement, vascular involvement and lobar atrophy [4]. This clinical T-staging scheme categorizes patients from least to most locally advanced by taking into account all factors related to local tumor extent and correlates closely with resectability and survival (Table I). In an analysis of 225 patients with hilar cholangiocarcinoma, resectability was nearly 60% in T1 tumors, 31% in T2 tumors and 0% of T3 tumors (Table II). Survival likewise decreased with increasing clinical T stage. On the other hand, there was no correlation with survival and stage based on the AJCC classification. In addition, and perhaps more importantly, the likelihood of distant metastatic disease increased with more locally advanced lesions (i.e. higher clinical T stage—see below).

Table II. Stratified by T stage

T stage	*n*	Explored with curative intent	Resected	Negative margins	Hepatic resection	Portal vein resection	Metastatic disease	Median survival
1	87	73 (84%)	51 (59%)	38	33	2	18 (21%)	20 months
2	95	79 (83%)	29 (31%)	24	29	7	40 (43%)	13 months
3	37	8 (22%)	0	0	0	0	15 (41%)	8 months
Total	219	160 (71%)	80 (37%)	62	62	9	73 (33%)	16 months

Six patients had incomplete data and could not be accurately staged. The percentages indicate the proportion of patients within each stage grouping or of the total number of patients. Metastatic disease refers to metastases to N2 level lymph nodes or to distant sites. Median survival was calculated for all patients, including those who died perioperatively. Reprinted from ref. no. 4 by permission of the publisher.

Table III. Criteria of unresectability

Patient factors
Medically unfit or otherwise unable to tolerate a major operation
Hepatic cirrhosis
Local tumor-related factors
Tumor extension to secondary biliary radicles bilaterally
Encasement or occlusion of the main portal vein proximal to its bifurcation
Atrophy of one hepatic lobe with contralateral portal vein branch encasement or occlusion
Atrophy of one hepatic lobe with contralateral tumor extension to secondary biliary radicles
Unilateral tumor extension to secondary biliary radicles with contralateral portal vein branch encasement or occlusion
Metastatic disease
Histologically proven metastases to lymph nodes beyond the hepatoduodenal ligament*
Lung, liver, or peritoneal metastases

* Metastatic disease to peripancreatic, periduodenal, celiac, superior mesenteric or posterior pancreaticoduodenal lymph nodes was considered to represent disease not amenable to a potentially curative resection. By contrast, metastatic disease to cystic duct, pericholedochal, hilar or portal lymph nodes (i.e. within the hepatoduodenal ligament) did not necessarily constitute unresectability. Reprinted from ref. no. 4 by permission of publisher.

Long-term survival with hilar cholangiocarcinoma depends critically on a complete resection with histologically negative resection margins. Proper patient selection requires high quality, complementary imaging studies and careful consideration of all of the available data. The authors' criteria of unresectable disease are outlined in Table III [4]. Distant metastatic disease, advanced cirrhosis, bilateral tumor extension to second order intrahepatic biliary radicles and encasement or occlusion of the main portal vein clearly preclude resection. In general, however, the individual determinants of resectability must be considered within the context of all findings, and in so doing, the importance of portal vein involvement and liver atrophy in relation to the extent of ductal cancer spread becomes evident. Thus, ipsilateral involvement of the portal vein and bile ducts may be amenable to resection whereas contralateral involvement is usually not. Likewise, ipsilateral lobar atrophy does not preclude resection, whereas atrophy of the contralateral lobe does.

While imaging studies will identify many patients with unresectable disease, a significant proportion are found to have unresectable disease only at the time of laparotomy. As a result, staging laparoscopy has been used increasingly to reduce the incidence of unnecessary open explorations. In a recent analysis of 56 patients with potentially resectable tumors on radiologic grounds, laparoscopy identified unresectable tumors in 14 (25%) [13]. The yield was significantly higher for patients with more locally advanced tumors (clinical T2/T3, as discussed above) (12/33, 36%) compared to those with clinical T1 tumors (2/23, 9%), which is almost certainly related to the higher incidence of metastatic disease in the former group. Laparoscopy detected the majority of patients with peritoneal or liver metastases, but failed to detect most locally unresectable tumors. Laparoscopic detection of irresectability based on vascular involvement and biliary tumor extent is particularly difficult in patients with biliary stents. Despite this limitation, however, laparoscopic staging appears to have a role in these patients.

FDG-PET scanning may be a useful adjunct to standard imaging but has not been fully evaluated in patients with hilar cholangiocarcinoma, although the few existing reports have suggested a potential role. In one of the larger series to date, Kluge *et al.* evaluated 26 patients with proximal and distal tumors, 8 patients with benign strictures and 20 control patients [14]. This study showed that FDG-PET has excellent sensitivity (92.3%) and specificity (92.9%) with respect to identifying the primary lesion, identified distant metastatic disease in 7 of 10 patients but was relatively ineffective for identifying regional nodal disease (2/15). FDG-PET may thus be of some value in distinguishing benign from malignant strictures and may identify some patients with metastatic disease not apparent on cross-sectional imaging.

The role of preoperative biliary drainage in jaundiced patients remains controversial. In practice, most patients undergo biliary drainage prior to referral for resection, despite the lack of data showing a benefit. In the authors' experience, many patients are ineffectively and/or inappropriately drained before referral, often leading to complications that delay treatment. Clearly, the presence of cholangitis mandates biliary decompression but there is no proof that routine biliary drainage in all patients facilitates resection or reduces post-surgical morbidity. On the contrary, there is some suggestion that biliary stents are associated with greater postoperative infective complications [7]. Previous studies investigating this issue have been criticized for a number of flaws, and whether major hepatic resection in the face of biliary obstruction is associated with a greater risk of liver failure or other complications remains an open question. Several centers, particularly in Japan, have a fundamentally different view, taking a very detailed approach to defining resectability based on aggressive direct cholangiography of segmental ducts, often with multiple drainage catheters, and

cholangioscopy [15]. This approach may offer an advantage with respect to improving resectability rates but a clear-cut improvement in perioperative outcome has not been definitively shown.

References

[1] Nagorney DM, Donohue JH, Farnell MB, Schleck CD, Ilstrup DM. Outcomes after curative resections of cholangiocarcinoma. Arch Surg. 1993;128:871–9.

[2] Broome U, Olsson R, Loof L, Bodemar G, Hultcrantz R, Danielsson A, et al. Natural history and prognostic factors in 305 Swedish patients with primary sclerosing cholangitis. Gut. 1996;38:610–15.

[3] Hakamada K, Sasaki M, Endoh M, Itoh T, Morita T, Konn M. Late development of bile duct cancer after sphincteroplasty: a ten- to twenty-two-year follow-up study. Surgery. 1997;121: 488–92.

[4] Jarnagin WR, Fong Y, DeMatteo RP, Gonen M, Burke EC, Bodniewicz BJ, et al. Staging, resectability, and outcome in 225 patients with hilar cholangiocarcinoma. Ann Surg. 2001; 234:507–17.

[5] Bismuth H, Nakache R, Diamond T. Management strategies in resection for hilar cholangiocarcinoma. Ann Surg. 1992; 215:31–8.

[6] Weinbren K, Mutum SS. Pathological aspects of cholangiocarcinoma. J Pathol. 1983;139:217–38.

[7] Hochwald SN, Burke EC, Jarnagin WR, Fong Y, Blumgart LH. Association of preoperative biliary stenting with increased postoperative infectious complications in proximal cholangiocarcinoma. Arch Surg. 1999;134:261–6.

[8] Hann LE, Fong Y, Shriver CD, Botet JF, Brown KT, Klimstra DS, et al. Malignant hepatic hilar tumors: can ultrasonography be used as an alternative to angiography with CT arterial portography for determination of resectability? J Ultrasound Med 1996;15:37–45.

[9] Bach AM, Hann LE, Brown KT, Getrajdman GI, Herman SK, Fong Y, et al. Portal vein evaluation with US: comparison to angiography combined with CT arterial portography. Radiology 1996;201:149–54.

[10] Schwartz LH, Coakley FV, Sun Y, Blumgart LH, Fong Y, Panicek DM. Neoplastic pancreaticobiliary duct obstruction: evaluation with breath-hold MR cholangiopancreatography. Am J Roentgenol. 1998;170:1491–5.

[11] Lee MG, Park KB, Shin YM, Yoon HK, Sung KB, Kim MH, et al. Preoperative evaluation of hilar cholangiocarcinoma with contrast-enhanced three-dimensional fast imaging with steady-state precession magnetic resonance angiography: comparison with intraarterial digital subtraction angiography. World J Surg. 2003;27:278–83.

[12] Wetter LA, Ring EJ, Pellegrini CA, Way LW. Differential diagnosis of sclerosing cholangiocarcinomas of the common hepatic duct (Klatskin tumors). Am J Surg. 1991;161:57–62.

[13] Weber SM, DeMatteo RP, Fong Y, Blumgart LH, Jarnagin WR. Staging laparoscopy in patients with extrahepatic biliary carcinoma. Analysis of 100 patients. Ann Surg. 2002;235:392–9.

[14] Kluge R, Schmidt F, Caca K, Barthel H, Hesse S, Georgi P, et al. Positron emission tomography with [(18)F]fluoro-2-deoxy-D-glucose for diagnosis and staging of bile duct cancer. Hepatology 2001;33:1029–35.

[15] Nimura Y, Kamiya J, Kondo S, Nagino M, Uesaka K, Oda K, et al. Aggressive preoperative management and extended surgery for hilar cholangiocarcinoma: Nagoya experience. J HBP Surg. 2000;7:155–62.