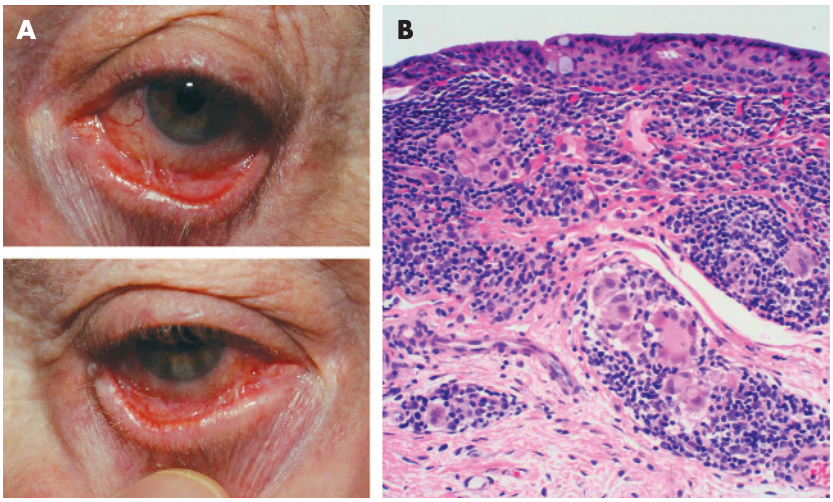

Figure 1 Cicatrising granulomatous conjunctivitis. (A) Right and left eyes of the patient on presentation. (B) Haematoxylin and eosin staining of conjunctival biopsy specimen showing multinucleated giant cells (×200). Informed patient consent was received for publication of this figure.

ing a prednisolone taper relieved the injection and irritation. In the absence of a topical prednisolone taper, the injection continued for over 2 weeks, at which time a prednisolone taper was prescribed with quick and successful resolution. Given the prompt development of severe conjunctivitis with several different drops, we hypothesised that the preservative in each of these drops may be causative. All these drops are preserved with BAC, except the generic timolol eye drops, which are preserved with dodecyltrimethylammonium bromide. This is also a quaternary ammonium salt preservative. Our hypothesis was further supported when a trial of preservative-free Timoptic Ocudose 0.5% (Merck) did not cause any ocular irritation.

Comment

Ocular drug allergies are fairly common and have a wide range in severity. Allergies to preservatives such as BAC have been noted, and reports of a severe form of drug-induced conjunctival reaction have been published and referred to as pseudopemphigoid. However, published biopsy results had not previously indicated the presence of non-caseating granulomas in association with pseudopemphigoid. Our patient responded well to removal of the offending stimulus (BAC) and short-term treatment with a topical steroid, even though it was also preserved with BAC. We speculate that the potency of the steroid (1% prednisolone acetate suspension) was sufficient to overcome the reactivity of the preservative.

The use of multiple topical drops in the treatment of glaucoma is quite common, but few preservative-free drops are available. Greater availability of preservative-free drops would be beneficial to patients sensitive to preservatives.

Alon Kahana, Marcus M Marcet, Daniel M Albert
Department of Ophthalmology and Visual Sciences, University of Wisconsin, Madison, Wisconsin, USA

Andrew T Thliveris
Department of Ophthalmology and Visual Sciences, The William Middleton Veterans Hospital, University of Wisconsin, Madison, Wisconsin, USA

Correspondence to: Dr A Kahana, Department of Ophthalmology and Visual Sciences, University of Wisconsin, 600 Highland Avenue, Madison, WI 53792, USA; kahana@wisc.edu

doi: 10.1136/bjo.2006.099085
Accepted 1 July 2006

Funding: None.

Competing interests: None declared.

Informed consent was received from the patient for publication of their details in this report.

References

1 **Noecker R**. Effects of common ophthalmic preservatives on ocular health. *Adv Ther* 2001;**18**:205–15.
2 **Patten JT**, Cavanagh HD, Allansmith MR. Induced ocular pseudopemphigoid. *Am J Ophthalmol* 1976;**82**:272–6.
3 **Fiore PM**, Jacobs IH, Goldberg DB. Drug-induced pemphigoid: a spectrum of diseases. *Arch Ophthalmol* 1987;**105**:1660–3.
4 **Bernauer W**, Broadway DC, Wright P. Chronic progressive conjunctival cicatrisation. *Eye* 1993;**7**:371–8.
5 **Gibran SK**. Unilateral drug-induced ocular pseudopemphigoid. *Eye* 2004;**18**:1270.
6 **Fernandes M**, Vemuganti GK, Pasricha G, *et al.* Unilateral tuberculous conjunctivitis with tarsal necrosis. *Arch Ophthalmol* 2003;**121**:1475–8.

Orbital mesenchymal hamartoma with rhabdomyomatous features

Rhabdomyomatous mesenchymal hamartoma (RMH) is a subcutaneous lesion that is

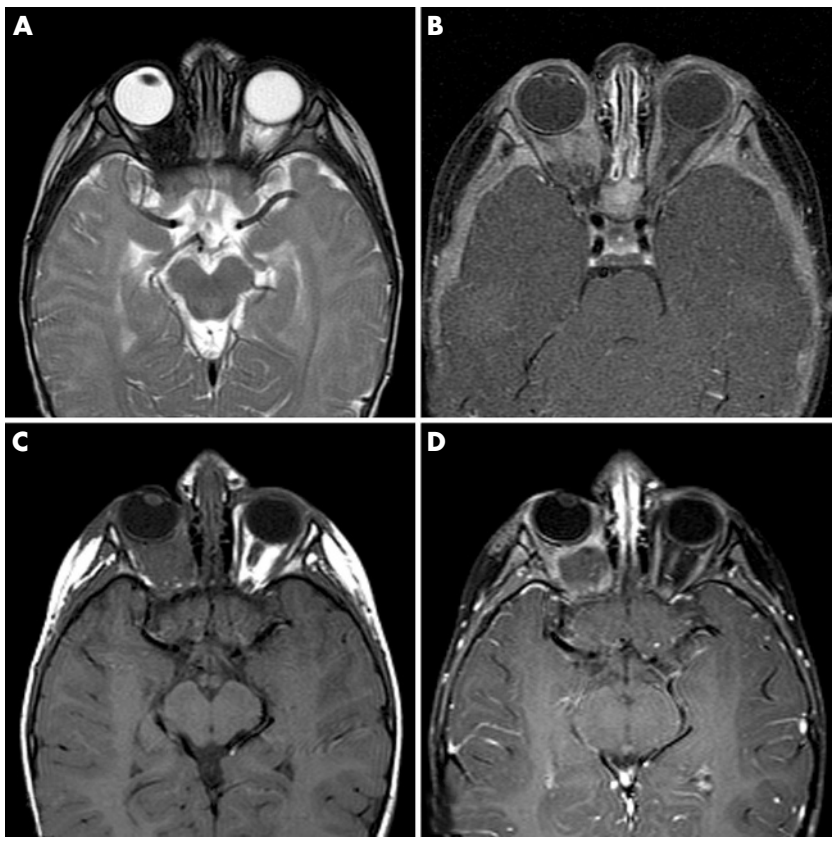

Figure 1 (A,B) Magnetic resonance imaging with gadolinium of the brain and orbit, at age 5-months, revealed a diffuse infiltrative retrobulbar intraconal lesion extending to the superior orbital fissure, and demonstrating marked T2 hypointensity, and avid, fairly homogeneous enhancement on the post-gadolinium T1 fat saturated axial scan. (C,D) Repeat MRI scan 18 months later revealed an increase in the lesion size, further expansion of the orbit, and enlargement of the superior orbital fissure. The mass remained isointense to surrounding extraocular muscles on T1-weighted imaging, hypointense on T2-weighted imaging (not shown), with peripheral enhancement seen on the T1 fat saturated axial post-gadolinium scan.

characterised by a normal epidermis overlying a dermis that contains randomly arranged mature striated muscle fibers associated with varying amounts of mesenchymal elements such as adipose tissue, collagen and blood vessels. Herein we report a mesenchymal hamartoma with rhabdomyomatous features occurring in the orbit.

Case report

A 2-year-old boy was referred to the clinic with a history of right unilateral axial proptosis presenting on the fourth day of life with no useful vision ipsilaterally. Two orbital biopsies had been performed, the first being unsuccessful, and the second showing haphazardly arranged skeletal muscle fibers and fibrous tissue. On examination, he had no light perception OD, ptosis, fixed extraocular movements, and a pale atrophic optic disc. Ultrasound features included a solid, well-outlined highly reflective mass that was indenting the globe. Magnetic resonance imaging with gadolinium of the brain and orbit, at 5 months, revealed a diffuse infiltrative retrobulbar intraconal lesion. A repeat scan 18 months later, revealed an increase in the size of the lesion and the orbit (fig 1). The initial differential diagnoses included mesenchymal hamartoma, benign soft-tissue neoplasm, and granular cell tumour.

Due to the loss of vision, relentless increase in the size of the lesion, orbit, and superior orbital fissure, the patient underwent an eyelid and conjunctival sparing exenteration with lateral orbitotomy and a dermis fat graft.[1] During surgery, the tumour felt firm and solid. The case was complicated by cerebrospinal fluid (CSF) leak one day postoperatively originating from the superior orbital fissure even though temporalis muscle with Tisseal® was used to patch the fissure intraoperatively. A lumbar drain inserted for 1 day resolved the CSF leak with no further complications. Histologic features are displayed in fig 2.

Two months later, the patient was fitted with an ocular prosthesis with good cosmetic outcome. He will undergo ptosis surgery in the future.

Comment

RMH was first described as striated muscle hamartoma in 1986 by Hendrick et al[2] Since then, 30 cases of RMH have been recognized and reported in the literature.[3–8] It is commonly seen in infants or young children and appears at birth. Clinically it presents as a firm, flesh-coloured, nontender, polypoid, solitary subcutaneous lesion, at or near the midline, without prominent change in size. Specific congenital anomaly syndromes associated with RMH include Goldenhar and Delleman syndromes.[3]

In our case the histology was similar to that described for RMH; however it occurred in the orbit rather than the usual dermal and subcutaneous region. To our knowledge, this is the first such tumour reported in a non-subcutaneous site.

The possibility of a benign Triton tumor was also considered but in these lesions the nerve and muscle tissue is intimately admixed as the muscle fibers are thought to have been entrapped within the nerve sheaths during development. As the main component of this tumour was skeletal muscle, with lesser contributions by peripheral nerve and adipose tissue, we are presenting this case as a unique occurrence of an orbital mesenchymal hamartoma with rhabdomyomatous features.

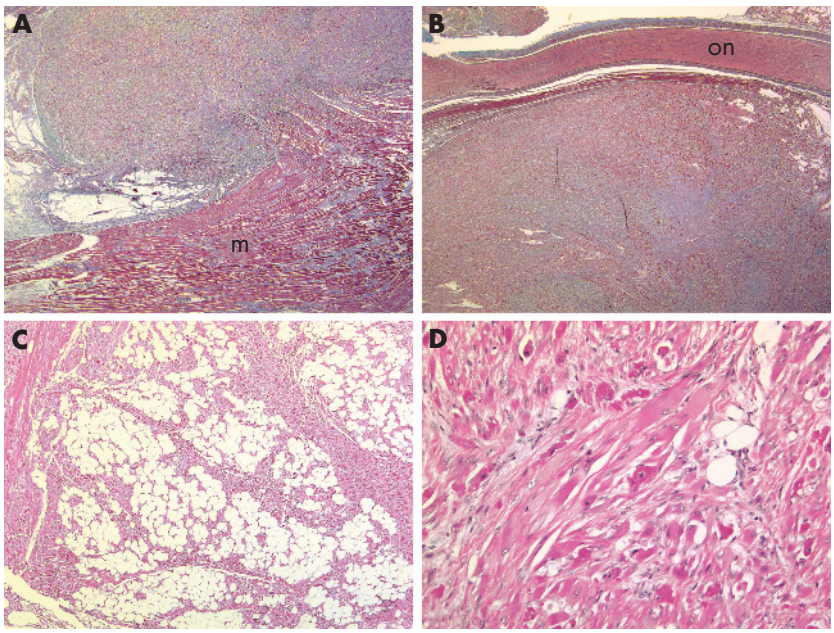

Figure 2 (A) The mass was composed predominantly of disorganized skeletal muscle which surrounded and infiltrated the extraocular muscles (m) (Trichrome stain, ×4), (B) compressed the optic nerve (on) (Trichrome stain, ×4) and, (C,D) infiltrated the adipose tissue (H&E stain, ×10, ×40). Adipose tissue and peripheral nerves were admixed with the muscle tissue in varying amounts throughout the lesion. We diagnosed this lesion as a hamartoma on the basis of presentation shortly after birth with slowly progressive growth associated with expansion of the orbit and its histologic resemblance to normal skeletal muscle. We used these features to differentiate it from a rhabdomyosarcoma which would have had rapid growth and be histologically composed of small, undifferentiated cells with little cytoplasm, a high mitotic rate and would lack an intimate admixture with adipose tissue and peripheral nerves.

I Mavrikakis, V A White
Department of Ophthalmology and Visual Sciences, University of British Columbia, Vancouver, BC, Canada

V A White
Department of Pathology and Laboratory Medicine, University of British Columbia, Vancouver, BC, Canada

M Heran
Department of Radiology, University of British Columbia, Vancouver, BC, Canada

J Rootman
Department of Ophthalmology and Visual Sciences, University of British Columbia, Vancouver, BC, Canada; Department of Pathology and Laboratory Medicine, University of British Columbia, Vancouver, BC, Canada

Correspondence to: Jack Rootman, Professor of Ophthalmology & Pathology, University of British Columbia, Vancouver General Hospital, 2550 Willow Street, Vancouver, BC, Canada, V5Z 3N9; jrootman@interchange.ubc.ca

doi: 10.1136/bjo.2006.099747

Accepted 4 August 2006

Informed consent has been obtained from the patient for the publication of their details.

Competing interests: none.

References

1 **Looi A**, Kazim M, Cortes M, *et al.* Orbital reconstruction after eyelid- and conjunctiva-sparing orbital exenteration. *Ophthal Plast Reconstr Surg* 2006;**22**:1–6.
2 **Hendrick SJ**, Sanchez RL, Blackwell SJ, *et al.* Striated muscle hamartoma: description of two cases. *Pediatr Dermatol* 1986;**3**:153–7.
3 **Read RW**, Burnstine M, Rowland JM, *et al.* Rhabdomyomatous mesenchymal hamartoma of the eyelid: report of a case and literature review. *Ophthalmology* 2001;**108**:798–804.
4 **Rosenberg AS**, Kirk J, Morgan MB. Rhabdomyomatous mesenchymal hamartoma: an unusual dermal entity with a report of two cases and a review of the literature. *J Cutan Pathol* 2002;**29**:238–43.
5 **Magro G**, Di Benedetto A, Sanges G, *et al.* Rhabdomyomatous mesenchymal hamartoma of oral cavity: an unusual location for such a rare lesion. *Virchows Arch* 2005;**446**:346–7.
6 **Ortak T**, Orbay H, Unlu E, *et al.* Rhabdomyomatous mesenchymal hamartoma. *J Craniofac Surg* 2005;**16**:1135–7.
7 **Takeyama J**, Hayashi T, Sanada T, *et al.* Rhabdomyomatous mesenchymal hamartoma associated with nasofrontal meningocele and dermoid cyst. *J Cutan Pathol* 2005;**32**:310–3.
8 **Chang CP**, Chen GS. Rhabdomyomatous mesenchymal hamartoma: a plaque-type variant in an adult. *Kaohsiung J Med Sci* 2005;**21**:185–8.

Ecstasy induced acute bilateral angle closure and transient myopia

A case of ecstasy (3,4-methylenedioxymethamphetamine (MDMA)) misuse in a previously emmetropic healthy man, who presented with acute bilateral angle closure and transient myopia after 2 weeks of consumption, is reported. Ultrasound biomicroscopy revealed bilateral ciliochoroidal effusions suggesting the mechanism of the adverse event. The episode resolved spontaneously. Ecstasy misuse needs to be considered as a possible cause in patients presenting with acute angle closure with choroidal effusion when no other known class of prescription drugs can be implicated.

MDMA, known as ''ecstasy,'' has become increasingly popular as a recreational drug over