ELECTRON MICROSCOPIC STUDIES OF MENINGIOMAS

JOHN KEPES, M.D.

From the Department of Pathology and Oncology, University of Kansas Medical Center, Kansas City, Kans.

Electron microscopy in diseases of the nervous system represents a relatively new field in pathology. The first studies of the central nervous system by this means were undertaken 5 to 6 years ago with the description of the submicroscopic structure of the normal brain and spinal cord. Whereas many outstanding papers have been concerned with the electron microscopic findings in inflammatory, degenerative and, particularly, demyelinating disorders of the nervous system, the first important study of brain tumors was published recently by Luse.[1] In this work certain electron microscopic features of a large group of brain tumors, including astrocytomas, oligodendrogliomas, ependymomas, glioblastomas, papillomas of the choroid plexus, meningiomas, neurolemmomas, and neurofibromas, were discussed.

In the present investigation I have concentrated on the submicroscopic features of meningioma. In this connection 3 features were regarded to be of particular interest: (a) the finer structure of the meningothelial tumor cells; (b) the mechanisms involved in the formation of whorls and psammoma bodies; (c) the origin of meningothelial cells. The question also arose whether details revealed by electron microscopy might shed light on the problem of the neuroectodermal versus the mesenchymal origin of meningiomas.

MATERIAL AND METHODS

Fourteen meningiomas removed by surgery were examined. Immediately after removal, the tissue was cut into small blocks with diameters not exceeding 1 mm. Even while cutting, the tissue was submerged in freshly prepared cold 2 per cent osmic acid fixative buffered to pH 7.5 by sodium veronal buffer and preserved by adding 0.147 mg. of sucrose per 3 ml. of fixative. The tissues were then fixed at 4° C. for one hour. This was followed by dehydration with graded concentrations of ethyl alcohol. The absolute alcohol in the series contained 1 per cent phosphotungstic acid. The blocks were infiltrated with methacrylate and embedded in 10/90 methylbutyl methacrylate with added "Luperco (CDB)" catalyst (50 per cent 2,4,-dichlorobenzoyl peroxide with dibutyl phthalate; prepared by the Lucidol Division of Wallace and Tiernan, Inc.) to promote polymerization. Sections cut on Porter-Blum microtomes with glass and diamond knives were mounted on copper grids covered with carbon. Some sections were stained with 2 per cent uranyl nitrate to increase contrast. Finally, the sections were examined in an RCA 3B electron microscope.

This work was supported by United States Public Health Service Grant No. H-4879.
Accepted for publication, June 2, 1961.

Sections for light microscopy were taken from the same tumors. These were fixed in 10 per cent formol, embedded in paraffin and stained with hematoxylin and eosin and by the van Gieson, Masson, and the Gomori trichrome methods, the periodic acid-Schiff (PAS) and elastica stains, and by the Gordon-Sweet reticulin impregnation method. Histologically, most tumors belonged to the meningothelial variety of meningiomas, 2 were of the so-called fibroblastic variety. None of the 14 neoplasms examined appeared to be malignant.

Results and Discussion

The Fine Structure of the Tumor Cells

The meningothelial cells varied in shape from round to elongated forms. Cell membranes were well-defined in most areas. Luse[1] emphasized that the complex plicated interdigitating plasma membranes of these cells caused the indistinct appearance of cell boundaries with light microscopy. We have also encountered such interdigitation, but there were just as many areas where the cell membranes were linear and quite straight. An occasional cell exhibited a straight cell membrane facing one of its neighbors, while having interdigitations with other adjacent cells (Fig. 1). The nuclei were sharply delineated, with a well-defined nuclear membrane. The chromatin in most nuclei was finely granular and evenly distributed, without conspicuous clumping. This was in accordance with the "vesicular" appearance of most meningothelial cells when viewed with light microscopy. Of the intracytoplasmic structures, mitochondria and endoplasmic reticulum displayed no unusual features.

The most characteristic finding consisted of the abundance of fine fibrils in the cytoplasm. These fibrils were of equal thickness and arranged for the most part in parallel bundles with occasional criss-crossing (Figs. 2 and 3). Their density around the nucleus and in the periphery of the cell was about equal. The use of 1 per cent phosphotungstic acid (PTA) in the alcohol series made the fibrils particularly conspicuous. One of Luse's illustrations[1] showed that she too had encountered these fibrils in meningothelial cells.

In studies based on light microscopy there was a certain controversy about the existence of intracellular fibrils in meningothelial cells. Mallory[2] described cytoplasmic fibrillary structures in meningioma tumor cells which he called "fibroglia" and regarded as indicative of the fibroblastic nature of these cells. Bailey,[3] however, claimed that fibroglia fibers were present only in fibroblasts mixed with the real meningothelial cells, and that the latter did not possess such structures.

It is not easy to differentiate between elongated meningothelial cells and fibroblasts. According to Bailey's criteria, however, the central core of a cellular whorl (i.e., the innermost cells) should be accepted as true

meningothelial cells. At the periphery of the whorl, fibroblasts may join the laminated structure.

The present studies, however, showed the existence of these fibers in every cell of the whorls, including the innermost ones and even the central cell if the whorl was built around such a tumor cell rather than a blood vessel or other structure. The existence of fibroglia or "desmofibrils" in meningothelial cells has been debated. On the other hand, they could be impregnated with silver salts by Costero and associates [4,5] in tissue cultures from meningiomas. Romhanyi,[6] using polarizing microscopic methods, expressed a belief in the existence of submicroscopic fibrils in meningioma cells. Electron microscopy thus verifies this indirect assumption based on the appearance of meningiomas in polarized light. With the electron microscope the fibrils were present in every meningioma examined, in the meningothelial as well as the fibroblastic varieties. Of course the fibers impregnated by Costero and co-workers undoubtedly represented greatly condensed elementary fibrils.

The function of these fibrils is not apparent, and one may only speculate on this matter. They probably have a supportive function and also, possibly, a role in the formation of the cellular whorls. Wherever cells in such whorls were examined, the intracytoplasmic fibrils followed the curve and spiral of the cell body. There were also cells which apparently were not participating in whorl formation; the external shape of these was unremarkable, yet inside the cytoplasm a marked whorling of the fibrils could be observed (Fig. 4). A similar arrangement of fibrils was seen in the central cells of whorls.

It appears that this phenomenon is probably the first expression of the whorling tendency in a meningothelial cell. The intracellular alteration, undetected by light microscopy, would be followed later by participation of the whole cell body in the building of a whorl. This finding is in accordance with the view of Kersting and Lennarzt [7] who observed the whorl formation in tissue cultures of meningiomas. They stated that the whorl was initiated by the deformity of a single cell, which became the center of the whorl. Naturally, this view requires modification somewhat when considered *in vivo,* where whorls can develop around blood vessels or collagen fibers. At any rate, I suggest that the "cell deformation" noted by Kersting and Lennarzt begins at the submicroscopic level.

Why does the whorling of the fibrils occur? There are two possible answers to this question. One is that streams and currents develop in the semifluid substance of the cytoplasm and the whorling of the fibrils is simply a visible expression of these changes. The other possibility is that the fibrils themselves have an inherent tendency, possibly due to their

molecular structure, to form whorls and in turn cause the whole cell to participate in whorl formation.

The Mechanism of the Psammoma Body Formation from the Whorls

According to information gained by light microscopy, the whorls are first entirely cellular; later their centers become hyalinized and eventually calcified. The occasional production of spherical proteinaceous bodies (pseudopsammoma bodies) by the meningothelial cells without collagen fibers or a tendency for calcification has been described in another paper.[8] In low power electron micrographs the cellular whorls were easily recognizable, and in some of these (Fig. 5) no evidence of degeneration of the central cell was seen.

As for the whorls with "hyalinized" centers, these centers looked more or less homogeneous under the light microscope, but they were far from homogeneous with electron microscopy. A mixture of elements derived from the cytoplasm (mitochondria with thick membranes and poorly defined cristas, and fragments of cytoplasmic fibrils) were observed, as were collagen fibers of varying thickness, recognized by their characteristic banding. The cytoplasmic membrane of the cells immediately lining this area was more or less fragmented, with a continuity existing between the interior of the cell and extracellular cytoplasmic particles and collagen fibers (Figs. 6 to 8). In some instances, dense amorphous particles were encountered in the centers of the whorls. These were morphologically analogous to structures described by Luse[1] in oligodendrogliomas. She was of the opinion that these represented early foci of calcification in oligodendrogliomas, and the same explanation seems likely in our case—i.e., the particles represented early calcium deposits in psammoma bodies.

As for the origin of the elements in the center of the whorls, the cytoplasmic structures evidently were derived from the neighboring cells. They became extracellular because of cellular degeneration and the breakdown of cell membranes.

The Origin of Collagen Fibers in the Whorls

The presence of collagen fibers in the middle of the whorls raises a more difficult question. Where do collagen fibers in meningiomas come from? It is true that an occasional whorl may develop around a preexisting collagen fiber or, perhaps, a bundle of fibers, but it is a generally accepted notion that initially "pure" cellular whorls eventually develop hyalinized centers, as a process of aging. As has been shown, the hyalinization indicates an admixture of collagen fibers and degenerating cells. These fibers then had to develop within the whorls. Their central location

would certainly relate them to the innermost cell of the whorls, the very cell Bailey[3] and others have recognized as the typical meningothelial cell.

The exact manner of collagen formation is not, as yet, exactly known. Electron microscopic studies by Porter and Pappas[9] in the chick embryo dermis suggested that the formation of collagen fibers was closely related to the cell membranes of fibroblasts. In 3-dimensional pictures produced by shadow casting, a blending of collagen fibers into the ectoplasm of the fibroblasts could be observed. More recently, Yardley, Heaton, Gaines and Shulman[10] described the formation of collagen in tissue culture of chick embryo heart fibroblasts. They found "marginal condensation" or "marginal filaments" in the cytoplasm of fibroblasts which in their opinion were related to the formation of collagen. These active fibroblasts had a loss of definite outer cell membrane. They also described intracytoplasmic fibrils in the fibroblasts and named them "endoplasmic condensation."

The cytoplasmic fibrils found in the meningothelial cells were at least morphologically analogous to the "endoplasmic condensation" of fibroblasts described by Yardley and co-workers.[10] They were also very similar to the intracytoplasmic fibrils described by Hama in mesothelial cells.[11] Marginal fibrils or condensation were not encountered, but in some sections (Fig. 9) the collagen fibers were very closely adjacent to the tumor cells. They ran parallel with the long axis of the cell and the intracytoplasmic fibrils, and appeared to be blending with the cell membrane which was focally indistinct.

In favor of collagen formation by meningothelial cells we can thus list (a) the development of collagen (particularly of young thin fibers) in areas completely surrounded by meningothelial cells, usually in the centers of whorls; and (b) tumor cells with indistinct cell membranes with very closely adjacent collagen fibers. We do not know whether or not the "marginal condensations" described by Yardley and co-workers[10] in tissue cultures are also features of human fibroblastic activity *in vivo*. They were not found in meningothelial cells, and this could be held against an assumption of their fibroblastic activity. Future studies of the formation of collagen in human connective tissue and in fibromas may give a better basis for comparison. Apart from this, the development of collagen in the center of meningothelial whorls suggests the ability of meningothelial cells to produce collagen *in vivo*. Benedek and Juba,[12] Morley,[13] and, in their very elaborate study, Costero, Pomerat, Jackson and Barroso-Moguel[4] noted the fibroblast-like characteristics of meningothelial cells in tissue culture. According to our present findings, these

characteristics can be observed in the tumor cells even without the dedifferentiation that occurs in tissue cultures.

Summary

Fourteen surgically removed meningiomas were examined with the electron microscope. The boundaries between the tumor cells were straight in some areas, interdigitating in others. The fine structure of the tumor cells of the meningothelial variety was not different from cells in "fibroblastic" meningiomas. A common feature of the meningothelial cells was the presence of fine intracytoplasmic fibrils. The whorling of these fibrils was observed in several tumor cells, and it was assumed that this represented the first visible expression of the whorling tendency of these cells.

Whorls with central "hyalinization" were associated with a breakdown of the cytoplasmic membrane in the innermost cells and an admixture of collagen fibers with degenerating cellular elements.

The development of collagen fibers in an area completely surrounded by meningothelial cells indicated the probability that these elements possessed fibroblastic activity. Collagen fibers running parallel and closely adjacent to the cell membrane of the tumor cells supported this notion. Although the cells failed to exhibit all the morphologic criteria of fiber formation observed in tissue cultures of fibroblasts, our findings suggest that meningothelial cells are a specialized variety of connective tissue cells with a collagen-producing propensity.

References

1. Luse, S. A. Electron microscopic studies of brain tumors. *Neurology*, 1960, **10**, 881–905.
2. Mallory, F. B. The type cell of the so-called dural endothelioma. *J. Med. Res.*, 1920, **41**, 349–364.
3. Bailey, O. T. Histologic sequences in the meningioma, with a consideration of the nature of hyperostosis cranii. *Arch. Path.*, 1940, **30**, 42–69.
4. Costero, I.; Pomerat, C. M.; Jackson, I. J., and Barroso-Moguel, R. Tumors of the human nervous system in tissue culture. I. The cultivation and cytology of meningioma cells. *J. Nat. Cancer Inst.*, 1955, **15**, 1319–1339.
5. Costero, I.; Pomerat, C. M.; Barroso-Moguel, R., and Chevez, A. Z. Tumors of the human nervous system in tissue culture. II. An analysis of fibroblastic activity in meningiomas. *J. Nat. Cancer Inst.*, 1955, **15**, 1341–1365.
6. Romhanyi, G. Histopathologic studies on submicroscopic structure of fibers. *Orvosok lapja*, 1947, **3**, 1569–1574.
7. Kersting, G., and Lennarzt, H. *In vitro* cultures of human meningioma tissue. *J. Neuropath. & Exper. Neurol.*, 1957, **16**, 507–513.
8. Kepes, J. Observations on the formation of psammoma bodies and pseudopsammoma bodies in meningiomas. *J. Neuropath. & Exper. Neurol.*, 1961, **20**, 255–262.

9. PORTER, K. R., and PAPPAS, G. D. Collagen formation by fibroblasts of the chick embryo dermis. *J. Biophys. & Biochem. Cytol.*, 1959, **5**, 153–166.

10. YARDLEY, J. H.; HEATON, M. W.; GAINES, L. M., JR., and SHULMAN, L. E. Collagen formation by fibroblasts: preliminary electron microscopic observations using thin sections of tissue cultures. *Bull. Johns Hopkins Hosp.*, 1960, **106**, 381–393.

11. HAMA, K. The fine structure of the desmosomes in frog mesothelium. *J. Biophys. & Biochem. Cytol.*, 1960, **7**, 575–578.

12. BENEDEK, L., and JUBA, A. Meningeom- und Gliom-Gewebskulturen. *Ztschr. ges. Neurol. u. Psychiat.*, 1942, **174**, 493–503.

13. MORLEY, T. P. The morphology of meningiomas grown in culture. *J. Neuropath. & Exper. Neurol.*, 1958, **17**, 635–643.

I wish to express my thanks to Dr. Peter Rasmussen, Assistant Professor of Pathology, University of Kansas Medical Center, for his valuable help and advice in the field of electron microscopy, and to Dr. William P. Williamson, Professor of Neurosurgery, for kindly supplying the operative specimens.

[*Illustrations follow*]

Legends for Figures

Key:

N = nucleus
F = intracellular fibril
CB = cell border
CO = collagen
M = mitochondria
CA = calcium

Fig. 1. Meningothelial meningioma. Cell boundaries are straight in some areas and interdigitating in others. The straight cell borders cause the "epithelioid" appearance with conventional light microscopy; the interdigitating membranes are not readily resolved at such magnification and give the impression of syncytium formation. × 5,400.

Fig. 2. A single meningothelial cell, showing many intracytoplasmic fibrils. Phosphotungstic acid stain. × 17,000.

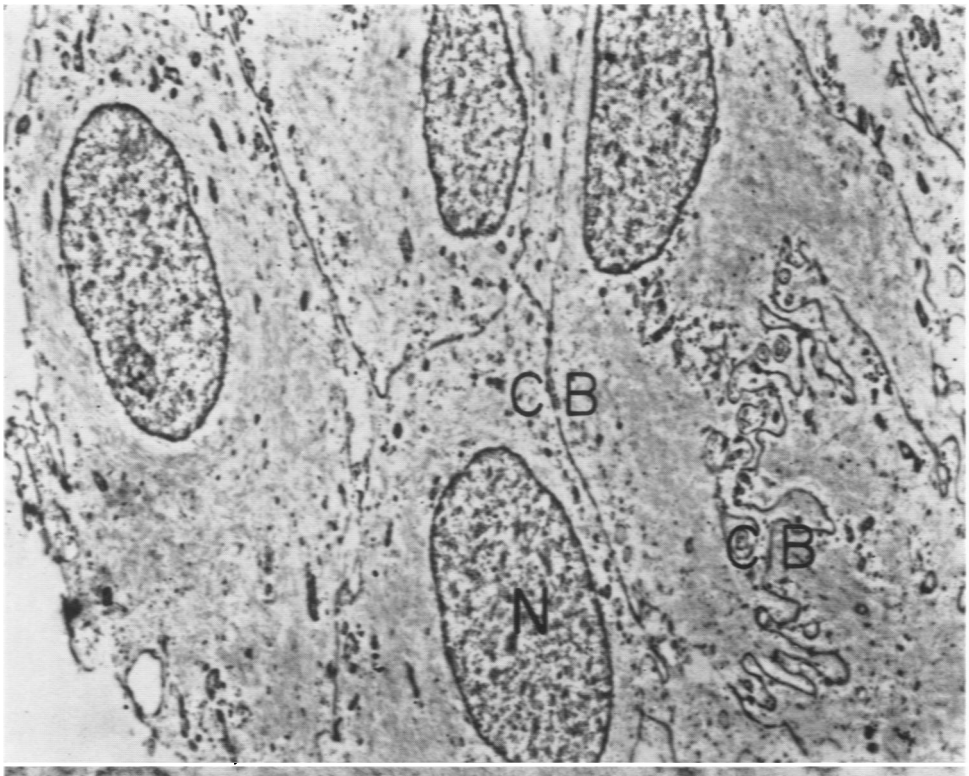

1

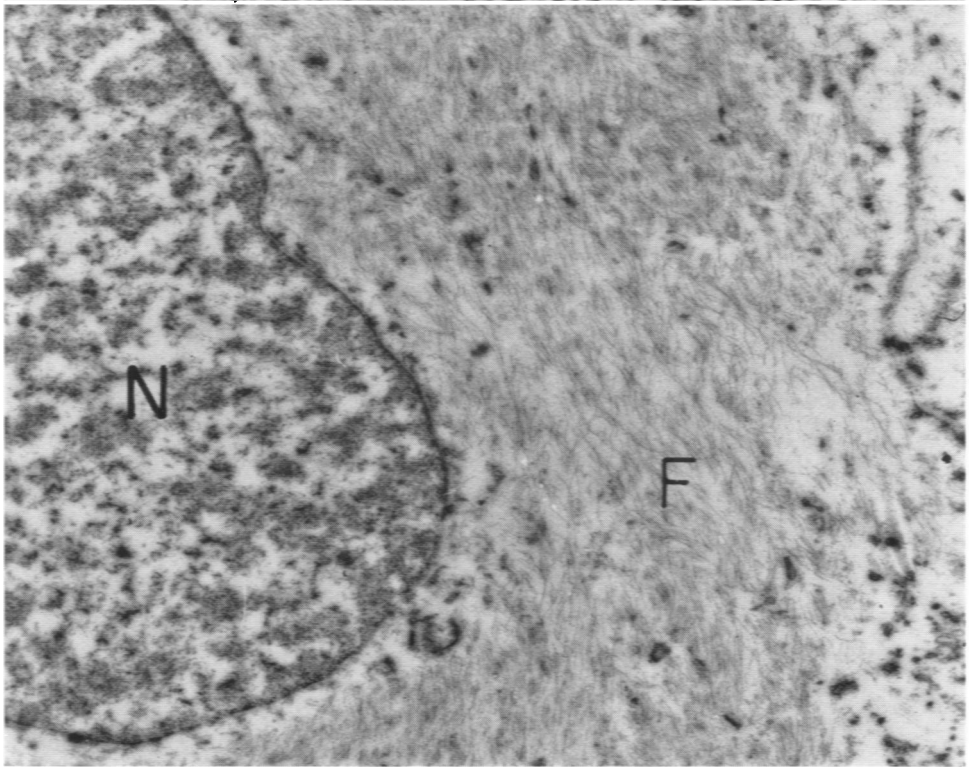

2

3

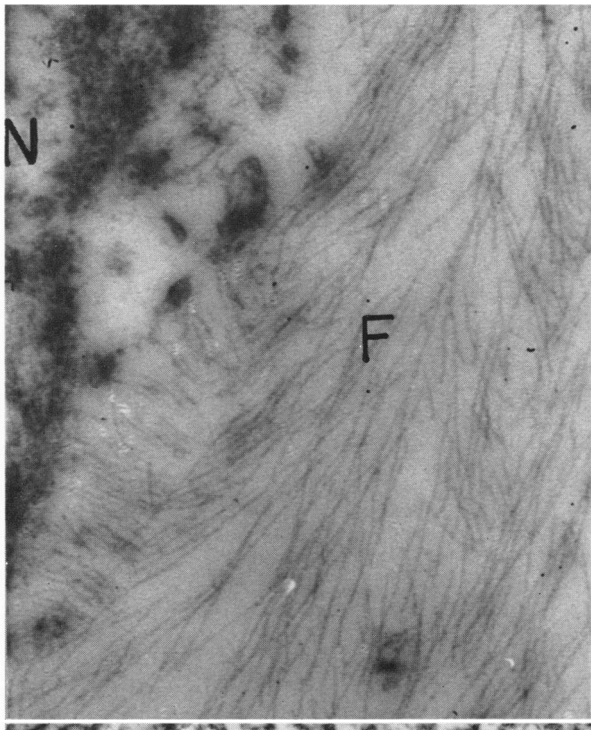

5

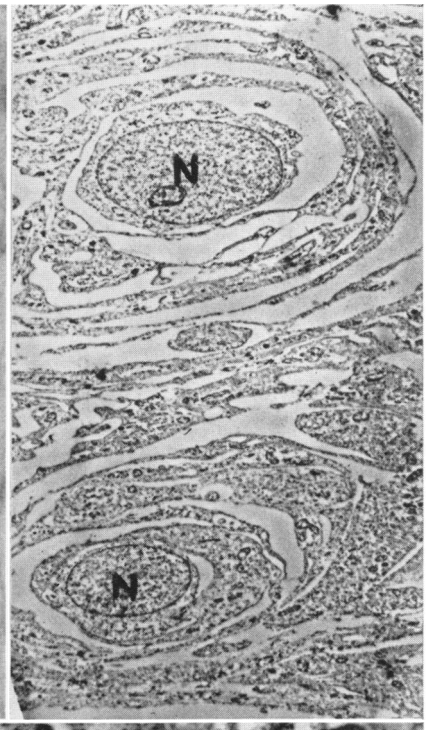

4

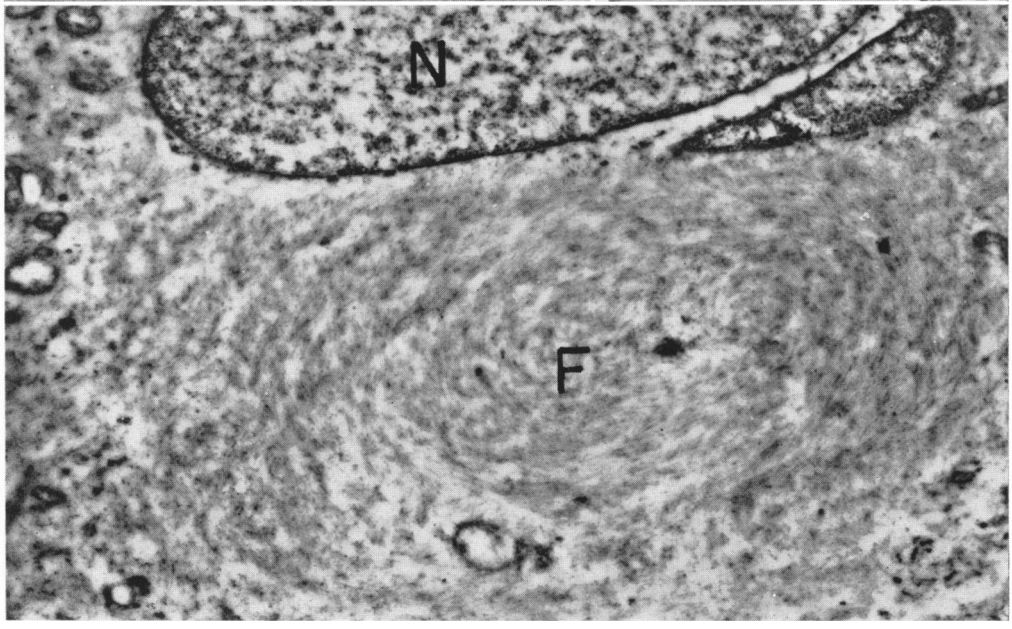

FIG. 3. A higher magnification of the same cell shown in Figure 2. × 65,000.

FIG. 4. The nucleus of this cell is displaced to its periphery. The cytoplasm contains whorling and spiraling fibrils. This arrangement of the fibrils is probably the first visible expression of the whorling tendency of the meningothelial cell. × 15,000.

FIG. 5. A low power electron micrograph of two cellular whorls. No central degeneration is present. × 5,000.

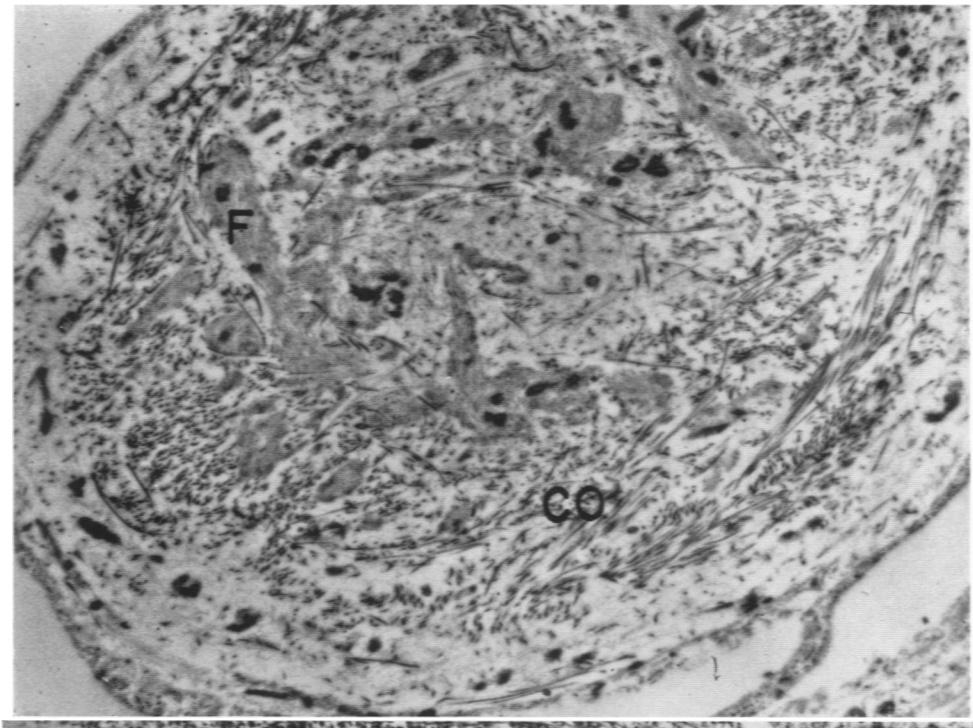

6

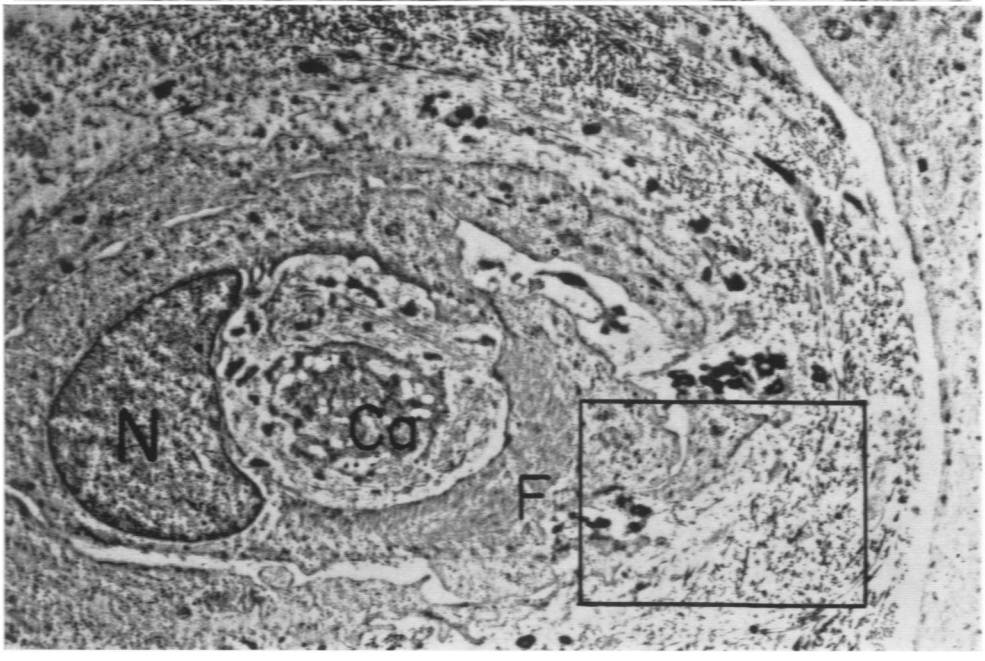

7

FIG. 6. The center of a "hyalinizing" whorl shows a mixture of collagen fibers and structures derived from the cytoplasm, i.e., degenerating mitochondria and bundles of intracytoplasmic fibrils. × 6.000.

FIG. 7. The cells surrounding the center of this whorl show a partial breakdown of their membranes. The center is occupied by amorphous dark clusters, probably early deposits of calcium. × 4.000.

8

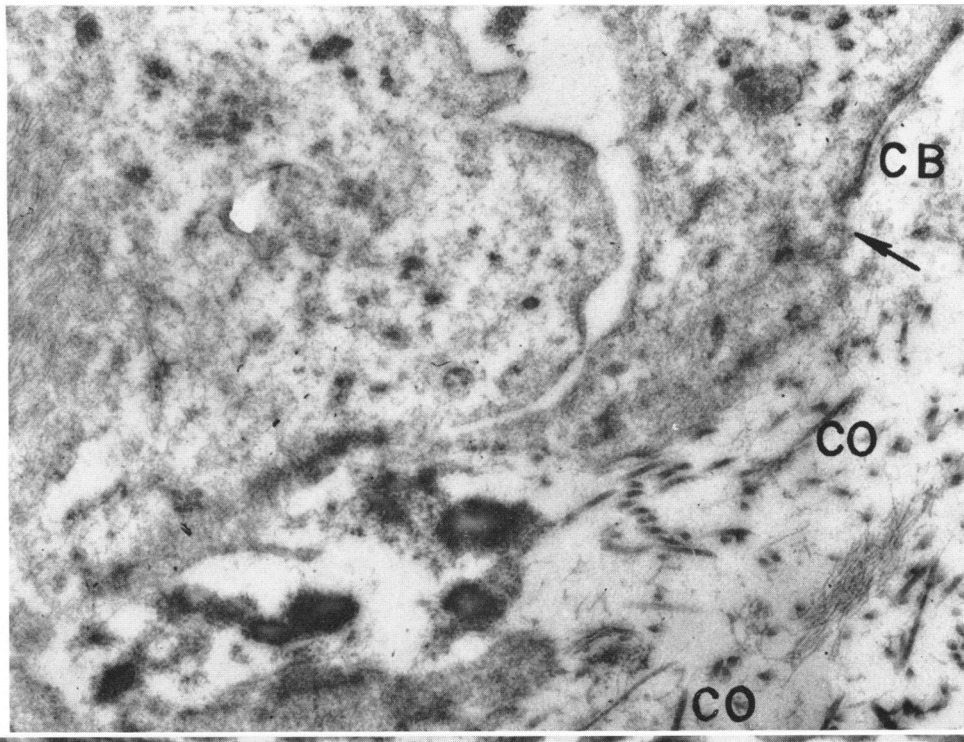

9

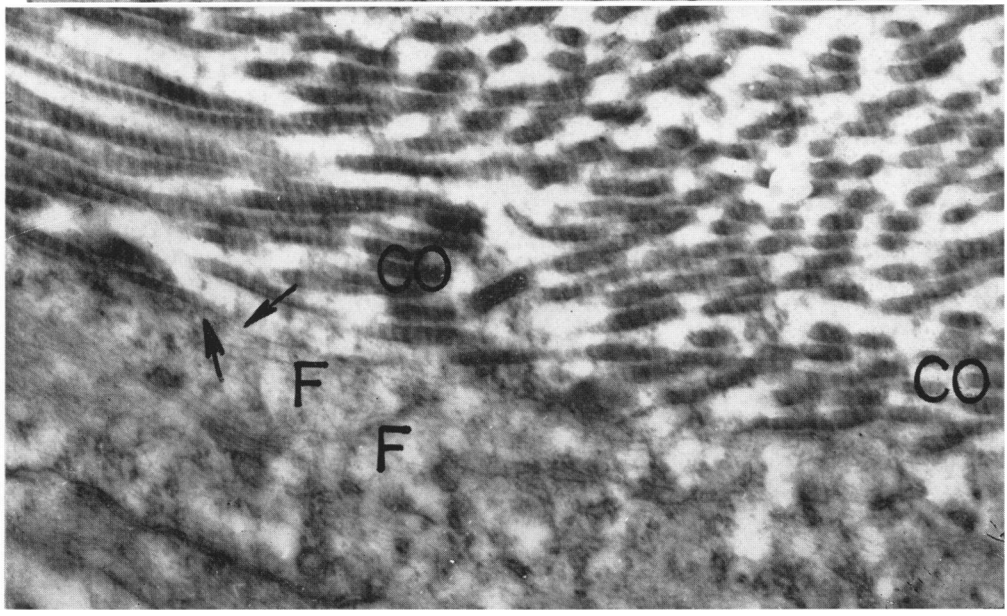

FIG. 8. Higher magnification of the area shown in Figure 7. There is a mixture of collagen fibers and degenerating cytoplasmic elements. The breakdown of the cell membrane is clearly seen (arrow). × 28,000.

FIG. 9. Collagen fibers are closely adjacent to the cell membrane of this meningothelial tumor cell. The fibers appear to blend with the cell wall which is somewhat indistinct in a few segments (arrows). × 27,000.