INFECTIONS OF THE MOUTH, PHARYNX AND UPPER RESPIRATORY TRACT*

JOHN D. KERNAN

Professor of Otolaryngology, College of Physicians and Surgeons, Columbia University

ACUTE PYOGENIC INFECTION OF THE TONGUE

HOWEVER important the tongue may be in its other relations to life and surgery, as the site of acute pyogenic infections it plays no great role. Only thirty cases of abscess of the tongue were reported in American and foreign literature in the 10 years between 1920 and 1930. In the last 10 years there have been only ten cases treated at the Presbyterian Hospital and Babies Hospital.

Various reasons are given for this immunity of the tongue. The covering epithelial layer is peculiarly thick and resistant. Surface infections do not enter easily. The blood supply of the tongue is very great, so that threatening bacteria are promptly attacked and destroyed. The structure of the tongue, almost solidly muscle, lacking connective tissue, gives pus no chance to spread. All these circumstances make tongue abscess rare.

Nevertheless, occasional cases do occur. Most of the cases start, not primarily from surface wounds of the tongue, but secondarily from acute infections of the tonsils. The usual history is that, several days after subsidence of an acute sore throat, pain begins in one side of the tongue. This increases gradually in severity, accompanied by swelling which may become so great as to interfere with breathing and swallowing. The usual constitutional symptoms of acute infections are present in varying degree. No one infecting organism is found exclusively. Streptococci are likely to predominate in the early abscesses, but later a mixture of many organisms will be found, with very foul pus being produced. As a rule the infection is limited to one side of the tongue, not penetrating the median raphe. When situated in the forward part, interference with breathing is caused by blocking of the

* Presented October 21, 1940 at the Graduate Fortnight of The New York Academy of Medicine.

mouth and the crowding upward of the soft palate into the nasopharynx. If, however, the abscess is situated at the base, even though the swelling of the tongue may not be great, an accompanying edema of the larynx may threaten asphyxia.

The treatment in the early stages consists of hot irrigations and the use of antiseptic mouth washes. It must be remembered that there is great difficulty in swallowing in these cases, so it will be necessary to combat dehydration and starvation. Later, surgical interference will be called for. The abscesses well forward in the body of the tongue present no difficulty. A large incision and the placing of an adequate drain results in prompt relief. The abscesses at the base of the tongue are very difficult to reach for the placing of an incision. The swelling of the tongue makes both the use of a laryngeal mirror and a direct laryngeal speculum difficult. I have had experience with two lingual abscesses. One was situated in the body of the tongue, well forward on the right side. No difficulty was had in draining it. The other was at the base of the tongue, seemingly having started as an acute lingual tonsillitis. There was early edema of the larynx which called for scarification through the direct speculum. This abscess itself gave much more difficulty. The pain was great and swallowing was almost impossible. Only such a sloping surface could be exposed that an incision with a straight laryngeal knife through a direct speculum could not be made. It was thought at one time that an external submental incision, dissecting through the body of the tongue, would be necessary. Finally an incision was made with a right-angled laryngeal knife, guided by a mirror. This resulted in prompt relief.

Sublingual Abscesses

These abscesses are for the most part secondary to bad teeth. Occasionally one will occur in connection with a calculus impacted in the sublingual duct, but this is rare. No one organism predominates but ultimately, as in all abscesses about the mouth, the pus will be foul. The course of development is that, pus having formed about the root of a tooth, the abscess ruptures through the bone into the floor of the mouth above the mylohyoid ridge, forming a swelling just under the mucous membrane. This situation is more likely to come about in connection with the incisors and canines than with the more posterior teeth. It must be remembered that the sublingual space communicates about the

posterior edge of the mylohyoid muscle with the submaxillary space so the pus may not be limited to the floor of the mouth, but may invade the neck as well. Another etiology must be mentioned. Since the introduction of local anesthesia by the injection of various solutions, a number of these abscesses develop following the extraction of teeth.

Whatever the course of development the symptoms are much the same. There is painful swelling under the tongue on one side which pushes that structure upward and backward, embarrassing breathing and swallowing. If the infection spreads beneath the jaw, a tender swelling develops in that region. The condition calls for adequate incision as soon as the pus can be localized. The drainage should be preferably into the mouth. If, however, submaxillary infection has developed, an external incision must be made parallel to the ramus of the jaw, displacing the submaxillary gland and thoroughly opening the submaxillary space.

It is necessary to describe here that inflammation of the floor of the mouth known as Ludwig's angina. This has such peculiar features that for many years it was described as a separate disease though there were always to be found eminent authorities who disputed that position, maintaining that it was only a form of submaxillary abscess.

Ludwig's[1] paper, published in 1836, gives an excellent description, not since surpassed. The infection arises as a rule in a decayed tooth or follows an extraction. The sickness begins with a slight fever, chills, fatigue, loss of appetite. A hard, painful swelling develops on one or both sides of the neck about the submaxillary gland, rarely about the sublingual or parotid. This hard swelling is the characteristic symptom. It progresses under the maxilla to the chin, perhaps to the opposite side, up over the jaw to the zygoma, down the neck to the clavicle, to the pharynx, to the larynx, to all the cellular and muscular tissue between the larynx and the mouth cavity. The tongue rests on a hard leathery mass which in the mouth feels like a hard ring along the borders of the maxilla. The patient can open the mouth only with distress and pain, speaking with difficulty partly from pressure on the larynx, and partly because the smaller throat muscles are affected. Swallowing becomes difficult on account of mechanical pressure.

For the first 4 or 5 days the general condition of the patient is fair. As the disease progresses, the skin over the swelling begins to redden, then some spots become soft, sink in, and give a feeling to the finger touching them as if there were air forming under the skin. Active

eruption of pus seems about to occur but this does not happen. At this stage, in the mouth cavity a part breaks through either in back toward the root of the tongue, or more often at the inner side of the maxilla, and an exceedingly foul, thin greyish or brownish red fluid is expelled. From then on there is rapid progress of the toxic symptoms, with death on the tenth or twelfth day in coma.

In some cases at autopsy the skin and immediately underlying cellular tissue were found unchanged. The deeper tissue was found to have disintegrated into a grey-black mass full of air bubbles. The salivary glands were unchanged. This suggests that the interstitial pressure is so great as to cause gangrene.

Ludwig's angina is summarized as follows:

1. Comparatively slight inflammation of the throat itself
2. Peculiar "woody" hardness of the cellular tissue
3. Hard swelling under the tongue with swelling of the floor of the mouth on the inner border of the mandible, with red and sometimes bluish coloration
4. Progress of swelling with well-defined border of hard edema in the neck
5. Slight infection or absence of infection in regional lymph nodes while swelling continues in surrounding cellular tissue

This statement of Ludwig that the lymph nodes were not affected is of great interest since there has been some dispute as to this. Price,[2] reporting on five cases in an article published in the *Annals of Surgery* in 1908, stated that the infiltration travels by the lymphatic spaces and by contiguity. In a discussion of Price's paper, G. D. Davis disagreed with Price as to the transmission by lymphatics. He stated that, although there are lymphatics in profusion along the deep vessels of the neck, no large lymph nodes are found in this disease. Grodinsky[3] in a very complete article published in *Surgery* in 1939 appears to demonstrate satisfactorily that the spreading is by fascial planes. This seems to be generally accepted by modern authors.

The treatment of Ludwig's angina has travelled the complete circuit from medical through surgical procedures and now seems about to become medical again. Ludwig reported one patient who was cured after 3 weeks by extensive blood letting, caustic applications to the swelling itself, very strong emetics, diet, and cataplasms. By 1885 surgi-

cal treatment was firmly established. A. Barker[4] published a paper in the *Lancet* in that year in which he reported two cases with recovery. He recommended early incision in the midline combined with free stimulation, the use of quinine and ferruginous tonics. Price, in his article already cited,[2] recommended very extensive incisions over the submaxillary triangles through the mylohyoid muscles, also in the midline between the hyoid bone and symphysis to the mucous membrane. If the sublingual tissues were very edematous, Price suggested that the mucous membrane be incised from the midline to the second molar tooth, then that a curette be inserted and the tissue curetted wherever there was a feeling of the tissue giving away. Four of his five patients recovered.

Rehn[5] in 1922 expressed dissatisfaction with the generally recommended therapy of early and extensive incision from the outside. He lost three successive patients treated by that method. He recommended complete extirpation of the submaxillary gland.

Medical treatment was again hinted at in an article by Blassingame,[6] in the *Memphis Medical Journal* in 1938. He suggested that sulfanilamide might influence the disease in the very early stages. Once necrosis had set in, however, he believed surgical drainage must be employed.

Hendricks[7] expressed active dissatisfaction with surgical results. He reported one patient who died, although operated on within 24 hours of the onset of the disease. A second patient recovered on whom a tracheotomy was done at once and then drainage incision made. A third patient recovered on sulfanilamide alone. He thinks the possibilities of sulfanilamide therapy should be more vigorously investigated.

Leonardo[8] reported twenty-one cases. This gave a rate of one case in 3630 hospital admissions. He insisted on very complete incision through the mylohyoid muscle, followed by the use of sulfanilamide postoperatively. This gave a mortality of 5 per cent. Thomas[9] reported 40 per cent mortality in 106 cases.

However the use of sulfanilamide may ultimately influence this disease, undoubtedly the best present treatment is by early and very extensive incisions, the neck being explored until the abscess is found and freed. The results at the Presbyterian Hospital bear this out.

Experience at Presbyterian Hospital

In the past ten years there have been twenty-eight cases classified as Ludwig's angina at the Presbyterian Hospital. Reading the history

TABLE I

SUMMARY OF 28 CASES OF LUDWIG'S ANGINA

SEQUENTIAL TO		TREATMENT	
Extraction of teeth	14	Pus released by incision	21
Sore throat	3	Incised, no pus found	3
Tongue abscess	1	Subsided without incision	4
Bad teeth	8	Total	28
Barber's itch	1		
Mastoidectomy	1	Died	2
Total	28		

and the examination of these cases one must conclude that there is a tendency at the present time to call all sublingual and submental inflammations Ludwig's angina. None of these cases strictly conform to the description originally given by Ludwig. They do not show the board-like hardness which he mentions and in most of them, when incised, a localized abscess was found. On the other hand perhaps we may conclude that the cases Ludwig described were in reality submaxillary abscesses which were not treated surgically and hence went on to a fatal termination. In any event, the treatment in this series has been much more successful than in many hitherto reported (Table I).

INFECTIONS OF THE LYMPHOID TISSUE OF THE TONGUE AND NASOPHARYNX

The lingual tonsils may be the site of quite as severe an infection as the faucial tonsils, though this is much more rare. In itself such an attack, even though caused by a streptococcus, is not as a rule serious. It must be remembered, however, that the infection is close to the larynx and may occasionally give rise to an embarrassing edema. It is probable, moreover, that some of the rare lingual abscesses begin as a lingual tonsillitis. It is necessary therefore to treat such infections with care. As a rule they improve quickly with local applications. Appropriate chemotherapy should of course be used.

INFECTIONS IN THE NASOPHARYNX

Occasionally a streptococcal infection will lodge in the nasopharynx. These patients will be very sick, not only on account of the distressing

local symptoms but because the toxemia is severe. There is, moreover, always the threat of an otitis media and its sequelae. Examination with a postnasal mirror will show the whole posterior wall of the nasopharynx to be plastered with membrane. Local treatment is difficult and the condition has been found to be very persistent. The use of chemotherapy may greatly alter this picture.

Infections of the Tonsils and their Sequelae

I shall limit my discussion to acute infections of the tonsils and their more important sequelae. Any discussion of diphtheria will also be omitted.

The tonsils are distributing points of infection. Secondary to tonsillitis any part of the respiratory tract, or the ears may be invaded. It has already been pointed out that an abscess of the tongue may be related to a tonsillar infection. The tonsils being distributors of infection, any means of limiting infection to them alone should certainly be used. Chemotherapy is one of these means. Our experience at the Presbyterian Hospital has been this, that sulfanilamide for instance, does not make much change in the ordinary course of a tonsillitis but that the complications are fewer when it is used. Once a complication has ensued, such as a peritonsillar abscess, surgical treatment will be indicated. Even then the drug should be continued after operation. The experience of Rhoads and Afremow[10] at the Cook County Hospital and Evanston Hospital has been less favorable. Treating thirty-one patients with sulfanilamide, thirty-six patients untreated being controls, appeared to make little difference in the results. In fact they concluded that the drug had no favorable effect on the severity of the symptoms, the period of incapacity or the incidence of complications. Moreover, in some instances, the reactions were serious enough to cause concern. They question the routine use of sulfanilamide in uncomplicated cases of tonsillitis and pharyngitis. They do, however, urge the use of the drug when complications occur, such as cervical adenitis, paranasal sinusitis, or otitis media.

At the Presbyterian Hospital our results have been checked in connection with otitis media. In a group of 100 children, half received sulfanilamide, half did not. In those receiving the drug, the duration of the discharge was on the average, 8 days. In those who did not receive the drug, the average duration was 12 days. Two per cent of the treated

cases had mastoidectomies, whereas 12 per cent of the untreated cases had mastoidectomies.

Of the various sequelae, I shall discuss laryngeal abscess, laryngotracheobronchitis, and peritonsillar abscess.

Laryngeal Abscess

A number of laryngeal abscesses are caused by the trauma of a swallowed foreign body. In such cases the train of events is easily followed. After the pain of the injury, there succeeds a period of more or less comfort. Then, as infection ensues, pain on swallowing develops, and perhaps some dyspnea. It is the characteristic of these traumatic abscesses, however, to be limited in their effect. Many of them are confined to the epiglottis. Examination with the mirror reveals a limited swelling which may already show a whitened area where the pus is pointing. Should threatening edema develop, the larynx should be exposed with a direct speculum, or a mirror and the edematous area scarified. As soon as an area of pointing presents itself, the abscess should be incised. As a rule healing is prompt.

The laryngeal abscess secondary to acute streptococcal pharyngitis or tonsillitis is much more stormy in its course. The infecting organism is as a rule an extremely virulent streptococcus. Pain in the throat is from the beginning severe, and difficulty in breathing may soon follow. Examination of such a larynx shows great swelling of the epiglottis and the aryepiglottic folds. At so early a stage no focus can be seen. It is customary to use for these cases, steam inhalations, sprays of cocaine and adrenalin and the like. These measures may at times suffice. The safest procedure however, is early and deep incisions made in the epiglottis and the folds. These incisions will relieve the edema. An abscess will probably form later and may discharge through these incisions or may need separate incisions. Occasionally the infection will penetrate to the perichondrium lining the inner surface of the thyroid cartilage. An abscess will then form in the pyriform fossa which must be drained by external incision in the neck. Such an abscess, undrained, may penetrate to the vascular sheath and invade the mediastinum.

The treatment, then, of acute laryngeal abscess is early scarification. A tracheotomy will thus be avoided. Later, drainage of localized pus must be effected by incision under direct exposure. If the pus reaches the pyriform fossa, an opening through a window in the thyroid cartilage

TABLE II

ANALYSIS OF FIVE CASES OF ABSCESS OF THE LARYNX

1. Sore throat for 24 hours; epiglottis swollen; ruptured on one side; opened the other.
2. Pain for 36 hours; swelling left side of larynx; ruptured.
3. Foreign body day before; larynx blocked; tracheotomy; discharged in 7 days.
4. Sixteen days old, ailing; abscess found at autopsy.
5. Pain in throat 2 weeks; admitted choking; tracheotomy; incision of laryngeal abscess; ligation of internal jugular vein; drainage of lung abscess; died.

and external incision low down in the neck may be required (Table II).

It will be seen that two of these cases came from infection and one from a foreign body. Only one of them had to be opened. Two ruptured spontaneously; one case of foreign body required a tracheotomy within 24 hours. In a paper published by Henry P. Schugt and myself,[11] five additional cases were reported. In addition I have seen three others. There have been two deaths among the thirteen patients, one due to mediastinitis, the other to lung abscess.

LARYNGOTRACHEOBRONCHITIS

In my experience this begins with terrifying suddenness. A child may complain of sore throat at noon and by evening be at the point of death from strangulation. Examination of the pharynx may show only a red throat. Examination of the larynx with the direct speculum shows the tissue fiery red, perhaps covered with white membrane. The cultures do not give uniform results; various forms of streptococci or pneumococci show. Two of the most severe cases I have seen showed the influenza bacillus in the throat culture and also in the blood stream. One of these patients recovered when given sulfanilamide.

My procedure is to do a tracheotomy if there is any difficulty in breathing. I have tried combating the dyspnea with steam and oxygen-helium in a tent. The latter beyond doubt relieves dyspnea for a time, but cannot maintain the improvement. My procedure is to pass a bronchoscope through the inflamed larynx, and perform a tracheotomy on that as a guide. Observation at that time shows the bronchial mucous membrane already inflamed, perhaps covered with membrane. The pa-

TABLE III

SUMMARY OF THE 18 CASES OF LARYNGOTRACHEOBRONCHITIS

Recovered	12	Deaths in tracheotomies	6
Died	6	Patients given sulfanilamide	12
Tracheotomies	10	Deaths in sulfanilamide group	3

tient is then kept in steam; sodium bicarbonate solution is instilled through the tracheotomy and perhaps bronchoscopy repeated many times for the removal of the membrane. The mortality of this disease has been 50 per cent. There was a remarkable increase in laryngotracheobronchitis in the years 1938 and 1939. George Brighton working with the patients at Babies Hospital, including also private cases, found the mortality among the tracheotomized cases to be 40 per cent. He makes the interesting suggestion that this may be a virus disease, not due to any bacterial organism, which would explain the cultures being so varied. He bases this idea on experimental work which has been done in connection with laryngotrachitis in chickens. This disease in these animals has proved to be due to filterable virus. The pathological changes found in the mucous membrane of the trachea are similar to those found in human beings who have died of this disease. Although it is not always safe to compare results in animals and human beings, the close resemblance of the two diseases is at least suggestive. Brighton's report is based on twenty-eight patients all of whom had tracheotomies. Many of these were private patients who perhaps received more intensive nursing care.

It will be seen from Table III that six out of ten of the patients who required tracheotomy died. Sulfanilamide appeared to make very little difference in these extremely ill children. One patient died 6½ hours after admission although he was given prontylin intravenously.

PERITONSILLAR ABSCESS

W. Krainz[12] explains the tendency to peritonsillar abscess in those subject to chronic tonsillitis in the following way. The crypts of the tonsils are always more or less occupied by a mass consisting of cell detritus, food, bacteria and the like. Owing to the action of the palatal muscles during swallowing, the crypts are for the most part kept clear

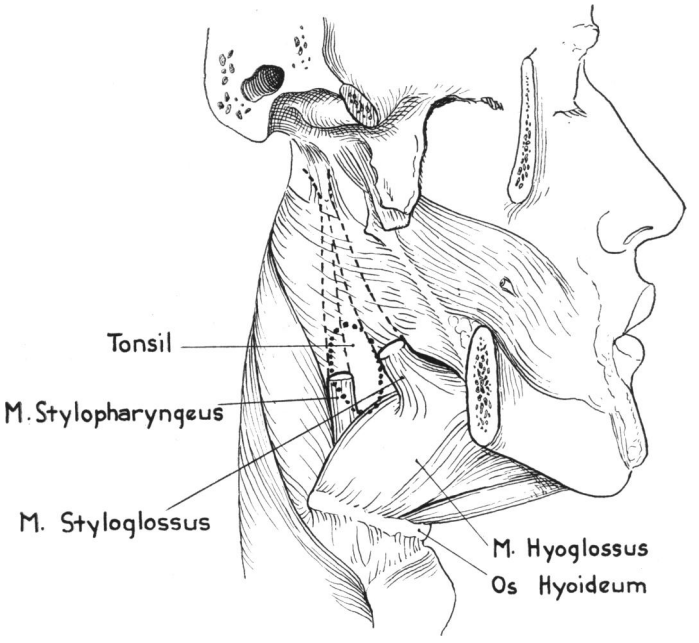

Fig. 1—The anatomy of the tonsillar region.

of these masses. When there have been many attacks of tonsillitis, however, there is a deposit of fibrous tissue in the tonsil which prevents the emptying of the crypts. Then the masses in the crypts become infected and abscesses are formed.

Such abscesses begin in the depth of a crypt. Swelling about the mouth of the crypt blocks off the drainage and the abscess ruptures outward into the space between the tonsil and the walls of its fossa formed by the pillars in front and behind and the superior constrictor of the pharynx to the outer side. As a rule the abscess develops high in this space and points forward between the anterior pillar and the tonsil at its upper pole where it can be opened after 5 or 6 days. The result then is immediate relief.

Sometimes the result is not so happy. The abscess may be low between the tonsil and the posterior pillar. Then it can be reached for incision only with great difficulty. The result may finally be spontaneous rupture without the intervention of the surgeon. Both of these results, though the patient has suffered much for a number of days, are considered satisfactory.

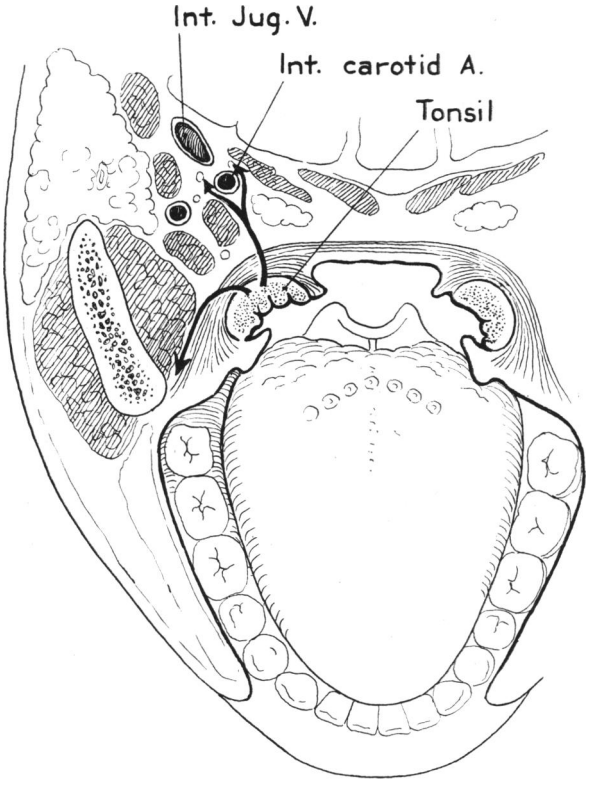

Fig. 2—The relation of the tonsil to the great vessels.

Things, however, may not turn out so well. The surgeon may make several incisions without finding the abscess. The tonsil may continue to protrude into the throat; pain and dysphagia may continue and a swelling appear outside in the neck. To explain this we must consider the anatomy of this region. It has been said that the tonsil lies on the superior constrictor of the pharynx. This muscle forms the inner wall of the pharyngomaxillary space, bounded on the outer side by the maxilla and internal pterygoid muscle, above by the base of the skull, behind by the muscle of the vertebral column. It is divided into an anterior and posterior compartment by the styloid process and its muscles. The anterior compartment contains the parotid gland and communicates below with the submaxillary space. The posterior compartment contains the great vessels of the neck in their sheath which runs into the mediastinum.

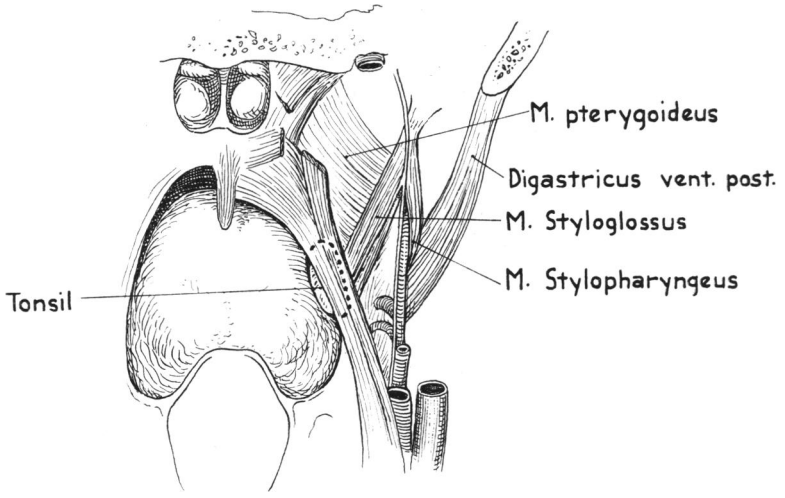

Fig. 3—The relation of the tonsil to pharyngeal muscles.

The peritonsillar abscess which does not respond to incision and drainage has broken through into the pharyngomaxillary space. This accident of course greatly increases the danger to the patient, the degree depending on where the rupture takes place. The pus may take one of four directions. If it ruptures high into the anterior compartment, it will lie between the internal pterygoid muscle and the pharynx. There will be no external swelling but considerable trismus. If the rupture occurs lower down, the pus will follow the styloglossus muscle to the floor of the mouth and form a submaxillary abscess. It will not pass down the neck. If the pus passes behind the styloid process it may reach the posterior triangle of the neck at the base of the skull. This very rarely happens. In one of the few cases reported there was severe hemorrhage because in the passage of the pus beneath the great vessels, the internal jugular vein was eroded.

Pus pointing into the posterior compartment is much more likely to break into the sheath of the great vessels and pass down the neck toward the mediastinum. Even though this does not occur, the mere contact of the pus with the vein may cause thrombosis of the internal jugular vein with consequent general sepsis. It should be recalled moreover, that the tonsil lies in a plexus of veins. Thrombosis of these small radicals may extend to the internal jugular.

Pus may reach the vascular sheath in still another way secondary

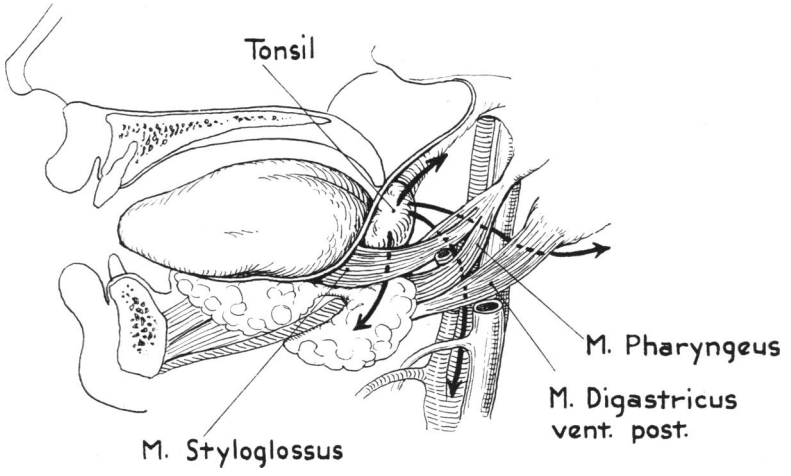

Fig. 4—Four possible paths along which peritonsillar abscess may travel when it has broken into the pharyngomaxillary space.

to tonsillar or peritonsillar abscess, namely, through the lymphatics. If the glands along the great vessels break down and suppurate, the pus will be in contact with the vein.

A number of so-called peritonsillar abscesses occur secondary to the extraction of teeth, and the formation of a submaxillary abscess. In these cases the pus has followed backward the route which leads from the pharyngomaxillary along the styloglossus muscle to the submaxillary space. These are not in reality peritonsillar abscesses. They are from the start deep abscesses of the neck.

Upon the entry of the pus into the neck, new symptoms are added to those of peritonsillar abscess. Severe trismus develops in connection with abscesses of the pharyngomaxillary space. The submaxillary abscesses develop characteristic local symptoms. The abscesses along the vascular sheath are liable to cause edema of the larynx and difficulty in breathing of such a degree that a tracheotomy may have to be considered. The chills and fever of septicemia will follow infection of the vein.

Treatment of Peritonsillar Abscess

In view of the dangerous complications which may arise in connection with peritonsillar abscess many have been discontent with the ordinary treatment, namely, hot irrigations till the pus points, then,

incision into the anterior pillar. The suggestions have been: (1) separation of the superior pole of the tonsil; (2) partial tonsillectomy, the superior pole of the tonsil being removed; (3) total tonsillectomy. These operations are done during the acute attack.

There appears to be little more to be said for separation of the superior pole of the tonsil than for simple incision or for separation of the anterior pillar from the tonsil with a tonsil hook, a procedure which has long been carried out at the Presbyterian Hospital. When this procedure is successful, it suffices but the pillar may adhere again and so block drainage and, moreover, low posterior abscesses are not reached.

Schroeder[13] reports on the treatment of peritonsillar abscess at the Sundby Hospital, Copenhagen; 92 patients were treated by the usual peritonsillar incision and made a satisfactory recovery. Fifty-six patients needed further operative treatment for the following reasons: In fifteen cases no pus appeared after repeated incisions and the temperature remained high; in thirteen cases the abscess was followed by nephritis; in eleven cases edema of the glottis occurred; in seventeen cases parapharyngeal abscess formed; in two cases there was thrombophlebitis of the internal jugular vein; in forty-three of these patients detachment of the upper pole was done, in five cases on both sides; in the remaining thirteen patients, total tonsillectomy was done. All of these patients recovered without further complications. The procedure was carried out under local anesthesia.

As early as 1911 (Winckler[14]), total tonsillectomy during the attack was suggested and carried out. Salingre[15] (Helsingfors) is one of those who advocates this procedure, especially in cases threatened with complications, or in cases in which the abscess is low down or far back. He uses local anesthesia, injected into the palatine foramen and into the lower pole of the tonsil. He employed this procedure in fifty-four cases; all were successful.

Other authors are even more enthusiastic than Salingre, unreservedly recommending tonsillectomy during the attack and even advocating the removal of the tonsil on the opposite side. Blashki[16] is one of these. He reports thirteen patients operated on under general anesthesia. One of these died from heart failure, the anesthetic risk being known beforehand. W. Klose[17] urges double tonsillectomy on these patients because of the frequency of concealed abscesses. In twenty-four of his patients an unsuspected abscess was found on the opposite side on the occasion

of abscess tonsillectomy. In eleven patients abscesses developed after repeated incisions had supposedly healed the peritonsillar abscesses. In eight patients entirely unsuspected abscesses were found on tonsillectomy. He maintains that many more concealed abscesses will be found if sought for.

One of the advantages especially emphasized by those who advocate tonsillectomy during the attack of peritonsillar abscess is that this procedure makes possible the drainage of pus which has already penetrated to the parapharyngeal space. The tonsil being removed, the fistula leading to the extrapharyngeal collection will be exposed. The enlargement of this fistula will promote drainage into the pharynx and thus external operation will be avoided.

To those who fear the spreading of the infection by tonsillectomy in the presence of an abscess, the article by Gangl-Battig[18] may be pointed out. This author has demonstrated that the height of the attack is the very time when the resistance of the patient is highest. Once a well demarcated abscess is formed, the greatest danger is over. Drainage then becomes the greatest necessity, and this is best accomplished by tonsillectomy. Surely no one hesitates to remove an appendix in the presence of pus. Why not, then, tonsillectomy?

It may be taken for granted, then, that a good case may be made out for tonsillectomy during the active stage of peritonsillar abscess, especially in cases threatened with complications. I am not quite prepared, however, to recommend the procedure unreservedly. Some bad results have been experienced, especially when the opposite sound tonsil has also been removed. At the Presbyterian Hospital only a meager number of cases can be reported on. These were all done under general anesthesia, only the diseased tonsil being removed. The results were most gratifying. All pain appeared to cease at once, and all patients were able to eat freely within 24 hours.

Little has been said as to the use of sulfanilamide in these cases. This is because our results have not yet been sufficiently numerous to make them of value. A number of cases have, to be sure, resolved without developing pus, but you will note on the table that this has also been brought about by hot irrigations. Reports in the literature on the use of sulfanilamide are as yet few. Hubert and Leroux[19] reported on twenty-two patients treated with this drug. Sixteen of these recovered without surgical intervention, and in six, surgical intervention was nec-

TABLE IV

FEATURES OF 320 CASES OF PERITONSILLAR ABSCESS

Previous attacks	49	Complications	57
Previous tonsillectomies	9	Hemorrhage	6
Tonsillectomies	40	Otitis media	15
Ruptured after irrigations	57	Cellulitis of neck	8
Incised	162	Acute cervical adenitis	6
Incised more than once	19	Arthritis	2
Arose from teeth	39	Rheumatism	4
Resolved on irrigation without pus	19	Erysipelas	5
Incised after prontylin	7	Abscess of pharynx	11
Resolved after prontylin	25		

essary. They conclude that if given early sulfanilamide may prevent suppuration, but that every formed abscess must be opened. Sonnenschein[20] made a report on two patients. In one of these, the abscess reruptured spontaneously; in the other, it resolved without suppuration. These reports are too few to justify any conclusions.

In the past 10 years we have had 320 cases of peritonsillar abscess which I show in tabulated form (Table IV).

REFERENCES

1. Ludwig, D. Ueber eine in neuerer Zeit wiederholt hier vorgekommene Form von Halsentzündung, *Med. Cor.-Bl. d. württemb. ärztl. Ver.*, 1836, *6*:21.
2. Price, J. W., Jr. Ludwig's angina; report of 5 cases, *Ann. Surg.*, 1908, *48*: 649; Discussion, 788.
3. Grodinsky, M. Ludwig's angina; anatomical and clinical study with review of literature, *Surgery*, 1939, *5*:678.
4. Barker, A. Two cases of angina Ludovici, *Lancet*, 1885, *2*:571.
5. Rehn, E. Die Behandlung der Ludwigschen Phlegmone durch Exstirpation der Glandula submaxillaris, *Klin. Wchnschr.*, 1922, *1*:2138.
6. Blassingame, C. W. Ludwig's angina and deep infections of the upper part of the neck, *Memphis M. J.*, 1938, *13*: 196.
7. Hendricks, W. C. Surgery or sulfanilamide in Ludwig's angina? *M. Rec.*, 1939, *150*:415.
8. Leonardo, R. A. Ludwig's angina; review of 21 cases, *J. Internat. Coll. Surgeons*, 1940, *3*:82.
9. Thomas, J. J. Ludwig's angina; an anatomical, clinical, and statistical study, *Univ. Penn. M. Bull.*, 1908, *21*:2.
10. Rhoads, P. S. and Afremow, M. L. Sulfanilamide in treatment of sore throat due to hemolytic streptococci, *J.A.M.A.*, 1940, *114*:942.
11. Kernan, J. D. and Schugt, H. P. Abscess of the larynx and its treatment, *Ann. Otol., Rhin. & Laryng.*, 1934, *43*: 1009.
12. Krainz, W. Chronische Tonsillitis und Peritonsillarabszess, *Wien. klin. Wchnschr.*, 1937, *50*:737.
13. Schroeder, R. Some remarks on the surgical treatment of peritonsillar inflammations, *J. Laryng. & Otol.*, 1936, *51*: 631.
14. Winckler, E. Ueber Therapie der phlegmomösen Entzündungen des Waldeyer-

schen Ringes, *Deutsche med. Wchnschr.*, 1911, *37*:2139.

15. Salingre, E. Erfahrungen über die Tonsillectomie bei Peritonsillarabscess und septischer Tonsillitis, *Acta oto-laryng.*, 1938, *26*:480.
16. Blashki, E. P. Tonsillectomy à chaud in quinsy; report of 12 cases, *M. J. Australia*, 1939, *2*:936.
17. Klose, W. Über die getarnten Paratonsillarabscesse, *Arch. f. Ohren-Nasen- u. Kehkopfh.*, 1938, *145*:298.
18. Gangl-Battig, O. Die Abscesstonsillektomie, *Zentralbl. f. Hals-Nasen- u. Ohrenheilk.*, 1938, *30*:1.
19. Hubert, C. and Leroux, M. Les composés di-azoïques dans le traitement des abcès péri-amygdaliens, *Oto-rhino-laryng. internat.*, 1937, *21*:137.
20. Sonnenschein, B. A resume of sulfanilamide treatment of peritonsillar abscess, *Illinois M. J.*, 1939, *75*:450.