such extensive destruction as took place in the present case has been reported.

The unique character of the present case is perhaps due to the fact that these patients usually die, and it is only by the rarest good fortune that this patient's recovery, owing to prompt medical attention and to her own remarkable vitality and resistance, has enabled us to witness and to treat the interesting condition which we are able to report in this paper.

"Lockjaw" Caused by Spasm of the Internal Pterygoid Muscle.*

By AD. B. BAER, B. L., B. S., M. D., D. D. S., Special Lecturer on the Medical and Surgical Diseases of the Mouth, Face and Jaws, University of California Dental Department.

About the middle of August, 1910, Mr. J. B., 22 years of age, was kicked on the right side of the face by a horse. Associated with extreme pain, there resulted a gradual difficulty in swallowing and progressively increasing difficulty in the movements of the lower jaw until complete locking occurred at the end of about a week. Two X-ray pictures were taken at the time and were interpreted as showing a fracture about the middle of the ramus of the maxilla on the right side. There was a complete over-bite of the upper front teeth, the lower front teeth being completely hidden behind the uppers. The bicuspids and molars were in apparent correct occlusion. It was this condition of the front teeth which first drew attention to the fact of a possible fracture, the patient claiming that previous to his injury the front teeth had been in edge to edge occlusion.

A plaster cast was applied and kept in position for six weeks. During its application patient complained of constant pain, difficulty in swallowing and intermittent desire to hawk and spit. Cast was removed at the end of six weeks, with no apparent change in patient's condition. Jaws were still locked, but there were intervals when he was able to open his mouth about one-half inch.

Another X-ray picture was taken at this time with same diagnosis, same treatment and the same result. Patient consulted several different surgeons and specialists in an effort to get relief, and after a lapse of nine months he was practically in the same condition as when he started. At the end of nine months he was given his choice of going through the rest of his life with his jaws almost locked, or of submitting to an open operation, which would necessitate the cutting of his right facial nerve with a resulting paralysis of the right side of the face, gradual loss of muscular tone and atrophy, dribbling of the saliva from the right corner of the mouth and pulling of the face over to the left side. He chose the first of the two alternatives until his nagging pain again caused him to seek relief and he was sent to me May 28th of this year.

Preliminary examination disclosed this very important fact: That his teeth were in perfect occlusion, the apparent over-bite of the upper front teeth being a perfectly normal condition. (Normal occlusion of the teeth may always be accurately determined as follows: the upper first bicuspid tooth should come down between and articulate with the two lower bicuspids; and the anterior buccal cusp of the first upper molar tooth should fall into the groove or sulcus which lies between the two buccal cusps of the first lower molar tooth.) Given this normal articulation of the teeth, we can practically always eliminate the possibility of displacement due to fracture in the anterior or posterior parts of the body of the maxilla. And a most painstaking and forcible digital examination failed to show any apparent fracture of the maxilla in this case. We were able to verify this conclusion by means of an X-ray picture taken by Dr. Painter. We were perfectly sure of our X-ray reading, but to make assurance doubly sure, inasmuch as practically every man who had seen the patient had made a diagnosis of fracture high up on the ramus, a second picture was taken, with a film placed inside the mouth and held against the internal surface of the ramus, for there is necessarily considerable overshadowing of the ramus of the jaw by the other bones of the head and especially by the first and second cervical vertebra. But by means of this film picture we were able to get the anterior half of the ramus clear to the coronoid process and were able to absolutely eliminate all possibility of a fracture. And there not only was no fracture, but there was no other pathological condition of the maxilla to account for patient's symptoms.

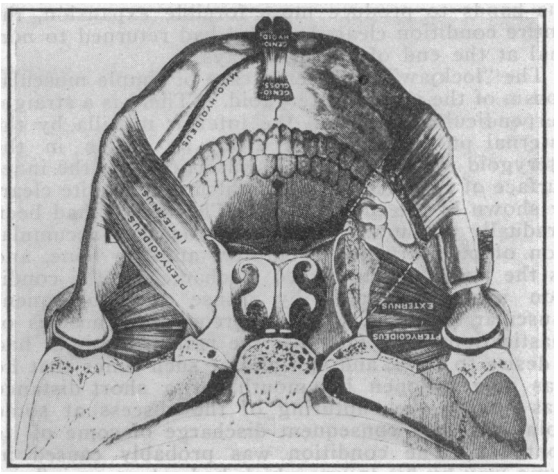

Plate showing internal pterygoid muscle, seen from behind. (After Testut.)

Having determined what was not the cause of patient's condition, we set about to determine what was the cause, if possible. We had four signs or symptoms to go by. 1st, the jaws were locked. 2nd, there was a dull, steady pain in the glenoid cavity at the point of articulation. 3rd, there were intervals when it was possible for patient to open his mouth from ½ to ¾ of an inch, and 4th, there was an intermittent desire to hawk and gag and spit. The diagnosis was finally made in the following way: By a careful digital examination, the most painful point was found to be up under the angle of the maxilla on the internal surface and not at the articulation as the patient supposed. From the angle of the jaw the pain decreased on pressure as we ascended toward the condyle. We then cocanized the throat and getting the base of the tongue well down and out of the way, an intensely red, inflamed area showed on the right side over the area of insertion of the internal pterygoid muscle, and there was a very definite inward bulging of the muscle at this point. This inward bulging was made perfectly evident by comparing the two sides. Pressure upon this area by means of a long applicator caused the patient to shriek with pain which was so intense that he lost complete control of himself. At the end of a few minutes he quieted down, and the intense pain was followed by an almost complete absence of pain. He was now able to open his mouth about ¾ of an inch and on further examination a thin stream of thick whitish gray pus was seen trickling down into the throat from the posterior inferior margin of the ramus of the jaw. Diagnosis of a slow chronic abscess in the sheath of the internal pterygoid muscle at its point of intersection into the lower end of the ramus of the maxilla, was made. The X-ray picture completely eliminated the possibility of there being any associated bone involvement and we were able to give patient and his friends a positive opinion on the question of prognosis.

Patient was sent to hospital and even under ether

* Read before the Eye, Ear, Nose and Throat Section of the San Francisco County Medical Society, Sept. 26, 1911.

it took some time to force the jaws apart owing to the long tonic contraction of the masseter, temporal and pterygoid muscles, which had resulted from their long disuse. With the mouth wide open a very definite fluctuating mass could be felt beneath the inflamed, bulging area. An incision about one inch in length was made along the anterior margin of the internal pterygoid muscle and about a dram of a thick, creamy pus was evacuated. The abscess sac was curetted and swabbed with Churchill tincture of iodin. The upper half of the insertion of the muscle was cut away from its attachment to the bone in order to weaken the contractile power of the muscle itself. Patient's pain gradually disappeared, and by constantly forcing the jaws apart by normal muscular action, assisted at times by having patient use his hands to produce more forcible expansion, the entire condition cleared up and had returned to normal at the end of about 12 days.

The "lockjaw" had been a case of simple muscular spasm of the internal pterygoid. (There is a straight perpendicular pull from the inferior maxilla by the internal pterygoid muscle, from its origin in the pterygoid fossa above, to its insertion into the inner surface of the ramus below, which is not quite clearly shown in the illustration.) The muscle had been gradually put upon a stretch by the slow accumulation of pus between the muscle and the bone, and as the jaws became locked mechanically, the condition was accentuated by disuse and consequent muscular spasm of the three remaining muscles of mastication. The fact that the patient at times had a desire to hawk and spit and at such times that he was able to open his mouth for a short distance was due to the rupturing of the abscess at some point and to a consequent discharge of some of its contents. The condition was probably caused in some way by his injury which had set up an inflammatory condition in the sheath of the muscle and which in the course of time became purulent.

Patient was seen again on July 5th and September 8th. There was no recurrence, the entire mouth condition being normal.

SOCIETY REPORTS

COOPER COLLEGE SCIENCE CLUB.

A regular meeting of the Cooper College Science Club was held on Monday evening, Oct. 2, 1911. when the following program was given:

1. Presentation of Surgical Cases. Dr. A. L. Fisher. Discussed by Drs. Winterberg and Fisher.
2. Presentation of Cases. Dr. H. H. Yerington. Discussed by Drs. Wilbur, Winterberg, Alvarez, Clark, Eloesser and Oliver.
3. Presentation of a Case of Rheumatoid Arthritis, with demonstration of X-ray Plates. Dr. H. R. Oliver. Discussed by Drs. McClenehan, Luttrell and Oliver.

At the close of the program refreshments were served.

CALIFORNIA ACADEMY OF MEDICINE.

The regular monthly meeting of the California Academy of Medicine was held in the library of the San Francisco County Medical Society on Monday evening, September 25, 1911, President Ebright in the chair. The scientific program was as follows:

1—Demonstration of Myopathies of Diverse Types. Langley Porter. Discussed by Drs. Watkins and Porter.

2—Is the Representation of Motor Function in the Cerebral Cortex Limited Topographically? An Experimental Inquiry. Sol Hyman. Discussed by Drs. Eloesser and Hyman.

3—Experimental Glandular Atrophy. Dudley Tait. Discussed by Drs. Ophuls, Eloesser and Tait.

Dr. Wilbur A. Sawyer was unanimously elected to membership.

At the close of the program refreshments were served.

PURE FOOD ORDINANCE IN SAN DIEGO.

Through the efforts of the San Diego Board of Health, a Meat and Dairy Inspection ordinance has been passed by the City Council, requiring inspection of all slaughter houses and dairies in or near San Diego furnishing their products to this city, and prescribing arrangement of their plants. Ion W. Parks, M. D. V., has been appointed Chief Inspector; appointment of assistant inspectors is pending. Appointments are made by the Board of Health.

A certified dairy has been opened in Mission Valley and the city now has the purest of milk from this source.

B. J. O'NEILL, M. D., Secretary.

CLINICAL CONGRESS OF SURGEONS OF NORTH AMERICA, SECOND ANNUAL MEETING, PHILADELPHIA, NOVEMBER 7 TO 16, 1911.

The program of the Congress includes clinics by the leading surgeons of Philadelphia in all the principal hospitals each day of the session from 8 a. m. to 5 p. m., and seven evening literary meetings at which eminent surgeons from other cities will read papers and take part in the discussions.

These programs, with detailed information as regards registration, appear in full in the October number of Surgery, Gynecology and Obstetrics, the official journal of the Congress, which can be obtained free by addressing Franklin H. Martin, M. D., General Secretary, whose address is given below.

Visiting surgeons will register at headquarters at The Bellevue-Stratford, where cards of admission to the clinics will be issued and a bulletin of the clinical features and literary sessions published daily.

Invitations will be issued to physicians who desire to attend the Philadelphia meeting and become members of the Clinical Congress if their names and addresses are sent to the General Secretary, Dr. Frank H. Martin, 1210 Columbus Memorial Building, Chicago, Illinois.

BOOK REVIEWS

The Practical Medical Series: Nervous and Mental Diseases. Patrick Bassoe, 1910. Published by Year Book Pub. Company, Chicago, 1910.

No man has a right to be ignorant of the year's neurological literature when he can acquire for the merest stipend the amount of information which the book under review presents; nor can he make the plea that the volume of the literature is so vast, that time fails him to attack it, for here it is given in the most succinct form.

While essentially a compilation this volume of the Practical Medical Series is not the work of mere compilers. We commend it most heartily. L.

A Working Manual of High Frequency Currents. By Noble M. Eberhart, A. M., M. S., M. D., Professor and head of the Department of Electrotheraphy, Chicago College of Medicine and Surgery, etc. Chicago: New Medicine Publishing Co.; cloth; $2.00.

This little volume treats the subject in a thorough manner, especially from a practical point of view.

For the busy physician who wishes to use High Frequency this book will prove useful, for it is not too extensive nor too technical.

A chapter is devoted to diseases, alphabetically arranged, telling the correct technique to be employed in each case. The author does not confine himself to High Frequency in treating certain diseases, but often suggests some other form of electrotherapy as being better suited for the amelioration of the trouble. His practical experience of ten years of daily use of these currents has enabled him to place before the profession an individual opinion. The book is written in good style and is well illustrated.

N. SELLING.