Paralytic shellfish poisoning

JOHN ACRES,* MD; JEAN GRAY, B SC, MD, FRCP[C]

Two cases of paralytic shellfish poisoning after ingestion of mussels occurred in October 1977 in Nova Scotia. The incidence of this type of poisoning is relatively high among persons living on the coast of the Bay of Fundy and the estuary of the St. Lawrence River. The causative organism, *Gonyaulax tamarensis*, elaborates an endotoxin, saxitoxin, that blocks neuromuscular transmission in the motor axon and muscle membrane while leaving the end-plate unaffected; it also suppresses conduction in the atrioventricular node and inhibits the respiratory centre. The clinical manifestations are unique and include numbness of the lips, tongue and fingertips within minutes of ingestion of the poisoned shellfish, then numbness of the legs, arms and neck, with general muscular incoordination, and finally respiratory distress and muscular paralysis. Treatment is symptomatic and prevention can only occur by public education.

Deux cas d'intoxication paralytique par absorption de coquillages se sont produits en Nouvelle-Écosse en octobre 1977 suivant l'ingestion de moules. L'incidence des intoxications de ce genre est relativement élevée parmi les habitants de la côte de la baie de Fundy et de l'estuaire du Saint-Laurent. L'organisme causal, *Gonyaulax tamarensis*, élabore une endotoxine, la saxitoxine, qui bloque la transmission neuromusculaire au niveau de l'axone moteur et de la membrane musculaire mais épargne la plaque motrice; aussi elle supprime la conduction au niveau du noeud atrioventriculaire et inhibe le centre respiratoire. Les manifestations cliniques sont tout à fait particulières et comprennent un engourdissement des lèvres, de la langue et des extrémités digitales dans les minutes qui suivent l'ingestion des coquillages toxiques, puis un engourdissement des jambes, des bras et du cou, avec une incoordination musculaire générale, et finalement une gêne respiratoire et une paralysie musculaire. Le traitement est symptomatique et la prophylaxie dépend uniquement de l'éducation du public.

From the departments of medicine and pharmacology, Dalhousie University, Halifax

*Resident in internal medicine

Reprint requests to: Dr. Jean Gray, Department of pharmacology, Sir Charles Tupper Medical Building, Dalhousie University, Halifax, NS B3H 4H7

Illness resulting from the eating of shellfish may be one of three types: an acute allergic reaction, a fulminant infection acquired from shellfish contaminated with bacteria or viruses, or sensory and motor paralysis known as paralytic shellfish poisoning. Two cases of paralytic shellfish poisoning are presented here, and the historical and medical aspects of this fascinating disease are discussed.

Case reports

Two brothers, aged 50 and 54 years, were vacationing at a cottage on the Nova Scotia coast of the Bay of Fundy in October 1977. A fierce storm drove a navigational buoy onto the beach, and the next day the two men harvested a large number of mussels from the buoy and steamed them. Within 20 minutes of eating the mussels the older brother complained of circumoral paresthesia. A family member immediately transported both men to a local hospital. In the older brother paresthesia rapidly developed in both legs, to be followed by generalized muscle weakness and vomiting. He was aware of being unable to breathe, but still had sufficient motor power in his legs to signal the medical staff of his difficulties. The younger brother's illness followed a similar but more protracted course. Both men required entubation and mechanical respiratory support. About 2.0 mg of atropine and 2.0 mg of physostigmine salicylate was administered to each man as an antidote to the poison. Transfer to the Victoria General Hospital in Halifax was then arranged.

Both men were admitted to the medical intensive care unit, where examination revealed no muscular activity whatever. All reflexes were absent, including the pupillary and corneal reflexes.

Respiratory support was maintained and intravenous therapy with 0.9% sodium chloride was begun. Urinary tract catheters were inserted, and hemodialysis was begun immediately. Within about 3 hours the older brother began blinking and moving his limbs. He was weak but mobile within 24 hours and no longer required respiratory assistance. The younger brother showed no signs of recovery after the first period of hemodialysis. Profuse bleeding from the upper gastrointestinal tract in this brother was controlled by administration of antacid and cimetidine through a nasogastric tube. Dialysis was repeated the following day, and during this procedure the patient began to blink his eyelids. For both men full recovery took several more days and was complicated by urinary tract infection and, in the case of the younger brother, severe back pain accompanied by absence of a knee jerk on the right side; myelography did not demonstrate an abnormality.

During the recovery period electromyography revealed slight but definite diffuse dysfunction of motor and sensory peripheral nerves but no evidence of defective neuromuscular transmission in the older brother. The younger brother was able to describe vividly the entire course of events, including conversations that took place in the ambulance and in the intensive care unit when he was completely paralyzed.

Subsequent analysis of the ingested mussels showed a toxin concentration of 43 mg per 100 g of the sample; a lethal dose is considered to be 0.5 mg (Fisheries Research Laboratory, Halifax: personal communication, 1978).

Discussion

Poisoning by shellfish is not uncommon, but most cases are either of the gastrointestinal type, due to bacterial or viral contamination, or of the hypersensitivity type.[1,2] The two men we have described, however, had the form of shellfish-associated illness in which neurologic symptoms predominated. This condition, known as paralytic shellfish poisoning, results from ingestion of saxitoxin, a very potent endotoxin.

Reports of paralytic shellfish poisoning have been worldwide. Among

persons living on the coast of the Bay of Fundy and the estuary of the St. Lawrence River the incidence of this type of poisoning is relatively high (Fig. 1):[3] there have been 117 documented cases in the Bay of Fundy area, 3 of which were fatal; most occurred during two incidents — one in Digby County in 1946 and one at Point Lepreau, NB in 1957.[4]

The disease is not a recent one. The French settlers at Annapolis Royal were cautioned by the Indians not to eat shellfish during the summer, and on the West Coast Capt. George Vancouver included in his diary of June 15, 1793 a classic description of a fatal case of paralytic shellfish poisoning among his crew. Vancouver subsequently named the spot where the mussels were harvested Poison Cove, and the branch leading to it Mussel Channel.[1]

The mussel is not the only shellfish capable of inducing paralytic poisoning. In the Bay of Fundy clams, scallops and other filter-feeding bivalve molluscs can also concentrate the dinoflagellate *Gonyaulax tamarensis* from the surrounding water. Saxitoxin elaborated from the organism does not affect any of these shellfish. Man eats only the adductor muscle of the scallop, which is not toxic, but birds and other animals are occasionally poisoned by eating the scallop shuckings. The dinoflagellate is rather fastidious, preferring warm water of relatively low salinity as well as abundant sunlight. Occasionally it grows to bloom proportions (Fig. 2) and imparts a characteristic redness to the sea water — a phenomenon commonly referred to as "red tide". Little is known about this phenomenon, and it does not necessarily precede an episode of shellfish poisoning. In the winter the organism is thought to become encysted and fall to the bottom of the bay.

Saxitoxin has a molecular weight of 372 daltons and the chemical composition $C_{10}H_{17}N_7O_4$.[5,6] The molecule is water soluble and heat stable. It is absorbed through the mucosa of the mouth and small intestine and is distributed throughout the body water. There is little information about its excretion in humans, but dogs excrete it in the urine.[7]

The toxin blocks neuromuscular transmission in the motor axon and muscle membrane while leaving the end-plate unaffected, as was confirmed by electromyography in one of our patients. In the heart saxitoxin suppresses conduction in the atrioventricular node, whereas its effects on respiration appear to be mediated in the respiratory centre. One of our patients was unable to breathe even though he had sufficient motor strength to signal medical staff with his legs. At a molecular level, saxitoxin (like tetrodotoxin, another marine poison) blocks sodium channels in excitable membranes, preventing the propagation of impulses.[1]

The clinical manifestations of paralytic shellfish poisoning are unique and begin with numbness of the lips, tongue and fingertips within minutes of ingestion of the poisoned shellfish, followed by numbness of the legs, arms and neck, with general muscular incoordination. Other symptoms often reported include a feeling of lightness (as though floating on air), dizziness, weakness, drowsiness, incoherence and headache. Most patients remain calm and conscious throughout the illness. Respiratory distress and muscular paralysis are the final stages of the disorder and

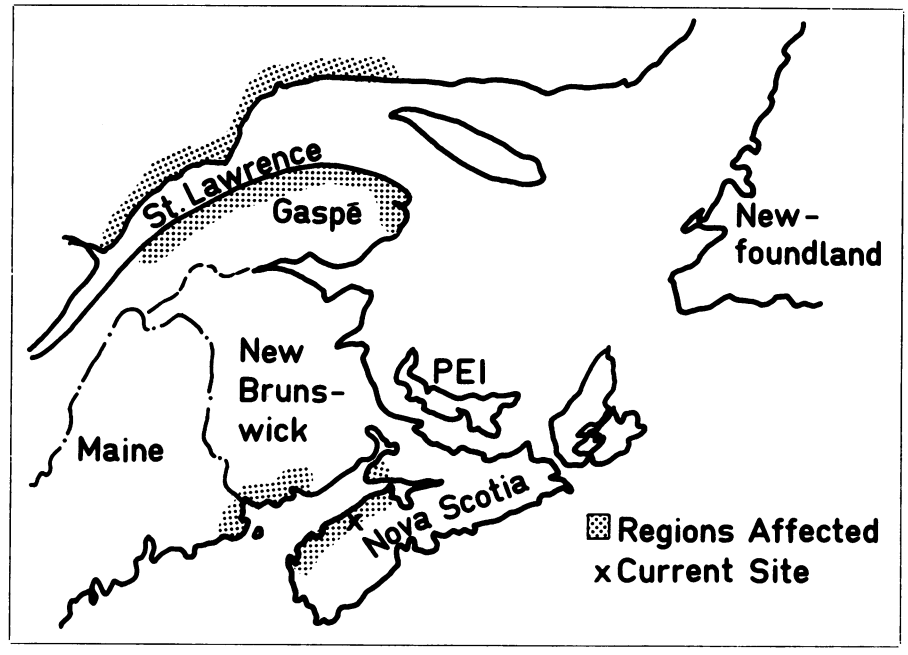

FIG. 1—Areas of confirmed cases of paralytic shellfish poisoning in Atlantic Canada.

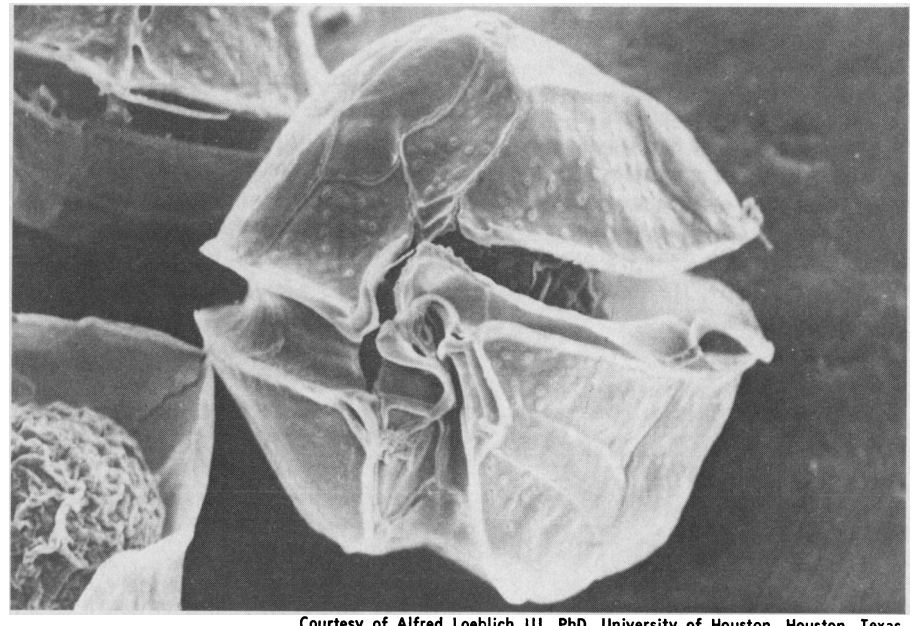

Courtesy of Alfred Loeblich III, PhD, University of Houston, Houston, Texas, and A. Prakash, PhD, Fisheries and Environment Canada

FIG. 2—Scanning electron micrograph of *Gonyaulax tamarensis* bloom (×2820).

can occur anywhere from 2 to 12 hours after ingestion.[7] Our two patients experienced most of these symptoms, including awareness of their surroundings during paralysis.

Treatment is symptomatic. If the patient is seen immediately after eating the poisoned shellfish the material should be removed from the gastrointestinal tract by emesis or lavage, then activated charcoal should be used liberally to block further absorption of the poison. Alkaline and sodium-containing fluids are thought to block the effect of saxitoxin on nerve conduction. Of greatest importance, however, to a successful outcome is prompt assistance with ventilation. Without the rapid action of the local attending physician both our patients would have died.

The poison is probably removed by the kidneys. Although both our patients received hemodialysis and one appeared to recover during dialysis, there is little information in the literature on the efficacy of removal of saxitoxin by this procedure.[8] Further study of this aspect of treatment is required.

An additional factor that might have aggravated the poisoning in these men was their consumption of alcohol prior to the meal. Alcohol consumption seems to increase the severity of symptoms produced by the toxin.[6]

Prevention of this type of poisoning remains a problem partly because of the inaccurate folklore associated with shellfish poisoning;[3] for example:

- Shellfish are safe if eaten during months whose names contain the letter "r". *False.* Our cases occurred in October, and earlier cases have occurred from May through November.
- Mussels are the only potentially poisonous shellfish. *False.* Mussels, clams, whelks and scallops may all be poisonous.
- All poisonous shellfish live high on the beach, where they become "sunstruck" in the summer. *False.* The likelihood of *G. tamarensis* accumulation is increased as contact with the water increases.
- Mussels growing on sand and mud are poisonous; those on rocks are wholesome. *False.*
- Paralytic shellfish poisoning is caused by only one or two toxic shellfish in any collection. This *may be true,* but there are no means of distinguishing the poisonous shellfish from the nonpoisonous.
- Only large, old clams are poisonous. *False.*
- The beard of mussels contains all the poison. *False.* This is the only part of the mussel free of poison.
- All of the shellfish is edible. *False.*
- You can tell when shellfish are poisonous by opening them. *False.* Even world experts cannot do this.
- A silver spoon in the cooking pot tarnishes if the clams are toxic and stays bright if they are nontoxic. *False.* This has been scientifically tested and proven incorrect.

Although Fisheries and Environment Canada posts warnings on potentially affected beaches each year (Fig. 3),[3] these warnings are frequently ignored, as in the incident we have described. Only by making the public aware of the hazard of paralytic shellfish poisoning can further cases be prevented.

We thank Drs. J. Weir, E. Mann, A. Cohen and L. Heffernan, who assisted in the care of the two patients, and Dr. P. Maclean, whose quick thinking enabled them to survive.

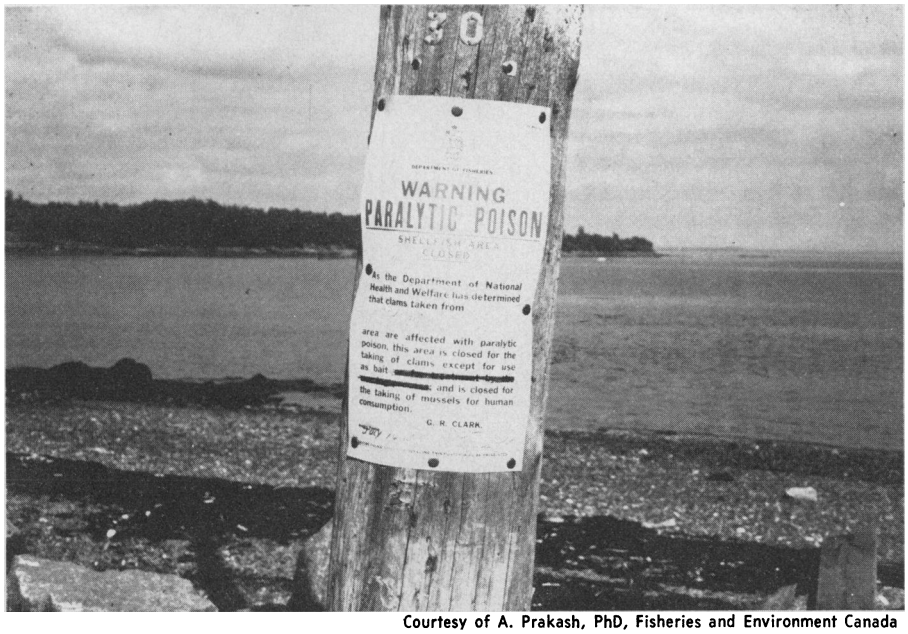

Courtesy of A. Prakash, PhD, Fisheries and Environment Canada

FIG. 3—Warning of paralytic shellfish poisoning on beach in Eastern Canada.

References

1. Kao CY: Tetrodotoxin, saxitoxin and significance in the study of excitation phenomena. *Pharm Rev* 18: 997, 1966
2. Earampamoorthy S, Koff RS: Health hazards of bivalve-mollusk ingestion. *Ann Intern Med* 83: 107, 1975
3. Prakash A, Medcof JC, Tennant AD: Paralytic shellfish poisoning in eastern Canada. *Fisheries Research Board of Canada Bull* 177: 1971
4. Bond RM, Medcof JC: Epidemic shellfish poisoning in New Brunswick, 1957. *Can Med Assoc J* 79: 19, 1958
5. Schantz EJ, Ghazarossian VE, Schnoes HI, et al: The structure of saxitoxin. *J Am Chem Soc* 97: 1238, 1975
6. Bordner J, Thiessen WE, Bates HA, et al: The structure of a crystalline derivative of saxitoxin. The structure of saxitoxin. Ibid, p 6008
7. Schantz EJ: The dinoflagellate poisons, in *Microbial Toxins,* vol 7: *Algal and Protein Toxins,* Kadis S, Ceigler A, Ajl SJ (eds), Acad Pr, New York, 1971, pp 3-26
8. Rand PW, Lawrence FH, Pirone LA jr, et al: The application of charcoal hemoperfusion to paralytic shellfish poisoning. *J Maine Med Assoc* 68: 147, 1977

BOOKS

continued from page 1193

THERAPEUTIC EXERCISE. 3rd ed. Edited by John V. Basmajian. 600 pp. Illust. The Williams & Wilkins Company, Baltimore; Burns & MacEachern Limited, Don Mills, Ont., 1978. $41.40. ISBN 0-683-00433-6

THIRD DECENNIAL REVIEW CONFERENCE: CELL, TISSUE AND ORGAN CULTURE. Gene Expression and Regulation in Cultured Cells. A Conference held in Lake Placid, New York, September 13-17, 1976. Edited by Katherine K. Sanford. National Cancer Institute Monograph 48. 401 pp. Illust. U.S. Department of Health, Education, and Welfare, Public Health Service, National Institutes of Health, National Cancer Institute, Bethesda, Maryland, 1978. Price not stated. DHEW publ. no. (NIH) 77-1441