CASE REPORT

Copper Deficiency in Calves in Northcentral Manitoba

M. E. SMART, J. GUDMUNDSON, R. P. BROCKMAN, N. CYMBALUK AND C. DOIGE*

Summary

Four seven month old Simmental calves were examined because of unthriftiness, a persistent cough, stiffness and lameness. The calves had gastrointestinal and pulmonary parasitism. Analysis of the blood copper levels of these calves and of cows and calves on the farm indicated a generalized deficiency. Only the calves affected with parasitism showed signs of clinical copper deficiency.

Résumé

Déficience en cuivre chez des veaux du centre nord du Manitoba

Quatre veaux Simmental, âgés de sept mois, subirent un examen médical parce qu'ils manifestaient une mauvaise condition, une toux persistante, de la raideur des membres et de la boiterie. Ces veaux souffraient de parasitisme gastro-intestinal et pulmonaire. La recherche de la teneur en cuivre du plasma de ces veaux et des vaches du troupeau en révéla une déficience généralisée. Seuls les veaux atteints de parasitisme manifestèrent les signes d'une déficience en cuivre.

Introduction

Primary copper deficiency occurs when dietary intake of this essential trace mineral is inadequate. Secondary deficiencies happen when intake is adequate but utilization is impaired by elevated dietary levels of molybdenum and/or sulphates (15). Although the N.R.C. Nutrient Requirements of Beef Cattle (9) states the copper requirement of beef cattle to be 4 mg/kg dry matter feed, these values are being reassessed to compensate for molybdenum and sulfate concentration of feed (5,15).

The clinical manifestations of copper deficiency in cattle vary with age. In adults, there can be a subtle loss in production with or without diarrhea or achromotrichia. In the growing animal, signs are impaired growth, lameness, stiffness, diarrhea, achromotrichia and mild anemia (4,13,15).

This report documents the clinical and pathological findings of copper deficient calves from a herd in northcentral Manitoba.

History

A purebred and commercial Simmental herd of cattle in northcentral Manitoba had a 20-30% decrease in the weaning weight of calves from a group of 200 cows. The calves were born on pasture in April and May and did well for the first month. In June seven calves died from bronchopneumonia. Although there were no further losses from pneumonia, the calves continued to do poorly. The affected calves were also stiff and had enlarged fetlock joints. Cows and calves were rotationally grazed on 400 acres of pasture. The pasture was fertilized annually with nitrogen and weeds controlled with a herbicide spray. The water supplies were a dugout and runoff. In the previous year, there had been scours and pneumonia in the calves but this was the first year that stiffness of gait was noticed.

Clinical Findings

Four seven month old, 3/4 Simmental calves, typical of the affected calves on the ranch, when admitted to the Large Animal Clinic at the Western College of Veterinary Medicine (W.C.V.M.) were unthrifty and had a dull, dry hair coat (Figure 1). The calves were reluctant to move; when prodded to walk they were stiff and walked on their toes. The legs were straight, with enlargement of the distal metacarpal and metatarsal physis (Figure 1). On auscultation of the lungs there were diffuse bronchial tones and dry râles. A moist cough could be elicited by palpation of the trachea. The mucous membranes were pale.

FIGURE 1. A seven month old Simmental calf with copper deficiency. Note the dull, dry hair coat. A - enlarged distal metacarpal physis.

On roentgenological examination, there were varying degrees of flaring at the metacarpal and metatarsal metaphyses. The physes were slightly irregular and widened (Figure 2).

Laboratory Findings

All calves had a mild microcytic

*Department of Veterinary Clinical Studies (Smart, Gudmundson, Cymbaluk), Department of Veterinary Physiological Sciences (Brockman) and Department of Veterinary Pathology (Doige), Western College of Veterinary Medicine, University of Saskatchewan, Saskatoon, Saskatchewan S7N 0W0. Present address of Dr. Smart: Department of Animal and Poultry Science, University of Saskatchewan, Saskatoon, Saskatchewan and present address of Dr. Cymbaluk: Equine Research Program, Cornell University, Ithaca, New York.

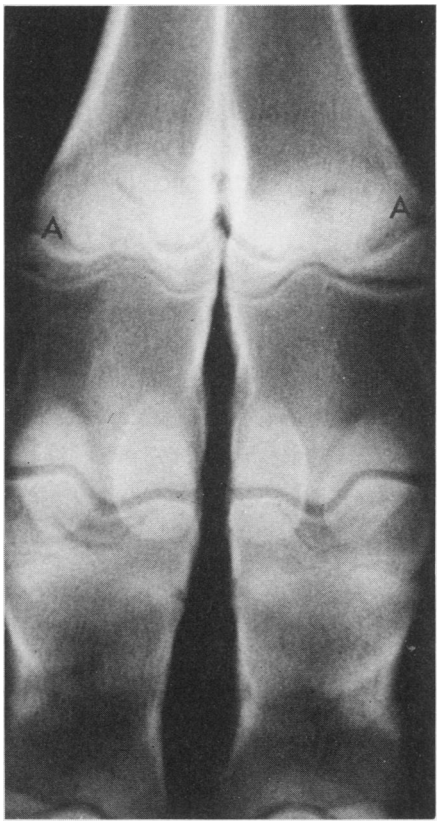

FIGURE 2. Anteroposterior view of distal metacarpus of a Simmental calf with copper deficiency. A - note flaring and mottling of the physis, especially in the lateral aspect.

TABLE I
CLINICAL PATHOLOGY RESULTS FROM SIMMENTAL CALVES WITH COPPER DEFICIENCY

	Day 1				Day 30 (After Treatment)			Normal
Calf Number	157	196	294	415	157	196	294	
Hemoglobin (g/dL)	10.4	10.2	11.6	-	9.3	9.3	11.1	11.4 ± 1.7 (12)
Packed cell volume (%)	29.2	25.8	32.0		24.6	23.6	31.1	35.9 ± 4.3 (12)
Mean corpuscular volume (fL)	27.0	27.0	31.0		28.0	30.0	33.0	43.2 ± 7.1 (12)
Mean corpuscular hemoglobin (pg)	9.8	10.7	11.2		10.7	11.2	11.7	13.6 ± 1.7 (12)
Mean corpuscular hemoglobin concentration (g/dL)	34.9	38.7	35.9		37.4	39.2	35.6	32.3 ± 1.7 (12)
Plasma copper (μg/mL)	0.50	0.44	0.56	0.49	0.67	0.76	0.47	0.7 - 1.2 (15)
Liver copper (μg/g) wet weight)	2.14	1.85	2.19	2.31	8.94	6.75	9.46	10-30 (15)
Liver molybdenum (μg/g wet weight)	.107	1.62	.97	1.50	2.03	1.39	1.16	<5 (15)

TABLE II
PLASMA COPPER CONCENTRATIONS (μg/mL), MEAN AND STANDARD DEVIATION FROM RANDOMLY SELECTED COWS AND CALVES AT PASTURE IN THE SAME HERD WITH COPPER DEFICIENCY

	Prior to Supplementation	After 4 Months Supplementation
Cows of Calves		
With clinical signs	0.28 ± 0.18 (N = 5)	1.07 ± 0.21 (N = 3)
Without clinical signs	0.37 ± 0.25 (N = 4)	
Calves		
With clinical signs	0.72 ± 0.29 (N = 6)	1.05 ± 0.30 (N = 4)
Without clinical signs	0.63 ± 0.43 (N = 5)	

normochromic anemia. The plasma copper concentrations were low. Liver biopsy samples obtained by laparotomy contained an average of 2.12 μg copper/g wet mass of tissue (15).

Mycoplasma species were isolated from the transtracheal aspirates of all calves. *Dictyocaulus viviparus* larvae, *Trichostrongylus* sp. and *Nematodirus* sp. were identified on fecal parasitological examination.

Treatment

Three calves (Nos. 157, 194, 196) were treated orally with gelatin capsules containing 5 g copper sulfate pentahydrate per day for one week, then necropsied on day 30.

The herd was provided with a loose salt mix containing 2.5% copper sulfate, *ad libitum*. Plasma copper concentrations of affected and unaffected calves and cows were analyzed prior to and four months after copper sulfate supplementation (Table II). Increased copper concentrations in the plasma were observed in all animals. Copper supplementation was continued throughout the year. The following spring, 200 mg copper glycinate[1] was injected subcutaneously into all newborn calves.

Additional therapy included treatment of internal parasites with levamisole hydrochloride[2]. The fecal parasite load was monitored in the spring and fall. There was 25 kg improvement in the weaning weights the next fall with no signs of copper deficiency, pneumonia or parasites in the calves.

Necropsy

The most severely affected calf (No. 417) was euthanized and necropsied on day four.

Calf (No. 417) had parasitic pneumonia *(Dictyocaulus viviparus)* and an abomasitis (*Ostertagia ostertagi*). The distal metacarpal and metatarsal bones were slightly enlarged due to the accumulation of osteous tissue on the periosteal surface surrounding the physis (Figure 3). On longitudinal sec-

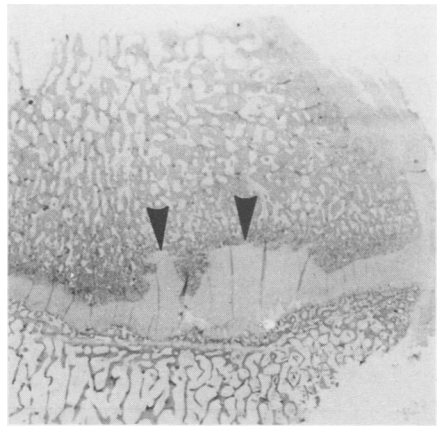

FIGURE 3. Longitudinal sections cut through the physis of the metacarpal bone. Note the focal overgrowth of cartilage (arrows). H & E. Approx. X3.5.

[1]Cumol, Cutter Laboratories Inc., Berkley, California.
[2]Tramisol, Cyanamid Canada Inc., Montreal, Quebec.

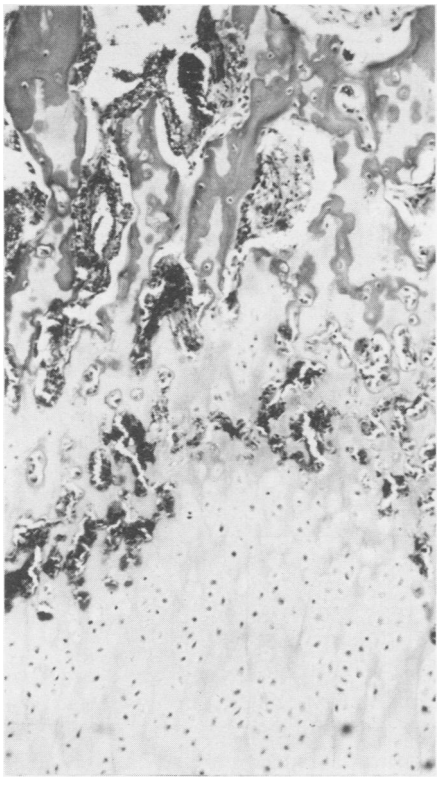

FIGURE 4. Microscopic view of area of cartilage overgrowth. Vascular invasion of cartilage is irregular. Osteoid appears to be present in normal amounts. H & E. Approx. X70.

tion of the metacarpal and metatarsal bones, the physis was irregular in thickness due to tongues of cartilage which extended into the metaphysis (Figure 4). In these areas, the zone of hypertrophic chondrocytes was greatly increased in thickness. There was no evidence of microfracture on the metaphyseal side of the physis although vascular invasion of the hypertrophic cartilage appeared to be occurring in an irregular manner (Figure 4). Growth plates at other sites and bone mass were judged to be normal. These skeletal lesions were absent in the treated calves but the chronic bronchopneumonia was present.

Discussion

The clinical, blood, liver and necropsy findings and the response to therapy support a diagnosis of copper deficiency.

Although a macrocytic hypochromic anemia is reported with copper deficiency (4,15), in our case the calves had a mild microcytic normochromic anemia. It is more logical to expect a microcytic anemia as there is an impairment of iron transport in the plasma and impaired iron release from the reticuloendothelial cells. These create a decreased availability of iron for erythrocyte production despite normal to high iron concentrations. The impairment of iron transport is attributed to a decrease in ferroxidase I (ceruloplasmin) and ferroxidase II activity. The action of both is dependent on the presence of copper in their structure (4,6,7).

There was no obvious response in the anemia to copper therapy. This may be related to a chronic low grade infection (bronchopneumonia) present in these calves (12).

The plasma copper concentration of selected cows and calves throughout the ranch were below normal (Table II). Underwood indicates that plasma copper concentrations below 0.5 μg/mL are indicative of depleted liver copper stores and copper deficiency in cattle. Calves born to copper depleted cows fail to receive adequate copper through placental transfer or through the colostrum (15).

Despite uniformly low plasma copper levels in all the animals sampled, only calves confined to one pasture showed clinical signs of copper deficiency. Parasitic bronchopneumonia and gastrointestinal parasites had likely precipitated the clinical signs. Some authors suggest that copper deficiency makes calves more susceptible to pneumonia and internal parasites (10). The plasma copper concentration may not be an accurate assessment of the actual copper stores in animals with a concurrent infectious disease. During infections of tissue necrosis, plasma copper concentrations are elevated as a result of increased ceruloplasmin synthesis (1).

The skeletal defect is related to a diminished stability and strength in bone collagen. Lysyl oxidase, a copper dependent enzyme is required for collagen cross linking (11). The physeal lesions seen in these calves agree with the observations seen in primary and secondary copper deficiencies (13,14).

The prevalence of copper deficiency in the summer months would be related to the rapid growth of herbage and to the high soluble protein content of immature plants probably increasing the ruminal sulfide and binding available copper (15). In the spring of 1976 in northcentral Manitoba there was abundant moisture and growth of lush pastures throughout the grazing season. The use of nitrogen fertilizer can aggravate a copper deficiency in herbage by increasing the rate of growth and diluting the absorbed nutrients in the plant tissue (2).

The diagnosis of a copper deficiency in this case is in contrast to a previously diagnosed molybdenum induced copper deficiency reported in the Swan River District of Manitoba (3). The liver and feed concentrations of molybdenum in the present case were normal. A secondary copper deficiency cannot be ruled out as other factors such as high levels of dietary sulphur, cadmium, zinc, mercury and phytates have been reported to interfere with copper absorption (15).

The use of copper sulfate in the loose salt fed free choice as treatment was successful in the cases we have treated. A 2.5-5.0% level was adequate to alleviate clinical signs and to increase plasma copper levels. The major problem with using a copper supplemented mineral or salt mix is to ensure adequate intake especially if the water supply is saline. To overcome this problem the salt or mineral can be added directly to a supplemental feed. This often is not practical in a pasture situation. Miltimore *et al* found that a level of 0.5% copper sulfate in the salt fed *ad libitum* was adequate and would increase the liver copper concentration (8). This level is likely too low when first treating the clinical deficiency. Once clinical signs are no longer evident the animals could possibly be maintained at the 0.5% level.

Acknowledgments

The authors thank Dr. D. Finley and Dr. J.N. Smart for bringing this case to our attention and Dr. S. Reinhardt for reading the radiographs.

References

1. BIESEL, W.R. Trace elements in infectious processes. *In* Medical Clinics of North America. 60: 831-849. Philadelphia: W.B. Saunders Co. 1976.
2. CHAUDHRY, F.M. and J.F. LONERAGAN. Effect of nitrogen, copper and zinc nutrition of wheat plants. Aust. J. Agric. Res. 21: 865-880. 1971.
3. CUNNINGHAM, H.M. , J.M. BROWN and A.E. EDIE. Molybdenum poisoning of cattle in

the Swan River Valley of Manitoba. Can. J. agric. Sci. 33: 254. 1953.
4. CUNNINGHAM, I.J. Copper and molybdenum in relationship to diseases of cattle and sheep in New Zealand. Copper Metabolism. A symposium on Animal, Plant and Soil Relationships. pp. 246-273. Baltimore: John Hopkins Press. 1950.
5. GIVENS, D.I. and J.R.HOPKINS. The availability of copper to grazing ruminants in parts of North Yorkshire. J. agric. Sci., Camb. 91: 13-16. 1978.
6. MATRONE, G. Interrelationships of iron and copper in the nutrition and metabolism of animals. Fedn Proc. 19: 659-665. 1960.
7. MILLS, C.P., A.C. DALGARNO and G. WENHAM. Biochemical and pathological changes in tissues of Friesian cattle during the experimental induction of copper deficiency. Br. J. Nutr. 35: 309-330. 1976.
8. MILTIMORE, J.E., C.M. KALNIN and J.B. CLAPP. Copper storage in the livers of cattle supplemented with injected copper and with copper sulphate and chelated copper. Can. J. Anim. Sci. 58: 525-529. 1978.
9. NATIONAL RESEARCH COUNCIL #4. Nutrient Requirements of Beef Cattle. 5th Edition. Washington D.C.: National Academy of Sciences. 1976.
10. PEEK, I.S. Hypocuprosis-hypomagnesaemia complex associated with pediculosis, and a predisposition to pneumonia in overwintered single suckled calves. Vet. Rec. 88: 318-321. 1971.
11. RUCKER, R.B. and J. MURRAY. Cross-linking amino acids in collagen and elastin. Am. J. clin. Nutr. 31: 1221-1236. 1978.
12. SCHALM, O.W., N.C. JAIN and E.J. CARROLL. Veterinary Hematology. Third Edition pp. 462. Philadelphia: Lea and Febiger. 1975.
13. SMITH, B.P., G.L. FISHER, P.W. POULAS and M.R. IRWIN. Abnormal bone development and lameness associated with secondary copper deficiency in young cattle. J. Am. vet. med. Ass. 166: 682-688. 1975.
14. SUTTLE, N.F. and K.W. ANGUS. Effect of experimental copper deficiency on the skeleton on the calf. J. comp. Path. 88: ;137-148. 1978.
15. UNDERWOOD, E.J. Trace Elements in Human and Animal Nutrition. 4th Edition. pp. 56-101. New York: Academic Press. 1977.

LETTERS TO THE EDITOR

Correct Syntax is Part of a Good Scientific Paper

DEAR SIR:

It is my opinion that, frequently, modern scientific writing, including that of veterinarians, is a distorted parody of desirable writing. One reads scientific papers and books, of which many are written by individuals who are eminent in their areas of expertise, to find that some of these manuscripts have been prepared with minimal or no regard for correct syntax. For example, I am amused and dismayed by the published statement, *"Each (virus) causes . . . lesions in swine that are indistinguishable"*. (Sic). There is no doubt that many swine *are* indistinguishable — that is what the sentence *tells* us — but I assume that the author *means* something quite different! I wish that he had written what he meant or that editorial intervention had required that he do so. It may be argued that one should not be concerned with the niceties of correct syntax if the scientific content of a paper is factual and comprehensible. This argument has some merit, but it sidesteps the point that, as members of a profession, we are careless and complacent in our writing. In the race for individual and collective recognition, we tend to sacrifice both the accuracy and the beauty of the English language to the more callous demands of speed and so-called efficiency.

My comments are not directed specifically toward our two Canadian publications, but they are concerned with what I believe are seriously declining standards of many veterinary and other journals, books and theses written in the English-speaking idiom. I may be taken to Task (a place in Siberia!) for daring to attack the sacred cow of modern veterinary writing, and for pointing out the apparently unending grammatical errors of our ways. In my opinion, however, it is time that someone addressed this matter. It is gratifying to know that I am not alone in this plea for improved writing (1, 2, 3).

It is unfortunate that, as readers of veterinary topics, we are assailed with misplaced modifying words and phrases, and with nouns that are used to modify nouns (e.g. *liver pathology, horse blood, dog blood cells* (!) etc.) and with combinations of singular subjects and plural verbs (e.g. *"A total of 100 cattle were* (Sic) *treated")*. In addition, we are told of *chick embryos, fetal calf serum, this data/data is,* and the redundant *histopathological lesions* and *large macrophages.* We read constantly of the incorrect *symptoms* in lower animals rather than of the correct *signs.* As well, *alveolar epithelialization* and *prone,* continue to assault our senses. *Prone* is the opposite of *supine* and should be used only in that context; in my view *alveolar epithelialization* is a misleading phrase because its use implies that epithelium did not exist previously. *Autopsy* may have been good enough for Rokitansky and for other pathologists of human conditions, but an examination of the root of the word indicates that it has a dubious place in veterinary literature. *Trimester,* a word that means *a period of three months,* is used frequently and incorrectly to divide gestational periods into three equal segments of time. It is correct for species that have gestational periods of nine months, but its use for those having shorter or longer such periods is questionable, and clearly, is impossible for canine and feline species.

Unfortunately, it is convenient to make scapegoats of editors and reviewers of veterinary and other journals, for this state of affairs. Short of rewriting the paper for authors however, editors and their reviewers should accept some of the responsibility for the grammatical and other accuracy of the final manuscript. In reality, the main problems exist probably a) because most writers are concerned primarily with the scientific accuracy of their material, b) because of the inability of some authors to write correctly, c) because of a casual or non-existent system of reviews within the institutions to which many authors belong, and finally, d) because