cessfully the diseased lung. The importance of early diagnosis especially before metastases[7] have occurred clearly indicates the opportunity for cure. More and more 5 year cures following pneumonectomy of the cancerous lung are being reported (Overholt).[8]

Obviously, attention must be sharply focussed on the early diagnosis of this lesion.[9] Perhaps the most important single factor in its diagnosis is that physicians think of the possibility of bronchogenic carcinoma. As shown in the present study the earliest clinical evidence in a majority of cases is persistent cough, dry at first, later productive. The sputum may or may not contain blood. Wheezing, dyspnoea, pain in the chest and hemoptysis commonly occur. The above evidences should at once suggest the possibility of the disease, particularly if they occur in the male sex after age 40.

It was of interest in this series that relatively few abscesses were found as the presenting symptom of the carcinoma. There was also a relatively low percentage of involved cervical lymph nodes.

The occurrence of any or several of these symptoms should not only arouse suspicion in the physician's mind but should compel him to make a complete clinical examination including an x-ray of the chest. Regardless of the outcome of the examination, if the symptoms persist, the patient should be bronchoscoped. The present study, in accordance with the literature,[2,5,10] shows that the majority of bronchogenic neoplasms arise in the main bronchi, thus being easily visualized by endsocopic examination. It is true that some of the lesions occur in lobar or smaller bronchi and may not be seen through the bronchoscope. In such cases however, the roentgenogram often reveals the tumor. In some instances, exploratory thoracotomy may be necessary. One thing is certain, vigorous prosecution of diagnostic measures will reveal the identity of the lesion in the majority of patients.

SUMMARY

A clinical and pathological study of 50 cases of primary carcinoma of the lung is reported. It was found that the diagnosis was usually made in the late or terminal stages of the disease. Clinical data leading to an earlier diagnosis is outlined.

384 Post Street.

REFERENCES

1. Mattick, W. L.: Primary Bronchogenic Carcinoma, a Diagnostic and Therapeutic Consideration, Radiology, 30:741, 1938.
2. Singer, J. J.: Primary Bronchogenic Carcinoma, a Clinical Study, Surgery, 8:910, 1940.
3. Stein, J. J., and Joslin, H. L.: Carcinoma of the Bronchus, a Clinical and Pathological Study of 164 Cases, Surgery, Gyn., and Obst., 66:902, 1936.
4. D'Aancy, R., Pearson, B., and Halpert, B.: Carcinoma of the Lung, Am. Jour. Path., 15:567, 1939.
5. Halpert, B.: Carcinoma of the Lung, a ten-year survey of Necropsies in the Charity Hospital at New Orleans, J.A.M.A., 117:1090, 1941.
6. Overholt, R. H.: A Common Masquerading Lung Disease, Dis. Chest, 9:197, 1943.
7. Samson, P. C.: The Relation of Cell Type to Metastasis in Bronchogenic Carcinoma, Am. J. Cancer, 23:754, 1935.
8. Overholt, R. H., and Rumel, W. R.: Clinical Studies of Primary Carcinoma of the Lung, an Analysis of Seventy-five Cases, Twenty-one of Which Were Treated by Pneumonectomy or Lobectomy, J.A.M.A., 114:735, 1940.
9. Hochberg, L. A., and Lederer, M.: Early Manifestations of Primary Carcinoma of the Lung, Arch. Int. Med., 63:80, 1939.
10. Jaffe, R. H.: The Primary Carcinoma of the Lung, a Review of 100 Autopsies, J. Lab. and Clin. Med., 20:1227, 1935.

Lanfranc of Milan (d. 1316) describes thirty-two forms of ulcers in his *"Chirurgia Magna"* and *"Minor."*

Roland of Parma, who flourished in 1250 and who was the pupil of Roger, advocated the excision of chancres.

EDEMA OF THE EYELIDS IN TRICHINOSIS*

PERRY N. PIEROSE, M. D.
AND
EDWARD M. BUTT, M. D.
Los Angeles

Introduction.—Recent studies and a review of the literature[12,13,19,20,22,24,25,27,33] reveal the fact that approximately twenty per cent of the general population are infected with trichinae. It appears also that very little effort has been made to determine the basis of one of the conspicuous symptoms of trichinosis, namely, edema of the eyelids. It is because of this fact that the following study was undertaken. The autopsy findings in two of the eleven unselected patients included in this study are of special interest since their extra-ocular muscles were found to be heavily infested with both calcified cysts and live-worm forms of Trichinella spiralis.

METHOD

The material studied was obtained from autopsies upon the bodies of eleven unselected patients. In each instance, the extra-ocular muscles were removed and examined by pressing small pieces of each rectus muscle between heavy plate glass and looking for trichinae with a dissecting microscope. Also, whenever possible, approximately 50 grams of the following muscles were removed from the same body, namely, laryngeal, deltoid, sternocleidomastoid, pectoralis major, diaphragm, rectus abdominis and gastrocnemius. The digestion technique was employed in searching for trichinae in these muscles.

DISCUSSION

Tiedman,[2,21] in 1882, was probably the first to observe Trichinella spiralis in human muscle, but R. Owen gave the parasite its present name some fourteen years later. It was not until 1860 that Zenker[2] disproved the commonly held views, both that trichinellae were harmless hosts of man and that they were larval forms of either "Strongylus" or "Trichocephalus," as was believed by such eminent men as Virchow and Kückermiester. Shortly afterward, he demonstrated the cycle of development of Trichinella spiralis. Another great contribution of fact concerning this disease was made by Herrick and Janeway[15] in 1909 when they first demonstrated the parasite in the circulating blood of man.

In the study reported here, trichinae were found in the extraocular muscles from two of the eleven unselected bodies investigated and also in the skeletal muscles removed from four bodies exclusive of the extra-ocular muscles. A review of the literature reveals that very few investigators have actually found trichinae in the extra-ocular muscles. Von Herrenschwand[32] reported such a finding in one body in 1927, which he illustrated. Fuchs[11] also illustrated a case in 1927. Another illustration of trichinae in the extra-ocular muscles is found in Friedenwald's[10] text published in 1929. The statement[10,16] that "Edema of the eyelids is due to an infestation of the extra-ocular muscles with trichinae," is made frequently. However, we have been able to find the records of only three instances in which trichinae have been demonstrated in these muscles. It is true that a muscle infested with trichinae is accompanied by edema, and that edema of the eyelids could result from infestation of the extra-ocular muscles with trichinae, but it does not follow that edema of various tissues, such as

* From the Los Angeles County Hospital and the Departments of Pathology and Medicine of the University of Southern California School of Medicine.

TABLE 1.—*Trichina Findings. Eleven Patients.*

Patient	Age	Sex	Race	Trichina in Muscles								Cause of Death (Autopsy)	Remarks
				Extra-Ocular	Laryngeal	Sternocleidomastoid	Deltoid	Pectoralis Major	Rect. Abdominis	Diaphragm	Gastrocnemius		
1	78	M	C	326†	100+†	25†		200+†	100+†	700+†	25†	Coronary Sclerosis; congestive heart failure; carcinoma of hand.	Artist. For years had occasional twitching of lids.
2	70	M	C	0	0	0	0	0	0	1†	0	Richter's Hernia with intestinal obstruction; pre-renal azotemia; bronchopneumonia.	
3	74	M	C	0	0	0	0	0	0	0	0	Bronchopneumonia.	
4	64	M	C	0	0	0	0	0	0	0	0	Tuberculosis, Pericarditis, Pneumonokoniosis.	
5	73	M	C	0	2*	10*		40*	11*	50*		Coronary Occlusion.	No History.
6	67	M	C	195† 185*	5–10 live worms and calcified cysts per each sq. cm. surface of all these muscles.							Carcinoma Bladder with Ureteral Obstruction. Pyeponephritis. Uremia.	Occupation—Butcher for 10 years before death.
7	73	M	C	0	0	0	0		0	0	0	Pulmonary Tuberculosis.	
8	72	M	C	0	0	0	0	0	1*	0	0	Lobar Pneumonia. Suppurative Pleurisy. General Arterio Sclerosis. Severe Myocardial damage.	
9	38	M	C	0	0	0	0	0	0	0	0	Perforated peptic ulcer. General Peritonitis; Chronic Alcoholism with Delirium.	
10	68	M	C	0	0	0	0	0	0	10*	0	Ureteral Stricture with Urinary Extravasation. Bronchopneumonia. Carcinoma mouth.	
11	68	M	C	0	0	0	0	0	0	0	0	Hypertensive Arteriosclerotic Heart Disease.	

* Live worms.
† Calcified cysts.
Note: Patient No. 6:—The autopsy was limited so that only the extra-ocular muscles were removed. Biopsy was used to confirm the gross findings.

the eyelids, is always accompanied by trichinae in the edematous structure. What is not known at present is whether or not edema of the eyelids occurs in patients who have trichinosis and who do not have infestation of the extra-ocular muscles. It must also be realized that edema of the eyelids, as it occurs in patients who have trichinosis, may be a local non-specific manifestation of toxemia which results from a generalized invasion of the body exclusive of the extra-ocular muscles, and that in those patients who have infestation of the extra-ocular muscles the edema of the eyelids is merely incidental. Supporting this view are the numerous observa-

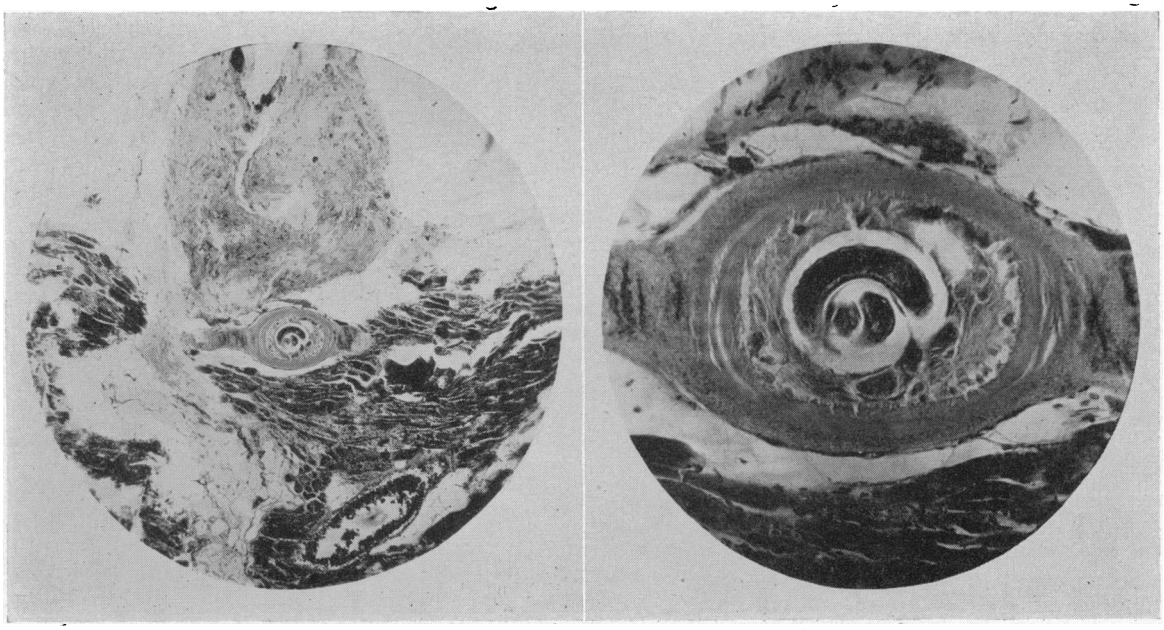

Fig. 1.—Low Power Trichina Work Encysted in Extra-Ocular Muscle. Patient No. 6. High Power of Same.

tions[4,8,9,14,18,23,29,30,31] found at autopsy in patients dying of trichinosis, reporting pathological evidence of toxic changes in the kidneys, heart, meninges, and brain, in which organs no trichinae were found. These toxic changes are therefore a non-specific manifestation because they occur in tissue in which no trichinae are present. As these non-specific toxic changes do occur in the above tissue, it is reasonable to believe that they could also occur in the tissues around the eyes and thereby serve as the basis by which to explain edema of the eyelids, rather than the commonly held view that the edema is due to the presence of trichinae in the extra-ocular muscles. This view would be proved if it could be demonstrated that edema of the eyelids occurred in proven cases of trichinosis in which no trichinae were found at autopsy in the extra-ocular muscles or in the tissues around the eyes, and if no other causes of the edema could be demonstrated.

It appears that the cause of edema of the eyelid in patients who have trichinosis has not been satisfactorily explained.

In the study reported here, two patients who had trichinosis were found to have the extra-ocular and other skeletal muscles heavily infested with trichinae. In none of these patients was edema of the eyelids observed before death, according to their hospital records. In six of the eleven bodies studied trichinae were demonstrated. Undoubtedly,[3] less discrimination is practiced among this group of charity patients in the selection and preparation of their diet than is practiced by the population at large, which factor may help explain the high incidence. However, this group is too small from which to draw any conclusion regarding a true incidence.

CONCLUSIONS

1. The commonly held view that "edema of the eyelids in trichinosis is due to the presence of trichinae in the extra-ocular muscles" lacks sufficient supportive evidence to date and must therefore be considered an assumption.

2. The concept is advanced that the edema of the eyelids as it occurs in trichinosis may be principally a non-specific toxic manifestation and not entirely due to the presence of trichinae in the extra-ocular muscles or tissues around the eyes.

3. Two instances of extra-ocular-muscle trichinosis occurring in the eleven unselected patients investigated are reported and illustrated.

4. Trichinae were demonstrated in six of the eleven bodies studied.

5. In none of these patients had there been recorded clinical symptoms of trichinosis.

Station Hospital, Fort McDowell, Angel Island.
1200 North State Street.

REFERENCES

1. Blumer, G.: Yale J. Biol. & Med., 11:581-88 (July), 1939.
2. Braun, M.: Text: Animal Parasites of Man, 1st edit., 1906.
3. Butt, E. M., and Lapeyre, J. L.: Calif. and West. Med., 50: No. 5.
4. Cabot, R. C.: Text: Mod. Clin. Med., 1911, p. 558.
5. Carter, L. F.: J. of the A.M.A., 95: No 19 (Nov. 8), 1930.
6. Cecil, R. L.: Text of Med., 3rd edit., p. 498.
7. Christian, H. A.: Oxford Syst. Med., Vol. V: part III, p. 996.
8. Dunlap, G. L., and Weller, C. V.: Prac. Soc. Exper. Biol. and Med., Vol. XXX: 1261, 1933.
9. Flury, F.: Arch. f. Exper. Path. u PharmaKol. LXXIII: p. 164.
10. Friedenwald, J. S.: Text: The Pathology of the Eye, p. 241, 1929.
11. Fuchs, A.: Atlas of the Histopathology of the Eye, Part II, plate 14, 1927.
12. Hall, M. C.: Pub. Health Rept. LII: 539, 1937.
13. Hall, M. C., and Collins, B. J.: Pub. Health Rept. LII: 468, 1937.
14. Hassin, G. B., and Diamond, I. B.: Arch. Neurol. and Psychiat. XV: 34, 1926.
15. Herrick, W. W., and Janeway, T. C.: Arch. of Int. Med., Vol. III: 263, 1909.
16. Hickling, R. A.: Brit. M. J., 2:654 (Oct. 10), 1931.
17. Horlick, S. S.: N. Eng. J. Med., Vol. 20:816 (October), 1929.
18. Kaufman, R. E.: Ann. of Int. Med., Vol. 13: No. 8, 1439 (February), 1940.
19. Magath, T. B.: J.A.M.A., 108:1964, 1937.
20. McNaught, J. B., and Anderson, E. V.: J.A.M.A., 107:1446, 1936.
21. Osler, W.: Text: Princips. & Pract. of Med., 13th edit., p. 417.
22. Pote, T. B.: Am. J. Med. Science, CXCVIII: 47, 1939.
23. Pund, E. R., and Nosteller, R.: J.A.M.A., Vol. 102: No. 15, 1221 (April 14), 1934.
24. Queen, F. B.: J. Parasit. 18:128, 1931.
25. Riley, W. A., and Scheifley, C. H.: J.A.M.A., 102: 128, 1934.
26. Scheifley, C. H.: Proc. Staff Meet. Mayo Clinic, 12:367-68 (Jan. 9), 1937.
27. Scheifley, C. H.: Am. J. Hygiene XXVII: 142, 1938.
28. Shapiro, M. M., Crosley, B. L., and Sickler, M. M.: Jr. Lab. and Clin. Med., 23:681-87 (April), 1938.
29. Sobel, I. P.: Am. J. Dis. Child., LI:367, 1936.
30. Spink, W. W.: Ann. Int. Med., LVI:238, 1935.
31. Spink, W. W., and Augustine, D. L.: J.A.M.A., CIV: 1801, 1935.
32. Von Herrenschwand, F.: Graefe's Arch. für Ophth., 119:374, 1927.
33. Wright, W. H.: Am. J. Public Health, XXIX:119, 1939.

PSYCHIATRIC CASUALTIES*

PEARL S. POUPPIRT, M. D.
San Francisco

THE large percentage of psychiatric casualties in the Armed Forces is a matter of common knowledge. It is apparent that they serve the enemy's ends as effectively as do the casualties resulting from physical injury or infection. It is perhaps not so well known that military psychiatric casualties are not limited to personnel with combat experience.

In civilian life psychiatric casualties occur both as the result of direct enemy action (such as has been experienced by our Allies but not, as yet, by us in continental United States), and in the absence of an emergency, but related to war-time conditions. The recognition and treatment of the latter casualties constitute a valuable contribution that civilian psychiatrists can make to the war effort today. This would be a contribution not only towards military victory, but towards minimizing the detrimental effects of war conditions upon the population as a whole. However, this paper is restricted to a consideration of emergency treatment of psychiatric casualties resulting from enemy action against the civilian population.

Civilian psychiatric casualties are of great value to the enemy. One has only to recall recent incidents of blocked roads preventing troop movements and the desertion of vital defense posts, such as those charged with keeping open the lines of communication and transportation, to realize the importance panic can play in the defeat of a nation. To avoid such mass reactions each civilian should be informed of the danger of attack, the anticipated nature of the attack, the defense plans that have been made, and the duties he will be

* One of several papers in a Symposium on "Emergency Medical Service in Wartime." Papers collected by Henry Gibbons, III.

Note.—The article "Psychiatric Casualties," by Pearl S. Pouppirt, M.D., which appears here was not printed in the "Symposium on Emergency Medical Service" which appeared in CALIFORNIA AND WESTERN MEDICINE for October, 1944, because of lack of space.