SELF ASSESSMENT ANSWERS

Low HbA1c levels in a poorly controlled diabetic

Q1: What do the data demonstrate?

The data demonstrate inappropriately low HbA1c values in a subject with symptomatic hyperglycaemia (weight loss, osmotic symptoms, and high plasma glucose values) and abundant glycosuria.

Q2: What is the differential diagnosis and what would you do next?

If a laboratory error can be ruled out (repeated samples need to be obtained), the main differential diagnosis is of an abnormal haemoglobin variant. Some causes of abnormal HbA1c values are listed in box 1. The next step is to perform haemoglobin electrophoresis. The following results were obtained in this patient:

- Alkali/acid elution: haemoglobin A + J (confirms the presence of abnormal haemoglobin J).
- Globin: fast beta chain variant (abnormal beta chain).
- Isoelectric focusing: haemoglobin A + J.
- Abnormal haemoglobin: 48% (a high percentage of haemoglobin J)
- Haemoglobin A2: 2.58% (normal <3%).
- Sickledex: negative (no evidence of sickle cells).
- Haptoglobin: 0.28 g/l (normal 0.7–3.19).

These tests are consistent with a diagnosis of haemoglobin beta chain variant: J trait.

Q3: What is the pathophysiological basis of the discrepancies observed and how would you assess this man's long term glycaemic control?

Non-enzymatic binding of glucose to the valine residue of the beta chain of the haemoglobin molecule gives rise to glycated haemoglobin (HbA1a, HbA1b, and HbA1c). The level of HbA1c reflects ambient blood sugar concentrations during the life span of the patient's red cells (half life about 6–8 weeks)—that is, uncontrolled hyperglycaemia results in high HbA1c levels. Current guidelines recommend HbA1c levels of less than 7% as a target for satisfactory control. HbA1c can be measured chemically, chromatographically, and electrophoretically.[1] Most autoanalysers use the chromatographic method. Haemoglobin variants may affect chromatographically measured HbA1c levels either by inducing an abnormal peak and thereby making the estimation of the fraction of HbA1c unreliable, or by reducing time available for glycation as a result of reduced red cell survival. These two effects may coexist.[2] Physicians should be aware of the potential pitfalls of HbA1c as a measure of long term diabetic control. Apparent discrepancies between glycaemic control reflected in day to day blood glucose concentrations, and HbA1c values should be noted. HbA1c levels are inappropriately affected by factors other than long term glycaemia as shown in boxes 1 and 2. Schnedl *et al* reported a prevalence of abnormal haemoglobin variants of 0.6% among 15 000 HbA1c estimations in a period of over six years.[3] In such individuals a method unaffected by abnormal haemoglobin variants, such as a turbidimetric inhibition immunoassay[4] or alternate methods of chromatography[5] should be used.

Box 1: Causes of high/low HbA1c levels

High
- Newly diagnosed diabetes mellitus.
- Uncontrolled diabetes mellitus.
- Non-diabetic hyperglycaemia: acromegaly, phaechromocytoma, thyrotoxicosis, Cushing's syndrome.
- Splenectomy.
- Alcoholism.

Low
- Haemolytic anaemia: congenital (for example, spherocytosis and elliptocytosis), haemoglobinopathies, acquired haemolytic anaemias—for example, drug induced (dapsone, methyldopa).
- Chronic blood loss.
- Chronic renal failure (variable).

Box 2: Abnormal haemoglobin variants and HbA1c

High HbA1c
- HbF
- HbE
- HbD
- HbJ Capetown
- Hb Raleigh

Low HbA1c
- HbS
- HbC
- HbJ
- HbG
- Hb Ramadan

Final diagnosis

Abnormal haemoglobin variant.

References

1 **Kahn CR**, Weir GC, eds. *Joslin's diabetes mellitus*. 13th Ed. Philadelphia: Williams and Wilkins, 1994: 400.
2 **Gunton JE**, McElduff A. Haemoglobinopathies and HbA1 measurement. *Diabetes Care* 2000;**23**:1197–8.
3 **Schnedl WJ**, Trinker M, Lipp RW. HbA1c determination in patients with haemoglobinopathies. *Diabetes Care* 1999;**22**:368.
4 **Chang J**, Hoke C, Ettinger B, *et al*. Evaluation and interference study of hemoglobin A1c measured by turbidimetric inhibition immunoassay. *Am J Clin Pathol* 1998;**109**:274–8.
5 **Philcox JC**, Haywood MR, Rofe AM. Haemoglobin A1c by HPLC with the Pharmacia Mono S HR 5/5 cation-exchange column; influence of sample protein load on optimal chromatographic conditions. *Clin Chem* 1992;**38**:1488–90.

A bed bound patient

Q1: What is the differential diagnosis and the most likely diagnosis?

The differential diagnosis is wide (box 1, which is not exhaustive) and influenced somewhat by the past medical history. However, the most likely diagnosis is polymyositis. The presentation with proximal muscle tenderness, and importantly weakness, together with a raised ESR and raised creatine kinase is typical. The clinical picture may evolve over several weeks or months, as in this case.

Had the appropriate skin manifestations been present, dermatomyositis would have been an important consideration. Dermatomyositis is easily recognised and diagnosed because of the characteristic rash that may either accompany or precede the onset of muscle weakness. Classically there is a purplish discoloration of the eyelids (heliotrope rash) often associated with periorbital oedema and papular, erythematous, scaly lesions over the knuckles (Gottren's sign). In addition, a flat, erythematous, sun sensitive rash may appear on the face, neck, and anterior chest (V sign), on the shoulders and upper back (shawl sign), and on the elbows, face, and malleoli. The nail beds often have dilated capillary loops and calcifications may be found in the subcutaneous tissues, although this is much less common in adults than children with this condition.

Inclusion body myositis is characterised clinically by the insidious onset of slowly progressive weakness. The slow evolution of symptoms contributes to the delay in diagnosis, which averages six years. Distinct from polymyositis and dermatomyositis, males are much more commonly affected than females and the clinical hallmark is early weakness of the quadriceps, wrist and finger flexors, and the ankle dorsiflexors. Invariably, the manual muscle scores of the finger and wrist flexors are lower than those of the shoulder abductors. Typically the serum creatine kinase is normal or only mildly raised.

The high ESR and the patient's age in combination with the marked muscle tenderness may point to polymyalgia rheumatica. However, although this condition is characterised by pains and early morning stiffness in the proximal muscles of the shoulder and pelvic girdle, the hands and feet are not affected and there is no muscle weakness. There are also usually some systemic features of a low grade fever or malaise. It is three times more

Box 1: Differential of chronic proximal muscle weakness in adults

- Polymyositis.
- Dermatomyositis.
- Inclusion body myositis.
- Virally mediated myositis: HIV, HTLV-1, influenza, coxsackie, adenovirus, herpes simplex virus, Epstein-Barr virus.
- Chronic inflammatory demyelinating polyradiculoneuropathy.
- Endocrine myopathy: hyperthyroidism, hypothyroidism, acromegaly, Cushing's syndrome, Addison's disease, Conn's syndrome, hypoparathyroidism.
- Myasthenia gravis.
- Sarcoid myopathy.
- Diabetic amyotrophy.
- Drug induced: alcohol, β-blockers, fibrates, diuretics, phenytoin, vincristine, zidovudine.
- Muscular dystrophies: limb girdle dystrophy, facioscapulohumeral dystrophy.
- Disorders of glycogen metabolism: acid maltase deficiency, myophosphorylase deficiency.
- Mitochondrial cytopathy.

common in women than in men and usually occurs between the ages of 60–70 years.

Chronic inflammatory demyelinating polyradiculoneuropathy (CIDP) is an immune mediated neuropathy characterised by a relapsing or progressive course. By definition, symptoms and signs of the neuropathy must be present for at least two months, which distinguishes CIDP from Guillain-Barré syndrome. With a peak incidence in adults of ~ 40–60 years of age, the majority of patients present with symmetric proximal and distal weakness of the arms and legs. Importantly, at least 80% of patients have both motor and sensory involvement, although one may predominate. Although the hyporeflexia seen in this case is compatible with CIDP, muscle tenderness would not be expected and the ESR and creatine kinase would typically not be raised. A raised cerebrospinal fluid protein is found in 80%–95% of patients, antibodies directed against myelin proteins are present in a small percentage of patients, and as many as 25% have an IgA, IgG, or IgM monoclonal gammopathy.

This patient's history of type II diabetes mellitus makes one consider the possibility of a diabetic amyotrophy (also known as diabetic lumbosacral radiculoplexopathy), especially given the pain and the weakness of her quadriceps muscles and the absent knee reflexes. However, this disease mainly affects men and does not affect the upper limbs. Most patients have non-insulin dependent diabetes mellitus and although commonly associated with periods of poor glycaemic control, the development of this neuropathy is often unrelated to glucose control or the duration of glucose intolerance. In this patient glycaemic control had been satisfactory with a glycated haemoglobin (HbA1c) of 6.5%. In diabetic amyotrophy, the neuropathy begins with severe pain in the back, hip or thigh, the pain typically characterised as burning, knife-like, and aching. On examination there is weakness of hip flexors and extensors, knee flexors and extensors, and ankle dorsiflexors and plantar flexors of varying degree. Profound atrophy of both thigh and at times distal lower extremity muscles develops.

There are many other metabolic and endocrine causes of a proximal myopathy including hyperthyroidism, myxoedema, Cushing's syndrome, acromegaly, osteomalacia, Addison's disease, and primary hyperaldosteronism. Those seen in metabolic bone disease, myxoedema, Cushing's and Addison's may all be associated with muscle pain at rest and both myxoedema and acromegaly may sometimes result in an increased creatine kinase. In this patient the hormone profile was normal.

A myasthenic syndrome must always be considered in any cause of muscle weakness. It may also cause a mainly proximal muscle weakness, but the lack of demonstrable fatiguability and the presence of muscle pain would be atypical. The raised creatine kinase, in this patient, is also against the diagnosis.

Q2: How would you confirm the diagnosis?

The diagnosis of polymyositis would be assisted by electromyography and muscle biopsy. Electromyography is usually abnormal in polymyositis with the following features: increased insertional and spontaneous activity with fibrillation potentials, positive sharp waves, and occasionally pseudomyotonic and complex repetitive discharges; small duration, low amplitude, polyphasic motor unit potentials; and motor unit potentials that recruit early but at normal frequencies. However, it can be normal if and uninvolved part of a muscle is sampled.

Muscle biopsy should come from a moderately weak muscle and preferably from a tender area. The predominant histological features in polymyositis are variability in fibre size, scattered necrotic and regenerating fibres, and endomysial inflammation with invasion of non-necrotic muscle fibres. All of the invaded and some of the non-invaded muscle fibres may express major histocompatibility complex class I antigen which is not normally present in the sarcolemma of muscle fibres. The endomysial inflammatory cells consist primarily of activated CD8+ alpha, beta T cells, and macrophages. Again, because can be patchily involved in polymyositis, biopsy can be normal.

Q3: What are the associations of this condition?

It has been known for some time that dermatomyositis and polymyositis are both associated with malignancy. There are some questions remaining as to the exact nature of the association between myositis and malignancy, the temporal relationship being unclear. In some patients, pre-existing myositis recurs in patients with a new diagnosis of malignancy and in patients with a relapse of malignancy, myositis has occurred de novo.[1 2] Dermatomyositis is associated with underlying malignancy especially gastric and lung in men and ovarian and cervical in women. Polymyositis is also associated with a higher incidence of underlying malignancy at the time of diagnosis but to a lesser extent.[3] In a large Swedish population based study the incidence of cancer in patients with dermatomyositis and polymyositis was compared to that in the general Swedish population. In the 392 patients with dermatomyositis the incidence of cancer was 15% (relative risk 2.4 in men and 3.4 in women). In the 396 patients with polymyositis the incidence of cancer was 9% (relative risk 1.7 in men and 1.8 in women).[4]

In addition to the association with malignancy, myositis with secondary congestive heart failure or conduction abnormalities occur in up to one third of patients with polymyositis. Polyarthritis has been reported in as many as 45% of polymyositis patients at the time of diagnosis. Interstitial lung disease occurs in approximately 10% of polymyositis patients, at least half of whom have Jo-1 antibodies. These are antisynthetases associated with a more modest response to treatment and poorer prognosis and which are found in around 20% of patients with polymyositis overall. Other antibodies seen in polymyositis include antinuclear antibodies, seen in 16%–40% of cases, and antibodies against the signal recognition particle, found in ~4% of cases and associated with an acute onset of severe weakness, myalgias, and myocarditis.

Q4: How would you manage this patient?

The management of polymyositis can be considered from three different aspects: drug treatment of the disease, general supportive measures, and further investigation of the patient. The mainstay of drug treatment remains corticosteroids especially in controlling the early clinical course. Over 80% of patients at least partially improve, while 10%–33% completely respond to prednisolone.[5 6] Treatment with steroids is usually initiated with prednisolone 0.5 to 2.0 mg/kg per day. Normalisation of muscle enzymes usually occurs within four weeks of commencement of treatment in responders. Improvement in muscle strength occurs later, usually within 3–6 months. Once there has been a full response the dose of steroid may be gradually reduced (for example, by 5 mg every two weeks). During the period of dose reduction the patient should be monitored closely for evidence of relapse of the disease.

Patients who do not respond to corticosteroids could be considered for other treatment modalities such as intravenous immune globulin, which has been shown to be an effective therapy for drug resistant dermatomyositis and polymyositis.[7]

Methotrexate and azathioprine should also be considered in patients who do not respond well to steroids, patients at risk of steroid side effects and those with poor prognostic indicators such as dysphagia, disease duration of three months before treatment, and profound weakness (bed or chair dependence). Methotrexate is best avoided in patients with coexisting interstitial lung disease and azathioprine requires regular monitoring of haematology and liver function tests every two weeks until a stable dose is reached, and monthly thereafter.

Other treatments being evaluated for use in the treatment of dermatomyositis and polymyositis include plasmapheresis, cyclosporin, tacrolimus, cyclophosphamide, chlorambucil, tumour necrosis factor inhibitors, total body irradiation, and thymectomy.

General supportive measures include good nursing and medical care as well as physiotherapy and rehabilitation. Patients treated with high dose steroids should be given calcium and vitamin D supplementation to prevent osteoporosis. Postmenopausal women should be treated with oestrogen unless contraindicated and bisphosphonates have also been demonstrated to be effective in the prevention and treatment of osteoporosis.

There is debate as to the extent that patients with polymyositis should be investigated to exclude malignancy. There should be a thorough physical examination with breast, rectal, and pelvic examinations. The full blood picture, ESR, liver function tests, and bone profile should all be recorded. Urinalysis should be performed as well as chest radiography. Testing the stool for faecal occult blood and gastrointestinal endoscopy may be indicated and women should undergo mammography, pelvic ultrasonography, and have their serum CA-125 levels measured. Further investigation of the patient should be determined by the clinical signs and symptoms. It has been suggested that surveillance for malignancy should continue at annual intervals for at least two years after the initial evaluation.[8]

Discussion

Polymyositis is a non-suppurative inflammatory condition of the muscles characterised by necrosis of the muscle fibres with evidence of regeneration and inflammation. Generally it presents in patients over the age of 20 years and it is more prevalent in females. It may have a very acute presentation and this is often seen in children with polymyositis. The chronic form is characterised by progressive muscle weakness and tenderness. Because there is no associated skin rash, the diagnosis is often delayed when compared with dermatomyositis.

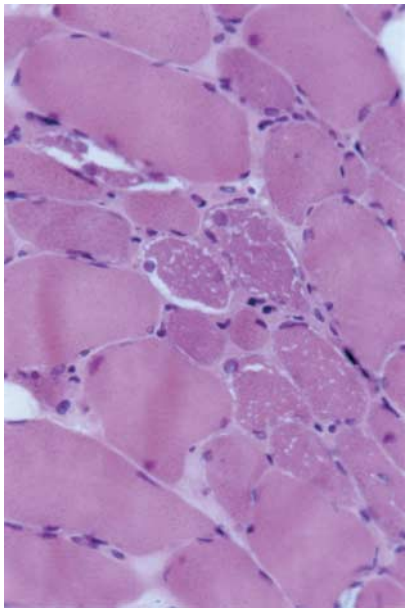

Figure 1 Needle biopsy from quadriceps indicating muscle fibre necrosis and loss together with a modest inflammatory cell infiltrate.

It is worth noting that only 50% of patients complain of tenderness, weakness being the main complaint. It may be associated with an arthralgia or arthritis. Around one third of cases have dysphagia secondary to oropharyngeal and oesophageal involvement and this appears to be a predictor of poor outcome.[9] Other potential features include Raynaud's phenomenon and Sjögren's syndrome.

The histological and immunological features on muscle biopsy suggest that polymyositis is the result of a HLA restricted, antigen specific, cell mediated immune response directed against muscle fibres. The trigger of this autoimmune attack is not known. A viral aetiology has been speculated, but there is no conclusive evidence supporting this theory.[10]

The raised creatine kinase together with the raised ESR gave rise to the clinical suspicion of an inflammatory myopathic process in this patient. This was supported by electromyography which showed spontaneous fibrillation and small motor units. However it was muscle biopsy that confirmed the diagnosis of polymyositis. It showed marked necrosis of muscle fibres and loss of muscle fibres (fig 1). However it showed relatively little inflammatory changes and this may be due to the length of time before presentation. Our patient was immediately started on oral prednisolone, ranitidine, calcium, and a bisphosphonate.

The difference between polymyositis and dermatomyositis is not merely determined by the presence or absence of a skin rash or the other clinical features listed above. Typically the muscle biopsy features are distinct. In dermatomyositis the characteristic histological finding is of perifascicular atrophy. Although scattered necrotic fibres may be present, in contrast to polymyositis and indeed inclusion body myositis, invasion of non-necrotic fibres is not prominent. In addition, inflammation is predominantly perivascular and located in the perimysium rather than the endomysium, and the infiltrate is mainly composed of CD4+ T cells, B cells, and macrophages.

Box 2: Learning points

- Polymyositis generally presents over the age of 20 years and is commoner in females.
- Presentation is with neck flexor and proximal limb weakness evolving over weeks or months.
- Dysphagia occurs in ~1/3 of patients due to oropharyngeal/oesophageal involvement.
- Jo-1 antibodies occur in ~20% of cases and are associated with a poorer prognosis.
- Risk of malignancy with polymyositis less than dermatomyositis but higher than in the general population.
- Inflammation in polymyositis is endomysial with invasion of non-necrotic fibres whereas in dermatomyositis it is perimysial with no involvement of non-necrotic fibres.
- Majority of patients respond favourably to immunosuppressive therapies but usually require lifelong treatment.

On initial assessment by occupational therapy and physiotherapy, the patient required the assistance of two persons to stand. Over the next 10 weeks, despite receiving intensive physiotherapy, and a concurrent substantial reduction in ESR (33 mm/hour), there was no improvement in the patient's clinical condition. It was decided that she was refractory to steroid treatment and she was started on a course of intravenous immune globulin at a dose of 0.4 g/kg over five days.

She was also started on azathioprine and after eight weeks of azathioprine treatment in combination with steroids she was mobilising with a walking frame under supervision. Her full blood profile and liver function tests were monitored weekly and regular creatine kinase measurements were made to exclude relapse. Serum creatine kinase can be useful in monitoring response to therapy but only in conjunction with the physical examination. The creatine kinase can be raised in patients with normal manual muscle testing, while weak patients can have normal levels.

Overall, this case emphasises the broad differential diagnosis of a painful proximal myopathy. The clinical, biochemical, electrophysiological, and pathological markers are typical of polymyositis and this patient demonstrates the clinical response to therapeutic intervention that can be expected in this condition.

Final diagnosis

Polymyositis.

Acknowledgements

Our thanks to Dr Mirakur (Consultant Neuropathologist, Royal Victoria Hospital) and Mr Roy Creighton (Technician) for supplying the photographic image.

References

1 **Callen JP**. The value of malignancy evaluation in patients with dermatomyositis. *J Am Acad Dermatol* 1982;**6**:253–9.
2 **Cox NH**, Lawrence CM, Langtry JA, *et al.* Dermatomyositis: disease associations and an evaluation of screening investigations for malignancy. *Arch Dermatol* 1990;**126**:61–5.
3 **Stockton D**, Doherty VR, Brewster DH. Risk of cancer in patients with dermatomyositis or polymyositis, and follow-up implications: a Scottish population based cohort study. *Br J Cancer* 2001;**85**:41–5.
4 **Sigurgeirsson B**, Lindelof B, Edhag O, *et al.* Risk of cancer in patients with dermatomyositis and polymyositis. *N Engl J Med* 1992;**326**:363–7.
5 **Amato AA**, Barohn RJ, Jackson CE, *et al.* Inclusion body myositis: clinical and pathological boundaries. *Ann Neurol* 1996;**40**:581–6.
6 **Joffe MM**, Love LA, Leff RL. Drug therapy of idiopathic inflammatory myopathies: predictors of response to prednisone, azathioprine, and methotrexate and a comparison of their efficacy. *Am J Med* 1993;**94**:379–87.
7 **Mastaglia FL**, Phillips BA, Zilko PJ. Immunoglobulin therapy in inflammatory myopathies. *J Neurol Neurosurg Psychiatry* 1998;**65**:107–10.
8 **Chow WH**, Gridley G, Mellemkjaer L. Cancer risk following polymyositis and dermatomyositis. A nationwide cohort study in Denmark. *Cancer Causes Control* 1995;**6**:9–13.
9 **Carpenter JR**, Bunch TW, Engel AG, *et al.* Survival in polymyositis: corticosteriods and risk factors. *J Rheumatol* 1977;**4**:207–14.
10 **Leff RL**, Love LA, Miller FW, *et al.* Viruses in idiopathic inflammatory myopathies: absence of candidate viral genomes in muscle. *Lancet* 1992;**339**:1192–5.

Lumbar facet synovial cyst

Q1: What is a lumbar facet synovial cyst?

Lumbar facet synovial cyst was first described in 1968 by Kao *et al.*[1] It is now being commonly reported with advanced neuroimaging techniques. It can pose serious diagnostic and therapeutic problems. The aetiology of this condition is degenerative including osteoarthritis, rheumatoid arthritis, and spondylolisthesis. It is commonly located at L4/5 in the most mobile part of the spine and is uncommon in cervical and thoracic regions. Repeated microtrauma is blamed for its aetiopathogenesis. It is related to the degenerative facet joint. It might be a very common cause of refractory low back pain with radicular pain; it is very rarely bilateral. It can present, although very rarely, acutely as an emergency and there have been reports of cervical cord compression and cauda equina syndrome after a bleed into this cyst. Elderly patients with low back pain and radiation with a leading symptom of aggravation of pain on standing and walking should be suspected.

Q2: How is it diagnosed?

Blood tests and radiographs are usually unhelpful. MRI is the investigation of choice.[2] The differential diagnosis with MRI could be a migrated disc fragment, a perineural cyst, schwannoma, and a extradural space occupying lesion. Pathologists divide these cysts into synovial and ganglion types but they do not have any prognostic significance

Q3: How is lumbar facet synovial cyst treated?

It is treated only if it is symptomatic.[3] If it is an incidental finding, analgesia can be given. Spontaneous disappearance has been reported in 10% of these cysts. Aspiration has led to recurrence and steroid injection into the cyst has been reported to increase the severity of pain. Surgery is the treatment of choice with excision of the cyst and associated laminectomy. If there is associated instability then fusion is the treatment of choice.