Perhaps I may add that:

1. We can never be sure that we have rendered an individual "focal infection" free, *e. g.*, once the dentine of a tooth has suffered from decay, its tubules have been invaded by organisms. They may remain permanently there, and I recall a number of patients in whom the most striking results followed the removal of an infected living tooth, which was located by the patient and not by me.

2. Most persons carry multiple infections. Even in those cases in which we are convinced that a particular condition is of focal infection origin, we are often unable to say which focus is at fault; and it has often happened that relief came only after the removal of the focus that was left to the last. A succession of such mutilations as the removal of all foci entails is distressing and not without risk to the patient. One must therefore weigh the benefit that can be expected to result against the distress and danger to be run, and advise accordingly.

FLETCHER B. TAYLOR, M.D. (400 Twenty-ninth Street, Oakland).—The capacity which any profession possesses for development depends upon its ability to coordinate the salient advances of allied sciences with itself. This may be called its "borrowing power."

The medical profession, more than any other, has need of scientific "borrowing power," and in our approach to a problem in focal infection it is necessary for us to "borrow" a judicial quality of mind which will enable us to weigh with unprejudiced attention several parallel lines of evidence at one time.

We are all well aware of the fact that no formula for medical procedure is infallible. There is some danger in habits of thought with reference to the treatment of focal infections. If the best service is to be delivered to our patients, we must be able to view impartially the new facts given us by research confrères, at the same time remaining conservative in their application.

In the consideration of focal infection there are three major opportunities which may bear emprahsis: first, the frank focus which is found in the routine examination of an otherwise healthy patient presents an excellent opportunity to prevent disease; second, the demonstrable focus in a young rheumatic patient is of importance if we want to protect that patient from bacterial endocarditis; third, and this is a matter for careful appraisal and conservative approach, the removal of inflammatory foci in chronic cardiovascular disease of the aged. Here more often supportive medical treatment is needed; less often, the surgical attack upon a focus of infection.

It is essential that before treatment is directed toward any one focus that all the foci be recognized. In this way a needless waste of money, time, effort, and even life may be avoided. Having found one or more foci in an individual we may then direct the therapeutic attack with proper consideration of accessibility of the focus, expense of treatment, and danger to the patient. The tonsils of a patient must not be removed while an aveolar dental abscess is overlooked. Deep-seated foci, expensive or dangerous in treatment, should wait for the clearing of superficial foci.

Those foci which have no drainage portals except by lymphatic channels or the blood stream are most important to the problem. Doctor Strietmann's plan of complete surgical attack on the dental focus is particularly stimulating to me. The work begun must be finished. The sigh of the surgeon who has just extracted an abscessed tooth should not be a sigh of satisfaction. The extraction is the beginning, not the end, of the treatment.

In general it is wise to avoid the sins of omission which are born of medical laziness or the patient's ideas of false economy. Thoroughness should be the keynote of the entire process. And, above all, it is our duty to be completely frank with patients in these as in other matters. We cannot make absolute promises and we must not appear to do so for the sake of medical argument and medical spoils. When we do we are faced with a focal infection in our own professional ethics.

DOCTOR STRIETMANN (Closing).—I must grant, with Doctor Kerr, that subacute bacterial endocarditis rarely results in cure. However, I have seen three such, in two of which large localized abscesses developed. One in the left thigh and another in the right scapular region. The pus was sterile in both instances. It makes me think of the possible advisability of inducing fixation abscesses by injecting turpentine, etc.

With Doctor Cooper, I realize that it is difficult to evaluate the part played by removal of a focus in angina pectoris, but I should like to add that it is equally difficult to say that, particularly when of dental origin, the focus has been definitely and completely removed. A pulp-stone is just as likely to be the result of a metastatic infection as a gall-stone, and I know that such apparently healthy teeth do at times yield a streptococcus.

As Doctor Taylor remarks, the removal of the infected tooth is but the beginning of the surgical procedure for the eradication of this focus, and it is this particular feature which is the burden of my remarks. When we are definitely certain that such a focus has been removed in its entirety, only then may we evaluate the part played and deduce with more reason the dependence of the condition at hand upon the focus removed.

ONCHOCERCOSIS IN NORTH AMERICA*

By HERBERT G. JOHNSTONE, PH.D.
AND
ALBERT E. LARSEN, M. D.
San Francisco

DISCUSSION *by John F. Kessel, Ph. D., Los Angeles; Rawson J. Pickard, M. D., San Diego.*

AN interesting disease exists in parts of Guatemala and Mexico, sharply limited to an area several hundred miles wide, extending from the slopes of the volcano Fuego, in Guatemala, north along the mountain range of the Sierra Madres, into the states of Chiapas, Oaxaca, and Guerrero in southern Mexico. This infected area has an average elevation of from two to four thousand feet.

PARASITIC NATURE OF DISEASE

The parasitic nature of the disease was first established in America by Robles in 1916. Calderón (1917) recognized that the common condition, known locally as "erisipela de la costa," was always associated with the presence of nodules located about the head and neck. These nodules were found to contain adult filariae, which were subsequently identified by Brumpt (1919) as a new species of *Onchocerca,* which he designated *Onchocerca cæcutiens.* Subsequent workers, including Fülleborn, Pacheco-Luna, Hoffman, Ochoterena, Blacklock, Blanchard and Laicret finally developed the complete clinical picture with its etiology, transmission, and treatment. Strong of Harvard, in a recent field study of the condition, made many valuable contributions while

* From the Pacific Institute of Tropical Medicine within the Hooper Foundation of the University of California.

* The list of references and additional illustrations will be given in the reprints.

bringing the disease to the attention of physicians in the United States.

Onchocerca cæcutiens Brumpt, the causative agent of American onchocercosis, belongs to the family Filariidæ, subfamily Filariinæ. In the Filariinæ are found many of the filarial worms infecting man, including such forms as *Wuchereria bancrofti* (causing elephantiasis), *Loa loa* (causing Calabar swellings), *Acanthocheilonema perstans,* and the American and African members of the genus *Onchocerca.*

O. volvulus, occurring in Africa, resembles closely *O. cæcutiens,* the American form. Brumpt described the latter species, but due to the similarity with the African form the validity of the differentiation is still in doubt. *O. cæcutiens* is given separate specific classification in that it is found at very high altitudes, localizes on the head and neck region, produces resorption of bone, and has pathogenic sequelae clearly differentiated from those produced by *O. volvulus.* The latter species occurs at much lower altitudes, is found generally on the trunk and extremities and only rarely in the head region, and although the tumors are adherent to the bone, no osseous resorption takes place.

The nodular tumors produced by *O. cæcutiens* are very small, measuring generally from 6 to 20 millimeters in diameter, although Strong states that in Guatemala he has observed tumors 2 to 3 centimeters in diameter, and in one case an extirpated tumor measured 5 centimeters in its greatest length. The fibrous tumors when removed are found to contain male and female adults (the former predominating) as well as numerous microfilariæ. The males, being much the smaller, measure from 2.5 to 3 centimeters, and the females from 30 to 44 centimeters in length (Strong).

The microfilariæ of *O. cæcutiens* (Fig. 3) do not occur normally in the blood, but are restricted solely to the lymphatics. They have the ability to escape through the capsule of the nodule and to wander through the lymphatics of the subepidermal tissue to remote parts. They are easily detected in thin sections of skin removed from infected persons and are actively motile when observed in normal saline solution. Strong has noted that, while the microfilariæ have been found in the skin in all regions of the body, they are most numerous in the areas of the head and neck. The bite of an Eusimulium fly (Fig. 2), the insect vector incriminated in onchocercosis, has a tendency to cause a mobilization of the microfilariæ from the subepidermal lymphatics in the areas of the skin adjacent to the bite. A section of skin removed from such an area previous to a bite of the fly will show perhaps one or two of the larval forms, but immediately following the bite a second contiguous section will harbor a decided increase in the number of microfilariæ.

Blacklock has shown that *Eusimulium damnosum* is the insect vector of *O. volvulus* and has described the various stages of development of the larval worm within the body of the fly. In Africa, *Eu. damnosum* has been the only fly shown to be implicated in the transmission of onchocercid microfilariæ, but in Guatemala and Mexico, Strong states that at least three species are vectors, tentatively identified as *Eu. avidum, Eu. ochraceum,* and *Eu. mooseri.* These flies are of aquatic origin and their breeding places are found widespread in swiftly running streams at high altitudes. Rocks, twigs, grasses, etc., immersed in or continuously sprayed by running water, are the favorite sites chosen by the female on which to deposit her eggs.

Strong has followed the developmental stages of *O. cæcutiens* in Eusimulium from the time of the ingestion of the microfilariæ to the passage of the infective forms through and emergence from the labium. The development in the fly is somewhat similar to that of *Wuchereria bancrofti.* A fly takes from three to five minutes to engorge itself, following which, after a short time, the microfilariæ are found in the gut. From the gut the larval forms pass to other parts of the fly, and in from twenty-four to forty-eight hours following the blood meal, are found particularly abundant in other parts of the abdomen and the thoracic muscles. In the gut the microfilariæ exhibit a greater activity than in the skin of the infected person. During the course of development in the thoracic muscles, marked changes are noted: The larvæ become much broader, decided changes in the caudal appendage are seen, and the alimentary tract shows considerable development. A marked decrease in vitality is observed and the movements have changed from a squirming, sudden type of motion to that of a slow, gliding motion.

These broader forms undergo further changes in the thoracic muscles, and when they reach the infective state measure 450 to 1140 microns in length and 16 to 25 microns in width and resume their former active movements. These active filarial forms pass toward the head to the labium of the proboscis, through which they finally pass. Strong found that of 1,658 simuliid flies caught at random, about 5 per cent were infected.

Hoffman has described the morphology of various members of the Simuliidæ occurring in Chiapas. *Simulium avidum, S. virgatum, S. pseudohæmatopotum, Eusimulium ochraceum, E. mooseri,* and *Eu. turgidum* have been reported from this region. He has found the infective larval forms in one of the above species only, viz., *Eu. mooseri.* Strong has likewise investigated the simuliid flies at Santa Emilia, in Guatemala, and found that three species of Eusimulium were capable of transmitting the microfilariæ of *O. cæcutiens.* Two other species of this same genus were not incriminated.

EPIDEMIOLOGIC IMPORTANCE

From an epidemiologic standpoint, it is of interest to consider the probable northward spread of onchocercosis along the path concomitant with the occurrence of the insect vector. It is supposed that the infection was introduced into eastern Guatemala by natives from Africa. The course of infection proceeded westerly to the mountainous regions along the Pacific, then northerly into the Mexican States of Chiapas, Oaxaca, and Guerrero. The simuliid fauna of northern Mexico is

as yet little known, but in all probability many species exist throughout the country.

The Simuliidæ are found widely distributed throughout the United States. Dyar and Shannon have described forty-seven species and two races occurring on the mainland of North America and Greenland. In California alone, these workers give a list of some eighteen species (Fig. 1). Most of the California species reported are found in the northern high Sierras. Six of the eighteen California species are members of the genus *Eusimulium,* various foreign representatives of which are the vectors of onchocercid larvæ. In considering the probable contamination of our own simuliid flies from imported cases of onchocercosis, the attendant climatic and geographic factors must be considered. The questions as to whether onchocercosis can be contracted and progress in any climate other than a tropical one, or whether our native flies are capable of serving as vectors deserve close attention.

Due to the migration of the microfilariæ, several remote effects are produced. The most common is the skin condition known as "erisipela de la costa," which may involve varying areas of the face, including the ears, nose, and lips. In the acute stage the skin becomes dry and shiny, with a greenish discoloration, such as one sees in an ecchymosis several days old. There is considerable swelling, with a nonpitting edema frequently present. Subjectively there is intense pain and itching, especially if scratched; a sensation as if insects were crawling over the face (formication) is experienced. A fever is usually present, ranging from 102 to 105 degrees, and children may develop great prostration, with convulsions and delirium. This state may exist for several days and then rapidly disappear *per se.* There may be recurrent attacks over a period of years. A chronic state is recognized in which the skin of the affected parts is thickened and furrowed, with a pallid greenish tinge, and a hard edema. There may be exacerbations of this condition at intervals of from one to two months. An eosinophilia is present, ranging from 25 to 50 per cent.

In its further migrations the microfilaria chooses the eye for a resting place. There is a large concentration of the actively motile larval forms, especially in the outer third of the corneal epithelium. For a long time the relation of the filaria to eye complications was not recognized, but when a series of cases had been observed where removal of the worm-containing nodules was followed by marked clinical improvement, their dependency was established. Final objective proof was provided when Ochoterena demonstrated the presence of the microfilaria in sections made from an excised eye of a blind man. Since then a wide variety of conditions, beginning with simple photophobia and ending with complete blindness, have been attributed to the filaria. In the acute stage, which may accompany the skin involvement, the soft tissues about the eye are swollen and closed. There is intense photophobia, blepharospasm, and periorbital headache. There may then develop, singly or in combination, a conjunctivitis, punctate keratitis, corneal leukoma, acute or chronic iritis, a pigmentation of the sclerae, progressive diminution of the visual fields, and complete blindness. All of these conditions are due to presence of the microfilariæ, which set up a foreign body reaction, scarring the parts involved. In the late stage there may be little evidence of the past attacks, with the exception that the visual field is reduced, or that complete blindness is present. The pupils may then be contracted and do not react to light or distance.

These serious eye complications are peculiar to *Onchocerca cæcutiens.* The widespread *Onchocerca volvulus of Africa,* to which it is closely related, does not seem to produce these complications, except in rare instances. This difference may find its explanation in the habits of the two native peoples. The natives of Africa wear little or no clothing, while those of Central America wear shirts, trousers, and footwear. This is undoubtedly a factor in determining the site that the simuliid fly would elect to bite. In Africa the worm-containing nodules are confined almost entirely to the pelvic girdle, while those of Central America are about the head and neck.

Fig. 1.—Distribution map of the simuliid flies in California, as reported by Dyar and Shannon (1927). Note that the majority of species occur in the northern high Sierra counties.

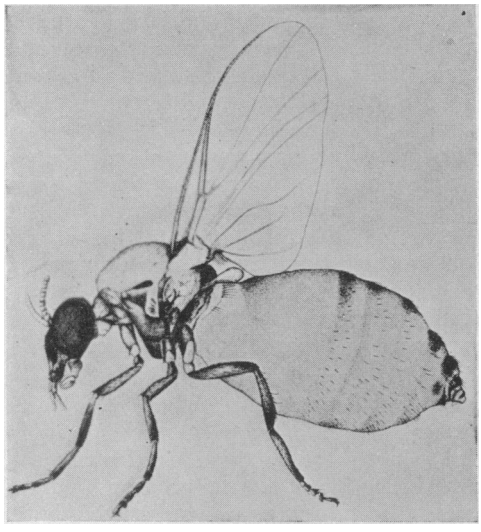

Fig. 2.*—A simuliid fly, the insect vector of *Onchocerca cæcutiens,* found widespread throughout the infected areas of Guatemala and Mexico.

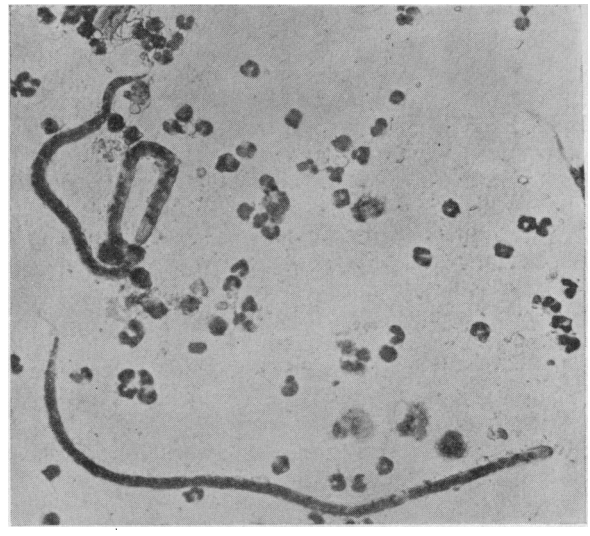

Fig. 3.—Lymph smear showing the microfilariæ of *Onchocerca cæcutiens* X320.

This difference in anatomical location may explain why two almost identical organisms produce different clinical pictures. Other filariæ have been found in the eye, but these are regarded as medical curiosities.

DIAGNOSIS

The diagnosis of *Onchocerca cæcutiens* in an infected locality is comparatively simple. The nodules with the presence or history of skin and eye complications produce an easily recognizable clinical picture. These nodules may be easily removed and on sectioning will always show the adult macroscopic worm. In itself, the skin condition could easily be confused with our erysipelas, the differential points being the peculiar greenish discoloration and the fact that skin sections will always show free microfilariæ. The eye complications are so varied that they may closely resemble many conditions present in the temperate zone. There remains the fact that long after the acute stage has passed and little evidence of irritation is present, the pupils may have been so affected that they do not react to light or distance. Taken alone, this finding may indicate syphilis, but the presence of nodules and a history of erysipeloid attacks would lead to a suggestion of the etiology.

TREATMENT

The treatment is simple. There is no known drug that will kill the wandering microfilariæ. The encysted adults are also safe from the action of any known filariacide. Consequently there remains only the removal of the source of infection, that is, surgical removal of the nodules. Very frequently this procedure is followed by a remarkable clearing of symptoms. This is true especially in the acute cases, where the relief occurs over night. But even when the disease has become chronic, this surgical procedure is of benefit. The case should not be dismissed but observed from time to time to watch for the development of nodules which may have been too small to detect at the time of the previous examinations. Frequently a residual blindness may remain, which, however, can often be helped by iridectomy.

PREVENTION

The problem of prevention is difficult. The Eusimulium fly is very active and lives in heavily wooded terrain by the side of swiftly flowing streams, and especially at the base of waterfalls. These facts present practical obstacles which are difficult or impossible to surmount.

Other measures, such as screening homes, placing mosquito netting about beds, and perhaps even wearing a daytime netting hung from the headwear are of some value. Strong has suggested the systematic removal of the worm-containing nodules and if accomplished this would render the fly noninfectious in time. However, observations over a continued period would be necessary, because minute missed nodules would continue to supply a source of infection.

IN CONCLUSION

This disease may seem a medical curiosity to physicians of the temperate zone since it has no immediate attendant public health problems, but we should become acquainted with it for the following reasons: (1) Clinical manifestations of Onchocercosis resemble many conditions of the temperate zone. (2) The Eusimulium fly is widespread in certain localities throughout the western states. (3) The disease has shown a definite tendency toward a northern migration. (4) The numerous Mexican immigrants in the United States provide an opportunity for the presence of a carrier of *Onchocerca cæcutiens.* This may lead subsequently to the contamination of our own simuliid species. If this occurs, a case of the disease is sure to make its appearance sooner or later; and, once present, it is difficult to eradicate.

Hooper Foundation, University of California.

* Figure 2, through the courtesy of Dr. Gaston Melo, Jefe del Departamento de Salubridad Publica, Mexico.

DISCUSSION

JOHN F. KESSEL, Ph. D. (University of Southern California, Los Angeles).—Though onchocercosis has been known for some sixteen years in Central America, only an occasional critical report has occurred in American journals and there are probably few physicians in California, even in the specialized field of ophthalmology, who are familiar with the condition and who would be prepared to recognize a case if the same were presented. This report should serve a twofold purpose: (1) to acquaint the profession throughout the state of California with the major characteristics of onchocercosis; and (2) to sound a warning so that our state will be on the alert to recognize the dangers of a possible advance of the disease into this region.

The fact that the filaria involved in the Mexican form of the disease is adapted for transmission to several species of Simuliidæ and that these species, in turn, are different from the insect vectors of Onchocerca in Africa, would indicate that the Simuliidæ or Buffalo gnats found in California or other parts of the United States of America might also serve as transmitting agents.

This is an excellent report on a timely subject.

❋

RAWSON J. PICKARD, M. D. (805 Watts Building, San Diego).—It is the large proportion of parasitic diseases that makes tropical medicine so interesting a field. The diagnosis can be a certain one, often the cure is as certain, and the mode of transmission of parasitic infestations, as well as the story of their discovery, is always interesting, sometimes exciting. The paper on Onchocercosis by Doctors Johnstone and Larsen fulfils these pleasant requirements.

There is also much of the unknown awaiting the patience and time of investigators in tropical medicine. Coutelan, studying the central internal body of microfilaria, found it to be a protein inclusion, an alimentary reserve, a sort of vitelline body, and reminds us that microfilaria are "in a manner hatching eggs (œufs embryonnés) in which the larval forms lacking a digestive tube are still in their first stage of development." In that Coutelan's work is based on the common and well-known microchemical staining reactions, it emphasizes the value of using the simple means of investigation at hand everywhere.

Concerning onchocercosis, Brumpt says the diagnosis of filarial itch is more easily made by allowing the vector fly to bite the affected area and then examine the gut content for microfilaria than by biopsy. Strong successfully used this method in Guatemala. The present paper should stimulate search in this state for the possibility of the existence of filarial mange in animals, which exists in Australia in cattle.

PANAMERICAN MEDICAL ASSOCIATION*

A REPORT ON FOURTH CONGRESS

By CHARLES P. MATHÉ, M. D.
San Francisco

THE fourth congress of the Panamerican Medical Association, held in Dallas, Texas, March 21-25, 1933, was a decided success. It was the first meeting of the association in an English-speaking nation, the other congresses having been held in Havana, Cuba, Panama and Mexico City.

THE DALLAS MEETING

Its successful outcome was due to the untiring work and guiding spirit of its officers, consisting of Doctors Francisco Fernández (Cuba), president; Conrad Behrens (U. S. A.), treasurer; J. E. López Silvero (Cuba), secretary; Miguel Branly (Cuba), Roberto Gutierrez (U. S. A.), Francisco de P. Miranda (Mexico), and Joseph J. Eller (U. S. A.), assistant secretaries; and the seventeen vice-presidents and the twenty-four trustees selected from the twenty-two countries making up the Western Hemisphere.

The congress was originally scheduled to take place in New Orleans, and the untimely death of Dr. Aristides Agramonte of yellow fever fame, permitted Dr. John Oliver McReynolds, past president of the Texas State Medical Association, to swing the meeting to Dallas, Texas. To him and to the Dallas sponsors and committees great credit is due for the success of the congress. Doctor McReynolds' unfaltering courage, particularly during the trying period of financial uncertainty, with all the banks of the United States and Cuba closed just two weeks before the scheduled opening of the congress, is responsible for the culmination of the most successful meeting ever held by the association. During these times of greatest depression he informed all interested in the congress by letter, radio, and wire that it would take place and that checks presented by men coming from all parts of the Western Hemisphere would be honored. In addition, the annual meeting of the Southern Clinical Society, which was to have taken place immediately after this congress, was canceled in order to afford an opportunity for the medical men of the south to attend the congress of the association. In all, about 1500 medical men from the United States and our Latin-American sister republics attended. The official languages of the association are Spanish, French, Portuguese, and English. Most of the papers were given in English, as many of our Latin-American brothers speak our language. Others gave their addresses in the beautiful Castilian language and in French.

ADDRESSES

The inaugural session took place in the spacious McFarlan Auditorium of the Southern Methodist University. A telegram of welcome from President Franklin D. Roosevelt and from the legislative bodies of the national government was read by Doctor McReynolds. Speeches were made by Doctors Francisco Fernández and López Silvero of Cuba, Francisco de P. Miranda of Mexico, Dean Lewis, Charles Mayo, Lewellys F. Barker of the United States, and many others, setting forward the purposes of the association, which are the advancement of the science and art of our noble profession, the stimulation of the spirit of broad fellowship and good will, and the social and intellectual development of the medical men of the new world. The speakers pointed out that the congress hoped to blend the best practical thoughts and progressive ideals of the century with the cultural influences of international contacts, reinforced with a world-wide knowledge of the achievements and needs of the human race.

* Report submitted by Charles P. Mathé, M. D., San Francisco.