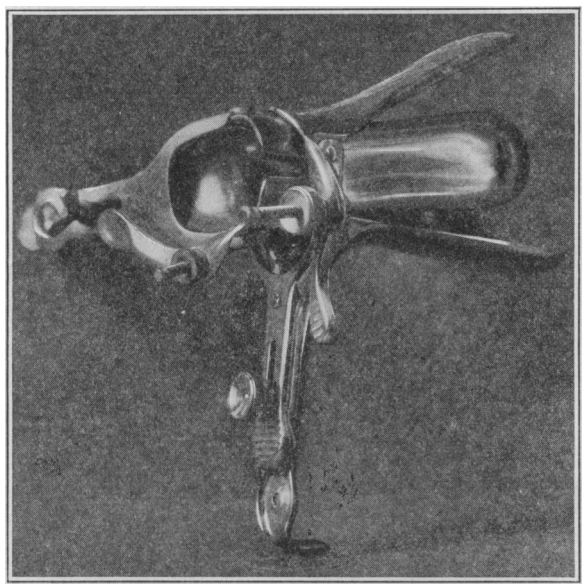

Fig. 1.—A four-bladed vaginal speculum.

its blades will open freely in a horizontal plane (Fig. 1). The protruding lateral vaginal walls can then be well retracted and a very clear view of the cervix secured.

1009 Medico-Dental Building.

REFERENCE

1. Am. J. Obst. and Gynec., 17:112, 1929.

ACTINOMYCOSIS OF PANCREAS

REPORT OF CASE

By H. H. Parsons, M. D.
San Bernardino

A SURVEY of available literature fails to disclose a report of a case of pancreatic actinomycosis, so I am submitting the following for record.

A married woman, thirty-five years of age, who had never lived in the country, was taken sick in November 1927 with what she called indigestion. These attacks were mild and ceased after a few days. On January 6, 1928, she developed somewhat similar symptoms, but they were more severe and were accompanied by vomiting, epigastric pain, and marked constipation. These symptoms continued and on January 11 the pain became excruciating, the vomiting persistent, and there was complete obstipation. At this time I, with Drs. C. N. Greusel and Ross C. Martin, was called to see the patient.

REPORT OF CASE

I found a well-nourished woman, apparently in shock, vomiting and complaining of severe epigastric pain. The pulse was 120 and the temperature 99.4 degrees. The abdomen was but slightly distended and there was only scant rigidity in the epigastrium, but there was marked tenderness all over the epigastric region, the lower limit of tenderness being well defined by a transverse line just above the umbilicus.

The white blood count was 41,200. The urine had specific gravity of 1017, was acid and contained no sugar. There was a trace of albumen, a few hyaline casts, red cells and pus cells. Acetone and diacetic acid were present in large amounts.

As the patient had had a previous section a diagnosis of intestinal obstruction was made, operation advised, accepted and carried out at once.

A midline epigastric incision was made and on opening the peritoneum clear fluid was found. No obstructive lesion could be found. The gall-bladder contained a few small stones, but the ducts were free. No stomach lesions were found, but on elevating the stomach the pancreatic area was found to be edematous. This was a mucous edema and not serous. This edema extended over the pancreas and retroperitoneally along the root of the mesentery and into the gastrohepatic omentum. This mucous substance was streaked with black.

On exposing the pancreas it was found to be of a yellow color with dirty black areas scattered through it. The pancreas was not hard and was but slightly enlarged. A diagnosis of pancreatic necrosis was made and tube drainage to the pancreas instituted, the retroperitoneum being sutured about the tube and the incision being closed up to the tube.

For about twenty-four hours she was in a very critical condition, being pulseless most of the time. However, she finally responded to stimulants and intravenous glucose solution.

For about a week the discharge consisted of the thick mucous material streaked with black, when the character of the discharge became purulent and profuse in amount. With this change in the character of the discharge there appeared in the pus small rounded masses from smaller than pin head to as large as a half grain of wheat. Some of these were yellowish, some copper colored, and others were tinged with red. Staphylococci also were present in the pus. Specimens submitted to Brem-Zeiler-Hammack were reported as actinomycosis.

On January 13, sugar appeared in the urine and on January 18 there was 4.5 per cent sugar and 3.2 per cent albumen by bulk, both of which had decreased to heavy traces by January 23. The fever was of a remittent type, ranging to 102 degrees, and the pulse remained fairly constantly at 120.

Vomiting continued at intervals and she complained of almost constant nausea. As soon as the diagnosis was cleared up treatment with intravenous sodium iodid was started and the pancreatic area irrigated daily with one per cent copper sulphate solution and later a weak aqueous solution of iodin was used. Potassium iodid was tried but invariably produced vomiting, so had to be discontinued.

On February 23, treatment with colloidal copper (Cuprase) by intramuscular injection was started, one ampoule being given every fourth to fifth day. After the fifth injection the discharge began to diminish and the actinomycotic granules disappeared, the temperature began to decline and reached normal on March 8, 1928.

About this time the vomiting became more frequent, she lost rapidly in weight, her appearance became drawn, and she complained of a metallic taste. The sinus by this time had ceased to discharge and was about closed.

On March 28 she suddenly developed convulsions and died. Autopsy was not permitted.

COMMENT

The interesting points about this case are the antecedent symptoms, the high white count, the retroperitoneal mucous edema, remittent fever, glycosuria which cleared up, the persistent vomiting, the apparent response of the infection to colloidal copper, and the terminal convulsions.

I believe that should I have occasion to use colloidal copper again I would increase the interval of treatment, and upon the slightest evidence of copper saturation would stop its use until such symptoms had cleared up. I believe that colloidal copper is a rational and effective treatment for actinomycosis.

668 E Street.