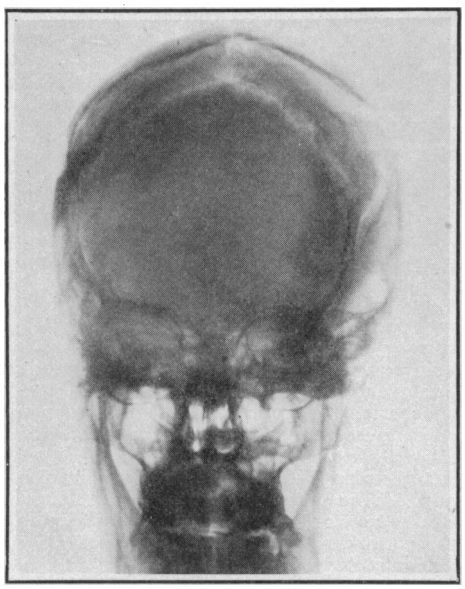

Fig. 2.—Posteroanterior View

pital it was noted that there were multiple lacerations about the scalp and face with evidence of considerable hemorrhage. There was no bleeding nor escape of cerebrospinal fluid from the ears, nose or mouth. Respiration was regular and quiet, 18 per minute; pulse regular, 80 per minute; blood pressure, 120/80. There was no motor disturbance of the face or limbs. Deep and superficial reflexes were all present and normally active. Pupils were equal, regular, and reacted to light. There was some vomiting, but not of the projectile type.

Three to four hours later some symptoms of acute intracranial pressure developed: the blood pressure showed a marked fluctuation ranging from 90 to 130 systolic and 10 to 68 diastolic, with a consequent variation of the pulse pressure; the pulse and respiration became slower, but remained regular. This condition lasted five days, after which the symptoms subsided, the blood pressure, pulse, and respiration remaining at constant levels. Temperature was subnormal upon admission and normal thereafter.

X-ray pictures taken upon admission showed (Figs. 1 and 2) a very extensive comminuted fracture involving both parietal bones. On the right side a fragment had been depressed into the cranial cavity. There was also a depression of the upper fragment of the parietal on the left side. There was a marked diastasis of the coronal suture and of the sagittal suture anteriorly. This diastasis no doubt accounted for the symptoms subsiding after the immediate effects of shock: the patient had decompressed himself.

The patient's general condition improved steadily under absolute bed rest and sedatives. At this time the question arose as to the advisability of surgical intervention, it being felt that the depressed piece of bone would irritate the cerebral cortex. However, due to the extreme shock sustained, it was deemed advisable to wait one month before removal was attempted. This was concurred in by Dr. H. Naffziger, who saw him in consultation with us. The patient improved steadily during this interval of time and operation was then performed. The fracture and overlapping bone were exposed through an inverted U-shaped skin flap. After removing the overlapping portions of bone, the dura was found to be intact but markedly thickened and congested. X-ray pictures were taken four days after the operation (Fig. 3).

Recovery was uneventful and the patient was allowed to leave the hospital on the fourteenth day after operation. The trephined area in the right parietal region was protected externally by an aluminum plate. He did not complain of any headache or dizziness and was mentally alert. He has continued to improve up to the present time, seven months after the accident, and no signs of cerebral irritation have developed. The trephined area has filled in to within a space one centimeter in diameter.

1065 Sutter Street.

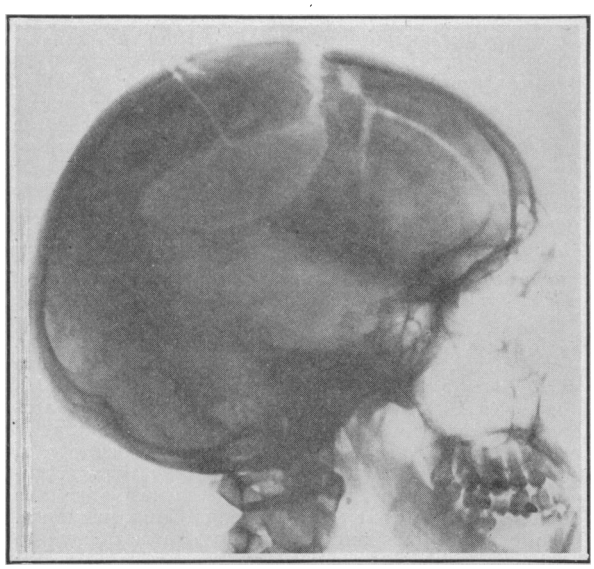

Fig. 3.—Showing a large ovoid defect in the right parietal bone where the comminuted and overlapping fragment had been removed.

SELF-RETAINING INTRA-UTERINE PESSARY

REPORT OF CASE

By Olga McNeile, M. D.
Los Angeles

After eighteen years' experience with different forms of self-retaining pessaries, it has finally been my privilege to find one that is nearly perfect.

The glass stems used in the past were satisfactory except for the danger of breaking (I have removed several broken ones). The aluminum, gold, and silver ones caused a cervical irritation

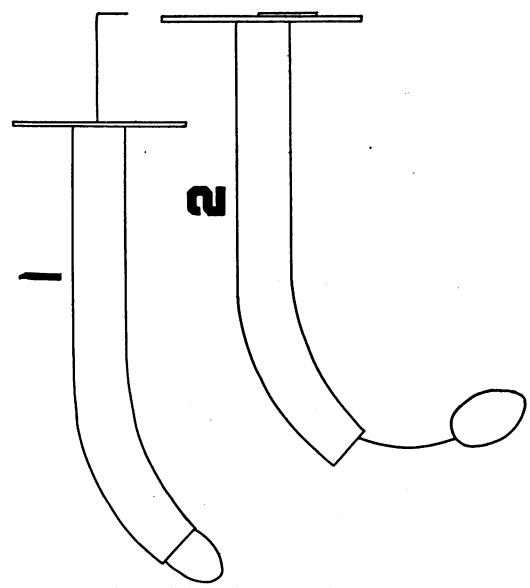

Self-retaining intra-uterine pessary

in a very short time, and had to be introduced with the use of capsule which contaminated them. All the old types were made in a limited number of sizes which often were not adapted to the individual anatomical structure.

I mentioned my problem to a friend of mine, Mr. J. J. Cantor, a designer of medical appliances, who thereupon devised a pessary which I have used during the past six months. Indications for its use were dysmenorrhea, with or without an anteflexion, and sterility. This pessary can be introduced when the patient is in the office. Slight dilatation may be necessary. The pessary can be altered to various lengths to suit individual requirements.

The pessary holds itself well in position and does not cause any irritation or odor, even after being worn for six months. After the usual dilatation under an anesthetic, the cervical muscle tissue is torn, often causing a secondary contraction. By wearing this type of pessary, from one to six months, the cervical canal becomes permanently dilated.

REPORT OF CASE

Mrs. X.—Introduced pessary after usual dilatation. She had borne two children. Operation for cervical repair followed. This repair had a contracted cervical canal so the ordinary uterine sound would not pass; and also had caused severe premenstrual dysmenorrhea and sterility. Pessary was easily removed after having been worn for six months. At no time did it cause erosion of the cervix or any leukorrhea. Six months have passed since its removal, the dysmenorrhea no longer exists, and the cervical canal is of normal diameter.

2007 Wilshire Boulevard.

SURGICAL CATASTROPHES FOLLOWING OVERLOOKED STONE

REPORT OF CASE

By STANLEY H. MENTZER, M. D.
San Francisco

D-65787, white, male, age forty-one, garage mechanic.

Family History and Past History.—Unessential.

Present Illness.—Patient had been perfectly well until one year ago when, after no previous indigestion or other suggestive signs of biliary disease, he suddenly developed an attack of severe pain in the right upper quadrant which radiated posteriorly; some nausea but no vomiting, no jaundice, no clay-colored stools. Since that time he had had characteristic gall-bladder distress with true qualitative food intolerance; flatulence and belching thirty to sixty minutes after meals. No chills or fever.

Operation (Elsewhere).—Under ether anesthesia, a relatively noninflammatory gall bladder containing two cholesterin-rich stones was found. During the cholecystectomy the gall bladder was ruptured. Some bile-oozing occurred. The abdomen was closed with a Penrose drain.

Interval History.—Patient was practically well for one year except for slight jaundice, which was intermittent. There was no severe pain, no chills or fever, until the second attack of distress one year after the first operation. Then rather suddenly the patient developed severe pain in the upper abdomen with deep jaundice, chills, fever, and clay-colored stools. A diagnosis of common duct stone was made and at operation I found a stone in an anomalous cystic duct which ran parallel to the common duct for most of its length and drained into it close to the ampulla of Vater. Signs and symptoms of acute duct obstruction were, therefore, due to the extraneous mass, *i. e.*, the stone within the cystic duct pressing on the common duct. The stone was removed and a catheter sutured into the cystic duct for drainage. The common duct was open and thoroughly explored, and no stones were found.

Postoperative Course.—Patient drained bile freely and had an uneventful convalescence until the fourteenth day, when he got up out of bed. He had been walking about the ward approximately half a day and felt reasonably well, when he suddenly fell over in a faint which, he stated later, had been induced by severe upper abdominal pain. He rapidly went into shock, and four hours later I performed an exploratory operation. Preoperative diagnosis of bile peritonitis or mesentery thrombosis was made. The abdomen, however, was filled with serosanguinous fluid, four quarts of which were removed. Small areas of fat necrosis were observed in the omentum and transverse mesocolon and the diagnosis of acute hemorrhagic pancreatitis was obvious. Literally fistfuls of pancreatic tissue were scooped from the tail and body of the pancreas. Abundant Penrose and gauze drainage was effected from the sloughing area about the pancreas through the transverse mesocolon and anterior abdominal wall.

Patient had a stormy convalescence characterized essentially by vomiting and by digestion of the abdominal wall, due to pancreatic juice. This was controlled more or less by Fuller's earth dressings and later by beef juice and hydrochloric acid dressings.

Three weeks later a secondary closure of abdominal wall had to be performed. Patient was discharged from hospital three months after the second operation. There was still slight drainage through the abdominal wall. A month later drainage had stopped and patient was practically well—as he has remained twelve months after his discharge from the hospital. There are no signs of pancreatic insufficiency.

Note.—The case is of unusual interest because of: (1) The surgical catastrophes following overlooked stone; (2) Anomalous course of cystic duct; (3) Development of acute hemorrhagic pancreatitis; and (4) Recovery from this lesion after early surgical intervention.

450 Sutter Street.

Mme. Curie Here for Second Gift of Radium.—America has been recently hostess to the greatest woman scientist the world has ever known. Mme. Marie Curie, co-discoverer of radium, has come to accept a second gift of a gram of the precious substance from her friends and admirers in this country. When the first gram was presented to her in 1921, she turned it over to the Curie Institute of the University of Paris. The second gram will be given to the Warsaw Cancer Hospital, which since 1921 has rented a gram, Mme. Curie herself paying the rental with the income of a money gift she received with the first gram of radium. Warsaw is Mme. Curie's native city, although she has worked and lived most of her life in Paris. Mme Curie and her husband, Pierre Curie, discovered radium but refused to make any personal profit from their discovery. They gave it to the public together with the methods they evolved for producing radium. These same methods are in use today in the radium industry. For years these great and generous scientists struggled with a meager income and without even an adequate laboratory. Pierre Curie, struck by a truck, died in 1906 without ever having a proper laboratory in which to use his great talents. Mme. Curie finally acquired the laboratory, planned too late for her husband to enjoy, in the Curie Institute. However, the small supply of radium in her laboratory was needed by the government during the war, and after the armistice she found herself without any of the precious substance. Then her admirers and friends in America came to the rescue with the gram of radium and the money which was meant to make living conditions easier for her. Characteristically, she used it to rent radium for the Warsaw Cancer Hospital.—*Science Service.*