procedure, reserving the suprapubic incision for cases complicated by rupture of the bladder.

Wherever there is urine beneath the skin it must be evacuated. Only a few years ago "bold" incisions through the skin and fascia were made, and this relieved the beginning cellulitis. However, after the patients were well from the effects of their extravasation, skin grafting was necessary to cover the exposed granulating areas, due to the retraction of the skin. In order to avoid this latter maneuver, gridiron incisions came into popular favor; no cuts were longer than one inch, but the cuts were only one inch part. These incisions, of course, are of no value unless a finger is slipped down into each incision and the region beneath connected by means of this blunt dissection.

I have obtained the best results with Dakin's solution, using many tubes and frequent injections. In large incisions dichloramin-T is easier to use than the Dakin's solution. After the acute condition has disappeared or the Dakin's is beginning to burn the skin, 5 per cent mercurochrome solution is substituted. Hypodermoclysis of not less than 3000 cc. of saline is used routinely immediately after operation, and this is repeated daily as long as indicated and without any fear of incommoding the circulatory system.

If following the removal of the perineal drainage tube the patient has a sudden elevation of temperature, the tube must be replaced immediately as a secondary extravasation is occurring, the fistulous tract not retaining its continuity. Incidentally, the tube cannot be replaced with the patient lying prone. He must be placed in the extreme lithotomy position used when the tube was first inserted.

During the war I saw at an evacuation hospital near Verdun a patient who had been wounded in the perineum. When a catheter was passed intra-urethrally into the bladder, it was visible through the frayed urethra at the bottom of the perineal wound. The shrapnel had done a perfect debridement (i. e., because of the great circumference of the wound, it was relatively shallow and there were no pockets). At the end of seventy-two hours, the bottom of the wound was filled with granulation tissue, so that the patient voided without any perineal leakage. As he was immediately evacuated to a railhead, I lost track of him and do not know, but I presume no fistula followed.

Urethral mucosa grows with such amazing rapidity, that grafting or approximating the cut ends is by many considered unnecessary. When a prostatectomy is done, practically the entire mucosa of the posterior urethra is removed along with the tumor. The surgeon is not interested in the preservation of the mucosa, but rather in the removal of all loose strands of mucous membrane that might eventually cause obstructions to the lumen.

Ordinarily, in cases of ruptured urethra, if bladder drainage is provided and the two ends of the cut urethra are placed as near together as possible so that a sound will readily pass to the bladder, nothing need be feared as to the ultimate result.

The drainage should be, unless otherwise indicated, by indwelling catheter with continuous suction. This will, as a rule, prevent the passage of urine around the catheter. There is necessarily a certain amount of maceration between the walls of the urethra and the catheter (which remains in position about two weeks), and this causes the stitches to slough. Five per cent mercurochrome should be injected daily into the bladder, so that if there is any leakage about the catheter it will be sterile.

Doctor Farman is to be congratulated upon the successful way in which he treated the first patient and the scientifically accurate method of treating the second.

GRANVILLE MACGOWAN, M. D. (Brack Shops Building, Los Angeles)—The treatment of rupture of the male urethra, if the results to be obtained are to be worth while, requires boldness, good anatomical knowledge of the perineum, resourcefulness, and patience. The subject is entirely too extensive to be covered in any short article or to be discussed intelligently in a few words.

It is only in large industrial centers or in general hospitals that enough material ever gets into the hands of any one man for him to reasonably and intelligently master the subject of the handling of these cases.

I have been much interested in Farman's report of his case of Mr. R, age 60, and I congratulate him upon a very excellent result obtained by his treatment. The only thing in his article which definitely calls for criticism is paragraph 6, "After-treatment," where he states: "The immediate post-operative treatment is very important. With relief of urine retention, further extravasation ceases, but there still remains the danger of spreading cellulitis. This can be partially prevented by the injection of hydrogen peroxide into the infiltrated tissues to destroy the anerobic organisms responsible for the cellulitis." This is a doctrine which is dangerous. Hydrogen peroxide does not destroy any malignant organisms, but because of the manner in which it spreads through the tissues by reason of its release of the oxygen, it tends to spread the disease and not to check it. It has been many years since I have known anyone to advocate the use of hydrogen peroxide for this purpose. Years ago, when the mistaken idea of its disinfecting and cleansing powers had great hold upon the profession, such a doctrine would have been regarded as orthodox.

ELECTRO-DESICCATION AND ELECTRO-COAGULATION AS A MEANS OF DESTROYING BENIGN AND MALIGNANT SKIN LESIONS

By ERNEST K. STRATTON *

Electro-desiccation destroys skin lesions with comparatively slight trauma to the tissues; therefore, a minimum amount of scar formation results. This, as well as its use in the treatment of lesions of the tongue and mucous membrane of the buccal cavity, is of special importance to the dermatologist.

Electro-coagulation destroys malignant lesions in a rapid and effective manner with a minimum amount of harm to the surrounding tissue, sealing the blood and lymph channels, which lessens the likelihood of metastasis and makes the operation bloodless.

DISCUSSION *by Harry E. Alderson, San Francisco; Ernest Dwight Chipman, San Francisco; J. Cameron Pickett, San Francisco; Moses Scholtz, Los Angeles; Howard Morron, San Francisco.*

ELECTRO-DESICCATION and electro-coagulation are the terms introduced by William L. Clark of Philadelphia to express the thermic effects on living tissue produced by the action of the unipolar and the bipolar high frequency currents.

This therapeutic agent was first used in surgery in this country about fifteen years ago by Clark, who claimed for it many advantages over other destructive methods. Since that time little that is really new has appeared, yet the interest in it has been unusually great. The method has not been universally adopted by dermatologists, but each year many more are becoming interested in it, and those who have mastered the technique are enthusiastic over their results, and are so recording them in the literature.

While my experience has been more or less limited, the results obtained are encouraging.

The purpose of this paper is to record these experiences with the hope of stimulating the interest of other physicians to use this therapeutic agent.

The heat effects vary in degree according to the

---

* **Ernest K. Stratton** (490 Post Street, San Francisco). M. D. George Washington University, 1916. P. D. Philadelphia College of Pharmacy, 1910. Practice limited to Dermatology and Syphilology. Hospital connections: San Francisco Polyclinic and Mary's Help Hospital. Appointments: Clinical Instructor Dermatology and Syphilology, Stanford University Medical School; Clinical Assistant in the Department of Dermatology and Syphilology, College of Physicians and Surgeons, Columbia University, 1923-1924. Captain Medical Corps (Regular Army), 1917-1922.

amperage and voltage of current employed, if we wish to cause desiccation, that is, a dehydration with consequent shrinking of the cells, we use the unipolar, which is known as the Oudin current; when we desire coagulation effects, that is, an actual coagulation of the tissue proteins into a homogenous mass we use the bipolar, which is known as the D'Arsonval current. However, heavy unipolar currents may also cause some coagulation, while mild bipolar currents may cause only desiccation.

There are many machines on the market that will deliver either type of current, the converting principle being the same in all of them. Figure 1 shows the electrical principles of the apparatus. A 110 volt, 60 cycle, unlimited alternating current passes through the primary coil of a transformer, thus inducing a current of much higher voltage in the secondary coil. The condenser and spark gap serve to break up the 60 cycle frequency into thousands, with a corresponding reduction in wave length. The current coming from such a combination is passed through the primary portion of an Oudin resonator, which may be in the form of an autotransformer which will again increase the voltage; the increase being proportional to the ratio of turns between the primary and secondary portions.

In the unipolar work, on account of there being no return circuit, the ratio must be higher so as to induce a voltage high enough to drive the current into the tissue. In the bipolar work, however, the return circuit is established by means of the indifferent electrode, hence a high voltage is not needed, and the ratio between the turns is much lower and the amperage correspondingly increased.

The greater the frequency the shorter the wave length. This point was made use of by D'Arsonval, who discovered first, that muscular contractions were intolerable with wave lengths of from 1500 to 2000 meters, while with wave lengths of less than 100 meters, as obtained with the oscillating current from an Oudin resonator, no muscular contractions were noted, but heat was produced within the tissues.

This current which now has a frequency of about 1,000,000 oscillations, with the voltage raised to about 15,000 and amperage limited to 2500 milliamperes is transmitted to the tissue to be destroyed by means of a metal point. Usually an ordinary sewing-needle is fastened in an applicator having a rubber handle, and in contradistinction to the actual cautery, which is hot and causes carbonization of the tissues with only superficial penetration, this metal point remains cold, the heat being generated within the tissue to any depth desired. The cell destruction is proportional to the strength and kind of current used. The explanation of heat development within the tissues rests on the fact that the body is a poor conductor of electricity and therefore offers resistance to it; this resistance shows up in the form of heat.

The effects of desiccation and coagulation on the tissues are different, and will be considered separately.

Desiccation will thoroughly destroy local skin lesions with a minimum amount of resulting scar formation; the heat produced is moderate in degree, but of sufficient intensity to cause complete evaporation of the water content of the cells. Figure 3 confirms the histological findings of Clark and Asnis in regard to the effects of electro-desiccation, the cells and nuclei appearing shrunken and elongated.

The comparatively slight trauma to the tissues, the more or less selective action it has on abnormal cells, or rather on cells of lower vitality than normal cells, and the mild secondary inflammation explain, from a histological point of view, the little scarring that follows this method of destruction. Its effects can be so perfectly controlled that it is possible to successfully remove a patch of chloasma without injuring the underlying tissues, or remove a basal cell epithelioma from the eyelid, for instance, without danger of producing an ectropion, or a large pigmented and verrucous nevus may be removed with good cosmetic results.

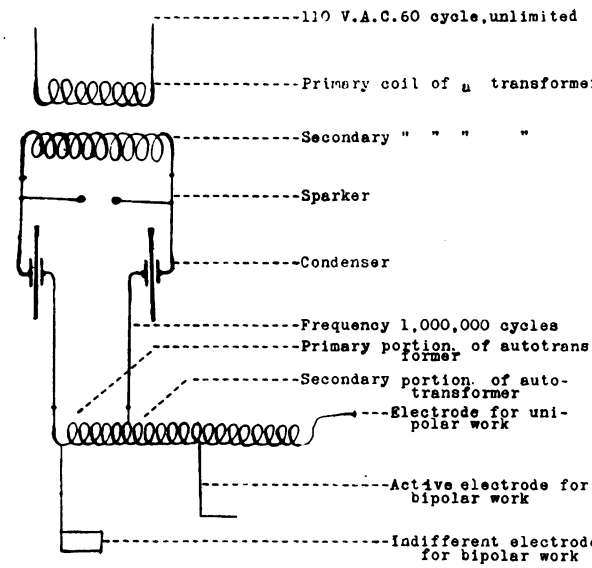

Fig. 1. Electrical principles of the desiccation and coagulation apparatus.

Very excellent results are also obtained in benign lesions of the tongue and mucous membrane of the buccal cavity; such lesions as papillomata, lupus erythematosis, glossitis rhombica mediana, can be destroyed rapidly and thoroughly. In two patients with the latter disease, whom I assisted in treating by this means, there was very little discomfort, and the end results were satisfactory.

In leucoplakia, it is the treatment par excellence. The patches are anesthetized by a topical application of a 10 per cent solution of cocain; then the application of a very fine current will completely destroy the lesion. The devitalized tissue can be separated and stripped off as a membrane with the aid of a pair of forceps. The after effects are not severe, and the patient never experiences the discomfort that usually follows radium applications in the buccal cavity.

A lesion of any size or depth can be removed with one application, but in the benign lesions that cover a large area it is better to destroy a portion at a time. The amperage, voltage, frequency, and time

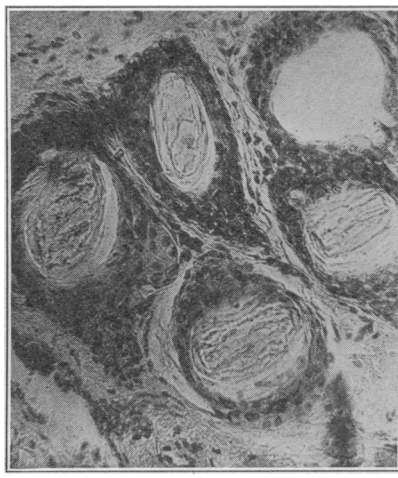

Fig. 2. Normal skin of guinea-pig, showing group of hair follicles.

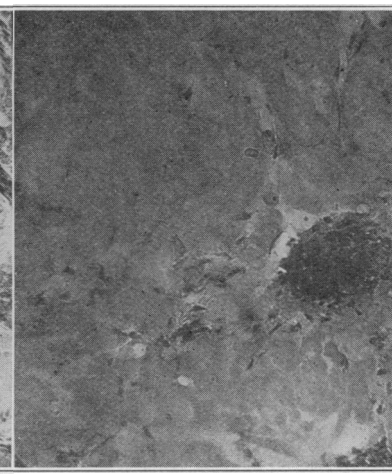

Fig. 4. Skin of guinea-pig, showing effects of coagulation; the cell outline is destroyed and the tissue has a hyalinized appearance.

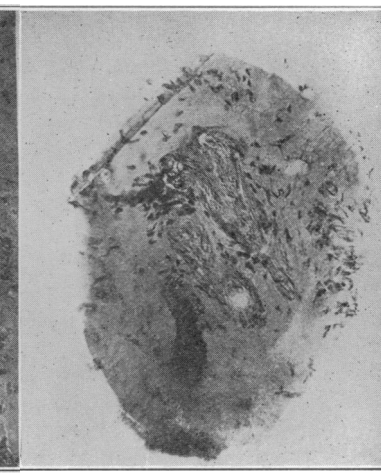

Fig. 3. Skin of guinea-pig, showing effects of desiccation; the cells and nuclei of the epithelium lining the hair follicles are shriveled and elongated.

of exposure must vary according to the depth and density of the tissue treated. This can be gauged only by experience.

When superficial dehydration is desired the metal point is not brought in close contact with the tissue, but an air space varying from 2 mm. to 2 cm. is interposed between them. The current is projected to the tissue in the form of sparks which follow one another with such rapidity that it appears as a luminous glow. A small growth may thus be desiccated through a sheet of white paper without charring or discoloring it.

A dry crust forms at once after the application, and the time required for separation depends on the character of the tissue. Desiccated mucous membrane tissue soon becomes macerated by the secretions and may separate in a few hours, but on the skin surface it takes a longer time. When the skin is soft and vascular there is a more rapid separation than where it is hard and with poor blood supply; thus a soft mole will slough more readily than a callus. Regeneration of the skin or scar tissue often takes place underneath the crust, and in benign lesions where a good cosmetic result is of paramount importance I have found that it is a better procedure to desiccate superficially and not remove the crust mechanically, but allow it to slough away naturally, repeating the treatment at a later date if all of the lesion has not been removed. However, in treating small rodent ulcers, nodules of lupus vulgaris, or a patch of lupus erythematosis where it is more important to completely remove the entire lesion at one time, a curette is used in conjunction with the desiccation, mechanically removing the tissue after it has been destroyed. The base of the lesion is then sealed by superficial desiccation.

Other skin conditions in which this method is applicable, the degree of success depending on the experience and skill of the operator, are plantar warts, xanthoma palpebrarum, keloids, rhinophyma, and tattoo marks.

Overtreatment is the mistake most of us make at the beginning and must be continually guarded against, as destruction goes beyond its apparent limits.

Coagulation, on the other hand, causes a more penetrating and more intense heat than that of desiccation, so that, in addition to dehydrating the tissue, it causes coagulation of the cell protoplasm as well; histologically, as Figure 4 shows, there is a complete loss of cell outline, thrombosis of the blood-vessels, and a hyalinized appearance of the tissue.

An indifferent electrode is necessary in this method, and a moistened asbestos pad must be placed in close contact with the patient's skin, the active electrode being of the same type as that used in desiccation, but both the active and indifferent electrodes are connected to either side of the winding. Since the effect of the high frequency current is entirely thermic, it does not matter to which side the active electrode is connected. A milliampere meter is attached in the circuit and the strength of current used varies from 200 to 2000 milliamperes, depending on the size of the growth to be treated.

This form of therapy is especially indicated in the localized basal and squamous cell epitheliomas of the skin. Its advantages are, that large areas of abnormal tissue can be destroyed rapidly and effectively and with a minimum amount of harm to the surrounding tissue. And in case of recurrence there is no contra-indication to repeating the treatment in a more radical manner. Whereas, in recurrences following massive doses of roentgen ray or radium the basophilic degeneration of the surrounding tissue has resulted in atrophy and further radiations are contra-indicated. The blood and lymph channels are sealed, making the operation bloodless and thereby lessening the likelihood of metastasis.

Coagulation is perhaps the best means we have for removing the highly malignant melanocarcinomas of the skin. I had an opportunity of assisting in thus destroying these cancers in three patients in whom this method of treatment was used alone. None of the patients presented palpable glands, and in two no recurrence nor any detectable metastasis occurred during my observation of one and one-half

years. The other patient, however, while presenting no recurrence at the site of the original lesion, did present constantly recurring pinhead-sized melanotic areas near the site of the original lesion, which were destroyed by desiccation as rapidly as they appeared.

The technique used in the removal of these tumors is applicable to all types of malignant skin lesions, and is as follows: The area is made anesthetic with a 1 or 2 per cent solution of novocain by injecting the skin surrounding the tumor at a distance of at least two inches from its outer margin, care being taken not to enter the needle near the tumor mass. The tissue corresponding to the injected area, as well as the tissue beneath the tumor, is then coagulated so as to cut off the lymph and blood drainage from the part. If desired, tissue can now be removed for microscopical study with safety. The entire tumor is then thoroughly coagulated and removed as a mass of dead débris.

Where small epitheliomas of the mucous membranes such as the tongue and lip are treated before metastasis has occurred, the results are as good as those obtained in localized skin cancers. However, we cannot be sure that the adjacent glands are not involved, even though they may not be palpable, and for that reason the gland areas should receive prophylactic exposures with radium or x-ray.

In patients with far advanced epithelioma of the tongue, lip or skin, where vital structures are involved, and gland metastasis has occurred, surgeons are reporting excellent palliative results from using the coagulation method to destroy the local lesion, making a preliminary ligation of the blood supply of the part, and treating the glands with imbedded radium needles.

I wish to thank Dr. Frank Blaisdell of the Department of Surgical Pathology, Stanford University, for photographing the microscopical sections.

DISCUSSION

HARRY E. ALDERSON, M. D. (490 Post Street, San Francisco)—The section owes its gratitude to Stratton for so ably presenting this subject. Electro-desiccation and electro-coagulation have been made much easier of application by improvements in apparatus, but the cost of their art is still rather high. However, the method has proved its great value, excelling in some of its results the use of radium or x-ray.

Some months ago Stratton very successfully treated a patient for me by electro-coagulation. It was a case of basal cell epithelioma recurring at the border of a scar on the face, due to previous unsuccessful radium treatments. Recently the patient reported for observation, showing a perfectly inconspicuous scar and not the slightest suggestion of a recurrence.

My first experience with diathermy was in Berlin (1912), when I saw a patch of lupus vulgaris on the nose effectively and painlessly destroyed. It is surprising that the method is not more generally employed, for time has demonstrated the permanency of its good results in destroying malignancy, pigmented naevi, leukoplakia, and numerous more or less disfiguring benign lesions of skin and mucous membrane. When skillfully applied the cosmetic results are most satisfactory, and this is of prime importance to the dermatologist.

ERNEST DWIGHT CHIPMAN, M. D. (350 Post Street, San Francisco)—It is certainly gratifying that the discussion of a relatively new method of treatment has been handled so conservatively. There is no question that there exist great opportunities for the application of electro-coagulation and electro-desiccation. As time passes, doubtless the indications will become more clearly defined in the minds of dermatologists. Even today there is ample room for differences of opinion as to the relative merits of such agents as carbon dioxide snow the galvano cautery, and the electric needle. Various considerations such as location, the size and the type of the growth, influence us in our choice of the agent to be employed. More time must elapse before the exact status of the newer method can be estimated. In the meantime Stratton has given us a valuable summary which is free from any exaggerated claims and which will not give the profession at large the idea of a wonderful cure-all.

J. CAMERON PICKETT, M. D. (291 Geary Street, San Francisco)—Doctor Stratton's paper on electro-desiccation was of great interest to me, for the reason that I have heard of very little discussion on this method of operation since it was first brought out by Clark about fifteen years ago. At that time I copied an apparatus used by him, and I have used it in my office ever since; this has been very unsatisfactory, as the high current cracks the leaded glass plates very frequently. I was glad to note that Doctor Stratton has found a more suitable apparatus for generating the cold spark.

I have used the electro-desiccation almost exclusively in the removing of warts, keratosis, and beginning squamous cell epithelioma. The desiccating current has a special selectivity to pathological tissue and makes a line of separation from the normal tissue, leaving the pathological tissue desiccated and easily removed. Then, if necessary, radium and x-ray can be used in more advanced forms of epithelioma. This current coagulates the blood and destroys the small capillaries so that the operation is almost bloodless. In a few seconds it will destroy a small capillary nevus on the face, and if properly used will leave no scar.

MOSES SCHOLTZ, M. D. (Brockman Building, Los Angeles)—Stratton has brought to our attention a subject of great clinical importance. Dermatology in general has benefited from electrotherapeutics possibly more than from any other branch of clinical medicine; and diathermy bids fair to prove one of the most promising and efficient electrotherapeutic agencies in dermatologic armamentarium.

I have no personal experience with electro-coagulation, but I do use extensively desiccation with the Oudin current, so-called fulguration. This seemingly technically simple and elementary procedure, in my experience, has proven most useful and covers a surprisingly large field of clinical application. Its clinical advantages are many: First, the very simplicity of technic, so easy that it requires no preliminary experience or training. Second, the rapidity of administration and its instantaneous action to any desired degree. Third, the perfect safety from any injurious effects and complications, if applied with the most ordinary intelligence and care. Fourth, relative painlessness, allowing its use even on sensitive individuals without a local anesthetic. Fifth, its inherent aseptic quality because of the production of a dry scab of heat-coagulated tissue, which prevents the possibility of pyogenic infection and requires no surgical after-care. And last but not least the excellent cosmetic results, as its penetration can be easily controlled to any desired depth, and in the overwhelming majority of cases it leaves no scars whatsoever. Lesions that can be treated by desiccation are many. Here belong all kinds of small benign tumors and formations—warts and papillomata, particularly multiple warts in the bearded region in men, small vascular and pigmented nevi, sebaceous adenomata, seborrhoic warts, senile keratoses, and even superficial incipient epitheliomata.

I believe that the use of diathermy will increase steadily, will grow in importance and clinical value, as dermatologists will familiarize themselves with its technic and clinical indications.

HOWARD MORROW, M. D. (384 Post Street, San Francisco)—Electrothermic destruction is a very useful addition to our therapeutic armamentarium in dermatology, particularly in the treatment of benign and malignant growths of the skin and mucous membrane. As is the case with any single method, electrothermic destruction

is not a cure-all, but may often be used to advantage in conjunction with radium, x-ray, surgery, or the curette. In addition to the conditions in which Stratton has indicated its usefulness, I would like to point out its value in the treatment of the radiodermatoses, especially in x-ray keratoses and epitheliomata. These often clear nicely under radium therapy, but the danger of accentuating rather than improving the condition is undoubtedly present, and we have discontinued radium treatment for them. Electro-desiccation or electro-coagulation removes these excrescences thoroughly, leaving a soft, vascular scar in place of the hard, avascular one which excessive radiotherapy causes. The area of destruction for an extensive lesion of this type must often be quite wide and deep, and the resulting ulcer may be painful and slow to heal, but the good result is our justification. It is notable that in extensive growths which are painful, especially those of the mouth, electrothermic destruction, though extensive, frequently relieves the pain at once.

ANOMALIES, DISEASES, AND INJURIES OF THE SPINE

By JAMES P. KERBY *

THE large number of variations and anomalies of development of the spinal column makes it difficult in many instances to differentiate the pathological from the anomalous; thus a knowledge of the anomalies and variations in development of the vertebrae is essential. Diagnostic difficulties are increased by certain other factors which, although being departures from normal, can scarcely be classed as pathological. Under this latter class may be mentioned variations associated with age, occupation, and posture.

In any study of the abnormal, we must have a full understanding of normal vertebrae. There may be some little difference in established standards, but with the exception of the fifth lumbar, and possibly the twelfth dorsal and first lumbar, a standard can be evolved, though it may have to be modified in the light of subsequent experience.

A typical vertebra develops from at least three chief primary centers: one for the centrum or body (some authors give two for the body, which fuse into one), the other two for the pedicles, posterolateral portion of the body, arches, and processes; and five secondary centers from which develop the tip of the spinous process, the transverse processes and a thin plate for the upper and lower surfaces of the bodies.

Variations in numbers include instances of 8 cervical, 12 dorsal and 4 lumbar; 6 cervical, 12 dorsal and 6 lumbar. Variation in the number of dorsal vertebrae is least frequently seen. To determine the exact number of vertebrae it is necessary to radiograph the entire spine. Despite the variation in the distribution of vertebrae in the different regions, the total number of presacral vertebrae is nearly always twenty-four.

Variation in structure is shown in failure of the posterior arch to fuse—spina bifida. This is most likely to occur in the seventh cervical and first dorsal or fourth and fifth lumbar. Faulty structure in the fifth lumbar vertebra is seldom of clinical significance, and is probably an incomplete fusion rather than a failure to fuse. Rudimentary spina bifida is frequently accompanied by an anomalous cervical rib or sacralization of transverse process of the fifth lumbar vertebra. In some persons the laminae may fail to fuse; the spinous process forms from one lamina; and an anomaly, simulating an apparent fracture, is observed. Anomalous formation of the spinous process of the sixth and seventh cervical vertebrae, producing an appearance suggestive of a fracture of the tip of the process, has been reported, but so far as I have been able to determine no report of an anomalous formation above the sixth has been noted. Normally the spinous processes of the third, fourth, and fifth are short and bifid; that of the sixth is longer and usually single; that of the seventh is longer, heavier, and single. The spinous processes of the upper dorsal are very much like that of the seventh cervical but a trifle longer and heavier and point lower. Those of the lower dorsal are longer and narrower and point even more toward the sacrum. The spinous processes of the lumbar vertebrae are shorter and point more nearly horizontally. The spinous process of the fifth lumbar is much shorter than those of its fellows and is frequently only rudimentary. Occasionally the tip of the spinous process seems to be connected with the rest of the process by cartilage. Long transverse processes on the seventh cervical vertebra may simulate a cervical rib. The transverse processes of the third and fifth lumbar vertebrae are longer than the others. Those of the fourth are shorter and lighter. One of the commoner anomalies is the change known as sacralization of the fifth lumbar vertebra —an anatomical variation in which the transverse process of the fifth lumbar vertebra attempts to take on the character of the first piece of the sacrum. Instead of being a perfectly straight process, it is expanded and bulbous, extending down to and touching the top of the sacrum and sometimes the posterior portion of the ilium, occasionally forming a false joint; oftener unilateral. An analogous condition, though less likely to produce symptoms, is noted in the top of the sacrum, which sometimes assumes the contour of the last lumbar vertebra, and develops a piece at its upper border simulating a free transverse process.

Occasionally a congenital fusion of bodies is seen. There may be an arrest in development, causing the bodies to be only one-half the usual height. These last two conditions are seen almost invariably in the lumbar vertebrae. Occasionally a rudimentary supernumerary vertebra, nearly always wedge-shaped, is observed. Occasionally the first lumbar vertebra has transverse processes so long as to simu-

---

* **James P. Kerby** (325 Boston Building, Salt Lake City). M. D. George Washington University, 1910. Graduate Study: Central Dispensary and Emergency Hospital, Washington, D. C., 1911-12; Children's Hospital, Washington, 1913; Chicago P. G. Medical School, 1916; School of Military Roentgenology, Johns Hopkins Hospital, 1917-18; New York P. G. Medical School, 1920. Previous Honors: U. S. Reclamation Service, Medical Dept., 1913-15; Medical Dept., U. S. Army, 1917-19. Present Hospital Connections: Roentgenologist to Holy Cross Hospital; St. Mark's Hospital; Salt Lake County Hospital; L. D. S. Children's Hospital; U. S. V. B. Regional Office. Present Scientific Organizations: Salt Lake County Medical Society; Utah State Medical Association; A. M. A.; American Roentgen Ray Society. Present Appointments: Major, M. O. R. C. Practice limited to X-Ray Diagnosis and Treatment since 1918. Publications: "Deep X-Ray Therapy," California and Western Medicine, May, 1924; "The Roentgenologist as a Staff Consultant," Hospital Progress, January, 1926.