Diagnosis and Treatment of Arteriovenous Aneurysm in a Naval Hospital

G. ARNOLD STEVENS,† M.D., *Beverly Hills*

ABNORMAL communications between arteries and veins resulting from combat injury constitute a relatively infrequent but important problem in a Naval Hospital. The vessels of the extremities are the most frequent sites of traumatic arteriovenous aneurysm, although the large vessels of the neck, the sub-clavian region, and the aorta and vena cava may be involved. The viability of the affected limb and, at times, the life of the patient, depend on correct diagnosis and proper treatment of the lesion.

DIAGNOSIS

The diagnosis is not difficult and is contingent upon an adequate appraisal of local and systemic symptoms and findings.

Local Symptoms and Findings are definite and easy to elicit. There is a scar at the site of injury. Within a few months or less, compensatory enlargement of the involved limb is apparent. There is increased temperature of the involved area. The veins of the involved extremities become dilated. A bruit may be heard at the site of the arteriovenous communication. There is a pulsating expansile mass at the site of the fistula, and a thrill may be palpated. Pressure over the site of the fistula causes the thrill and bruit to disappear and results in a slowing of the pulse rate. The tributary veins to the fistula show a higher oxygen content than in other veins and conversely the regional arterial blood has a diminished oxygen content. Enlarged communications, pigmentation, ulceration, hemorrhage, and even gangrene of the extremity distal to the fistula may occur. Pain is an inconstant symptom. It is merely the result of pressure on nerves by larger fistulas.

Systemic Manifestations, although less obvious, are significant. Fall in blood pressure is an early effect. This results from an immediate decrease in the cardiac output, of peripheral capillary resistance and of the total volume of circulating blood. These early effects are identical to those resulting from any massive hemorrhage. Subsequently, compensatory reactions are evident. There is an increased rate of cardiac contractions with a resultant increase in the pulse rate, and increased filling of the right heart, and, therefore, increased output. The total blood volume is increased. The amount of the increase obviously is proportionate to the size of the arteriovenous fistula, as it is a compensatory phenomenon. Other factors influencing the cardiovascular dilatation are the duration of the fistula and its location in the arterial tree. The more proximal the fistula is to the heart, the greater the dilatation. Collateral circulation is stimulated and increases with time.

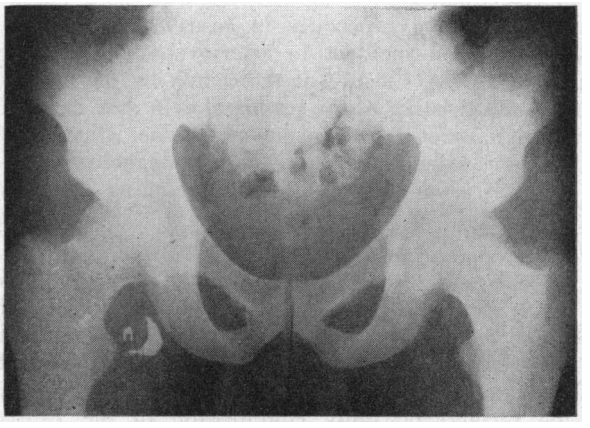

Figure 1.—Fragments of shrapnel causing femoral arteriovenous fistula.

SURGICAL MANAGEMENT

The immediate treatment of the initial wound and site is within the province of the surgeon in the field of combat. The treatment is essentially that of hemorrhage, infection, and gangrene. The responsibility of the surgeon in the Naval Hospital resolves itself to the definitive care of the arteriovenous aneurysm. This report is concerned with this phase of the treatment.

Contrary to our previous conception, experience has shown that these cases may be operated upon safely within one to three months after the initial injury. In patients of the age group involved in the military service, adequate collateral circulation with the aid of compression will usually develop within this time. We have observed cases in which compression could not be tolerated for more than three minutes without distress in the involved extremity. These cases have, without exception, been able to tolerate 30 minutes' compression, twice daily, at the end of 30 days without pain. We have had no untoward experience following surgery when this routine has been followed. It is, of course, necessary to delay operation until edema, infection and local hematoma have subsided.

A number of operative procedures have been carried out in the treatment of arteriovenous fistula. Closure of the fistula with restoration of the artery and vein carries considerable risk and is only rarely possible. Preservation of the artery and vein with repair of the fistula in the artery wall sacrificing the vein, is too frequently attended by embolism and arterial aneurysm. Ligation of

---

Note: The opinions and views set forth in this article are those of the writer and are not to be considered as reflecting the policy of the Navy Department.

† Associate Clinical Professor of Surgery, College of Medical Evangelists; Consultant in Surgery, Veterans' Hospital, Los Angeles (Sawtelle).

the communication of the canal is rarely possible. Ligation of the artery and vein proximal to the fistula is a compromise and not a cure. Ligation of the proximal and distal artery is followed by a high percentage of recurrences as collaterals reestablish the communication. Ligation of the proximal artery alone is contraindicated because of the high rate of gangrene and ischemia. Ligation of the proximal vein alone may be used as a palliative life-saving procedure in cases of cardiac decompensation incident to arteriovenous fistula. It is not a cure. Closure of the fistula by triple ligation and twisting of the proximal vein may be used in high carotid arteriovenous fistulae. Quadruple ligation without excision and endoaneurysmorrhaphy is usually successful if all incoming branches are ligated.

The operation of choice, we believe, is quadruple ligation with excision of the arteriovenous fistula. If the artery and vein proximal and distal to the fistula are exposed and fixed with unbilical tapes before resection of the aneurysm is carried out, danger of serious hemorrhage is precluded. We recommend daily compression of the fistula beginning with three minutes and working up to 30 minutes twice daily. This can usually be accomplished without distress within 30 days. We realize that this procedure is possibly unnecessary in young individuals with adequate collateral circulation. However, the cases in which we have followed this procedure have not required sympathectomy to insure the viability of the limb. We therefore consider it a wise precaution. Chart I reports six consecutive cases treated by this method with entirely satisfactory results. Figures 1, 2, 3, 4 and 5 are taken from this series of cases.

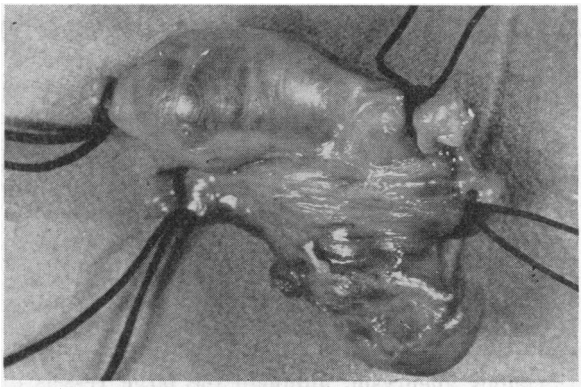

Figure 3.—Resected femoral arteriovenous fistula with false aneurysms.

PHYSIOLOGIC EFFECTS FOLLOWING RESECTION OF ARTERIOVENOUS FISTULA

The immediate effects of obliteration of the fistula are: a transient rise in general blood pressure followed almost immediately by a fall to a lower level, a marked immediate slowing of the pulse rate, a decrease in venous pressure proximal to the fistula, and a marked decrease in cardiac output. The remote and permanent accomplishments are: gradual readjustment in the general blood pressure with decreased pulse pressure, a decrease in the total blood volume, a recovery to a normal pulse rate, and subsidence of dilatation of the heart and of the proximal artery and vein. In other words, the cause of the manifestations of over compensation, namely, the arteriovenous aneurysm has been eliminated.

CHART I

Case	Sex	Age	Location of Fistula	Operation	Result
1	Male	21	Left posterior tibial	Quadruple ligation and resection	Good
2	"	32	Left popliteal	"	"
3	"	20	Right femoral	"	"
4	"	24	Right femoral	"	"
5	"	23	Right femoral	"	"
6	"	19	Left brachial	"	"

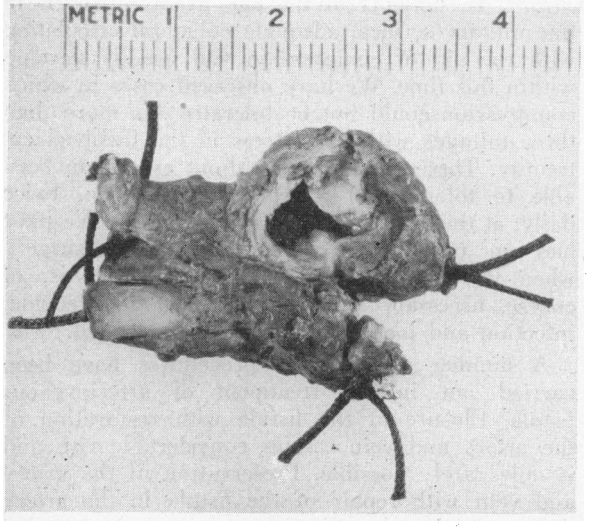

Figure 2.—Resected, arteriovenous fistula of femoral artery and vein with false aneurysm.

CONCLUSIONS

1. Six cases of traumatic arteriovenous aneurysm treated by quadruple ligation and resection with good results are reported.

2. Sympathectomy was not necessary in cases in which the fistula was compressed daily for 30 days before surgery to give added stimulus to collateral circulation. This procedure seems to be a well-advised precaution.

3. Resection of the fistula should be carried out three months or less after the initial injury. This minimizes such untoward compensatory manifestations as marked cardiac enlargement and deforming hypertrophy of the affected extremity.

120 South Lasky Drive, Beverly Hills, California.

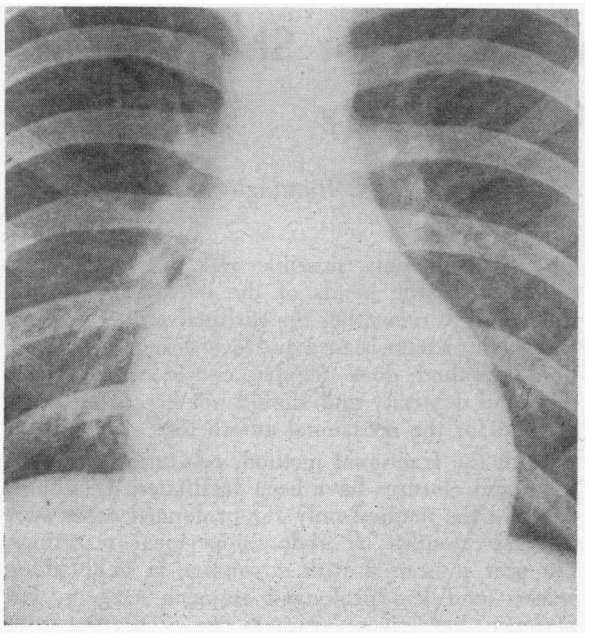

Figure 4.—Cardiac enlargement incident to femoral arteriovenous fistula.

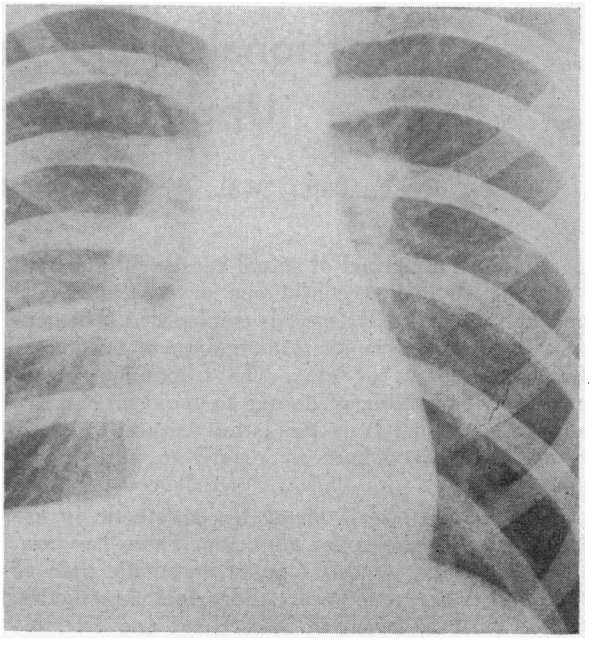

Figure 5.—Subsidence of cardiac enlargement following resection of arteriovenous fistula—same case as in figure 4.

76th Annual Session
California Medical Association
Los Angeles
April 30—May 3, 1947