EMBRYOLOGY AND PATHOLOGY OF THE INTESTINAL TRACT: PRESENTATION OF 40 CASES OF MALROTATION*

WILLIAM H. SNYDER, JR., M.D. AND LAWRENCE CHAFFIN, M.D.

LOS ANGELES, CALIFORNIA

FROM THE SURGICAL SERVICE OF THE LOS ANGELES CHILDRENS HOSPITAL AND THE UNIVERSITY OF SOUTHERN CALIFORNIA SCHOOL OF MEDICINE

AN EFFORT TO produce an animated film of the development and rotation of the intestine in the embryo, from four weeks to 12 weeks, required knowing the exact position of the various portions of the alimentary canal in the process of rotation. Some 2,000 pictures had to be drawn to show the minute changes in position as they occurred. This led to the dissection of some 50 human embryos and to an intensive review of the basic works of His,[12] Mall,[20] Frazer and Robbins,[5] Huntington,[13] Pernkopf,[24] and others.[11, 14, 15, 22, 29, 31] This resulted in the investigations and conclusions that follow.

Frazer and Robbins considered rotation to be the process by which a straight and midline tube is changed into one in which the distal part is rotated around the proximal portion in a direction from left to right. They specifically deny that the duodenal curve has anything directly to do with rotation. Dott[4] and subsequent writers[7] have stated that the right colon and cecum revolve in a counter-clockwise direction through an arc of 270° about the superior mesenteric artery. The emphasis is laid, in both these concepts of rotation, on the movement of the distal bowel. It is evident, in studying the entire intestinal tract, that the duodenum and jejunum begin in the midline, anterior and superior to the superior mesenteric artery and finally, in the adult, come to lie to the left of the artery. It seems reasonable, therefore, to include this portion of the intestine in a description of rotation. The following diagrams and discussion make this point clear.

The movement of the duodenojejunum from its position on the right of the artery, at the beginning of the second stage, and its rotation to a position beneath the artery and, finally, to the left of the artery, has usually been considered to take place at the time of the return of the intestines from the cord into the abdomen, although Mall[20] and others[1, 15, 24] have recorded a movement of the proximal portion of the jejunum at an earlier phase. The timing of this movement in the developing embryo may have more significance than might first appear, as the early failure of this segment to rotate may predict defects in the process which later become manifest. The biological urge of rotation is not present in some of the primitive vertebrates,[13] so that the basis of this anomaly might be considered as an atavistic tendency.

From a clinical standpoint, Ladd[16] in 1932 emphasized the importance of completely freeing the duodenum in the management of malrotation, in order to relieve obstruction from peritoneal bands. It now seems important also to free the upper part of the jejunum to aid in stabilizing the mesentery and preventing recurrent volvulus.

---

* Presented before the American Surgical Association, Cleveland, Ohio, April 29, 1954. Presented as a film.

Especial appreciation is extended to Doctor J. N. Nichols and other members of the Staff of the Los Angeles Childrens Hospital for use of their cases.

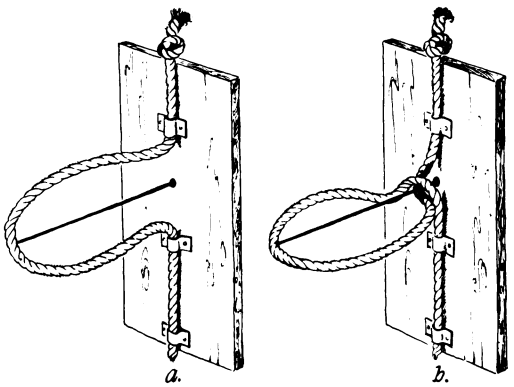

FIG. 1. This demonstration had, perhaps, better be studied after a review of Figures 2 to 10. It consists of a loop of rope attached at both ends to a board, with a wire extending at right angles from the board at the base of the loop. In *a*, the top limb of the loop corresponds to the duodenojejunum, the wire to the superior mesenteric artery and the bottom limb to the cecum and right colon. In *b*, the loop has been grasped with the hand and rotated through an arc of 270°, or three-fourths of a complete turn about the wire as the axis in a counterclockwise direction. Thus, in *b*, the top limb has become the bottom one and the bottom one the top. If one follows the movement of the two limbs about the wire, he will visualize the process of rotation of the intestine in the embryo.

The account of rotation here presented lends embryological support to this contention. The symptomatology, operative findings, and the clinical course of 40 new cases of this condition, from the files of the Los Angeles Childrens Hospital, tend to emphasize the importance of this phase of the process of rotation and its correction.

An understanding of rotation can be grasped, roughly, by attaching the ends of a loop of rope, as indicated in Figure 1. Between these two ends bring out a length of red wire and attach it to the end of the loop. Then, twist the loop through 270°, or three-fourths of a turn, in a counterclockwise direction. Both portions of the loop will pass in the same direction about the wire, through an arc of 270°. The twist will come at about the midportion of the wire, but it can be pushed closer to the base of the wire as indicated in B, of Figure 1. If the upper limb is considered as representing the duodenojejunum, and the lower limb the cecum and proximal colon, then the process which goes on in the developing embryo will be duplicated. In the embryo, the twist in the duodenojejunal loop takes place about the base of the artery (wire) and the cecocolic twist a little further out, but the motion will be the same as indicated in the demonstration.

ROTATION OF DUODENOJEJUNAL LOOP

In the 5 mm. embryo (Fig. 2), at about the fourth week of embryonic life, the intestinal tract is an almost straight tube. The duodenojejunal loop lies in the midline, superior or above the superior mesenteric artery. If an imaginary watch or dial,[2, 9] facing up, is placed on the posterior wall of the embryo, and the artery brought out through the center of the watch, then the duodenojejunal loop will lie in the starting, or 0° position.

In the 10 mm. embryo (Fig. 3), or about the fifth week, the duodenojejunal loop has been pressed down, or inferiorly and to the right, by the developing liver and left umbilical vein (Frazer and Robbins). Thus, this portion of the bowel has rotated through a 90° arc to the right of the artery. The loop of intestine including the ileum and cecum, are extending out into the umbilical cord. The yolk stalk drops off at this phase.

By the 25 mm. stage (Fig. 4), or perhaps a little later, the duodenojejunal loop has passed beneath or inferior to the artery. This accounts for a rotation of another 90°, or a total thus far of 180°. The question of the exact time in embryonic life when this phase is completed is open to some doubt. Frazer and Robbins considered it to take place at the time of the return of the intestine from the cord to the abdomen, or at the beginning of the second stage. However, Mall states "after the intestine is within the cord—as the small intestine is folded into coils—(it) is rolled under the superior mesenteric artery." This is clear in his reconstruction of a 28 mm. embryo (Fig. 10). It is also evident in Pern-

FIG. 2.

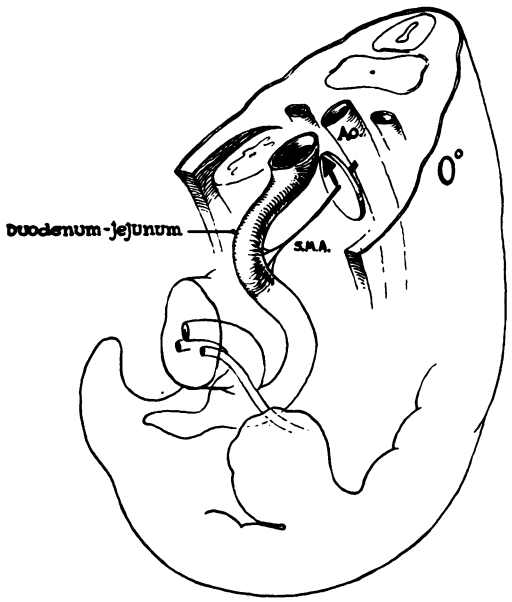

FIG. 3.

FIG. 4.

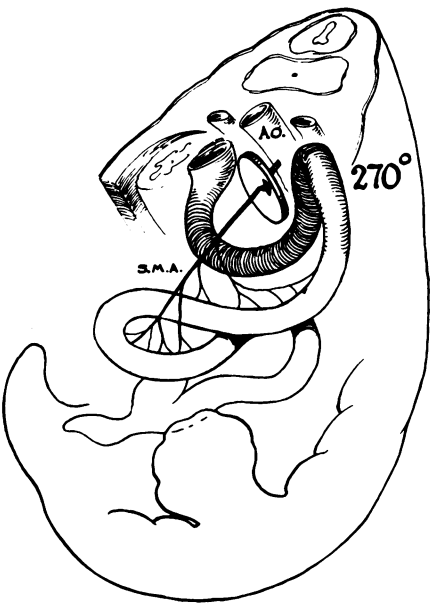

FIG. 5.

FIG. 2. Schematic ventrolateral view of 5 mm. embryo. The intestinal tract is forming a slight curve forward. SMA, superior mesenteric artery, is passing at right angles from the aorta to the curve of the intestine. A disc has been drawn about the superior mesenteric artery at its base; an arrow points superiorly to the starting position, or 0° rotation, of the duodenojejunal loop. Rotation proceeds about the artery as an axis.

FIG. 3. Schematic ventrolateral view of 10 mm. embryo. The duodenojejunal loop has passed from a position superior to the superior mesenteric artery to the right of the artery and thus has rotated through an arc of 90°, from its starting position, as indicated by the arrow on the dial. This is considered the first stage of rotation.

See facing page for legends for Figures 4 and 5.

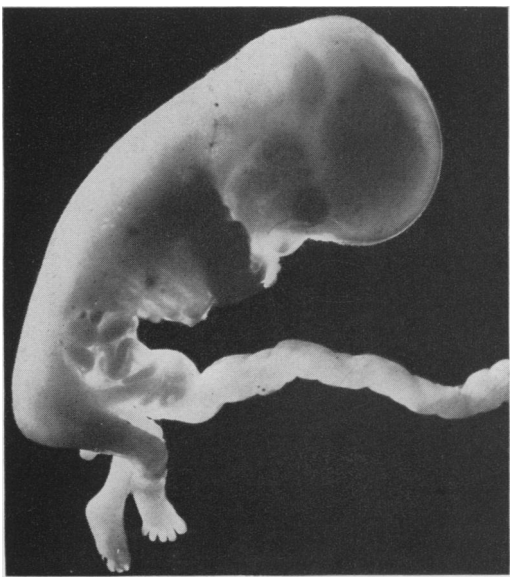

FIG. 6. Photograph of 37 mm. CRL embryo, lateral view, with cord and membranes left intact. Intestinal coils have been brought into focus by a strong light placed behind the embryo. It is evident there are intestinal loops both within the cord and the abdominal cavity.

kopf's cross sections and diagrams (p. 27 Abb 5-A and Abb 5-B, 25 mm. embryo, and p. 41 Abb 9-B and Abb 8-B, 32 mm. embryo), and in the accounts by Keith,[15] and Bardeen,[1] who have indicated the early rotation of the duodenal jejunal loop. It was also true in the embryos dissected for this study. Although Frazer and Robbins do not grant this rotation during the first stage, it appears evident from their diagrams that the duodenojejunal loop is beneath the artery at this early time.

The final phase of rotation of the duodenojejunal loop occurs with the return of the intestine to the cord which brings the first part of the jejunum to the left of the artery (Fig. 5), and completes another arc of 90°, and a total of 270° in a counter-clockwise direction. This was well seen in one of our unusual embryos,[26] verifying the actual return of the intestine from the cord (Fig. 6). This was the first published photograph of such a transitional stage and the second one reported in all the American literature.[1] It showed the position of the returning jejunum as it passes beneath the superior mesenteric artery to a position to the left of the artery. It demonstrated the persistence of the cecum and right colon on the left of the artery and within the cord, and indicated the start of the next phase of rotation of the cecocolic loop when it drops back into the abdomen.

ROTATION OF THE CECOCOLIC LOOP

Returning to the 5 mm. embryo (Fig. 7), the entire intestinal tract lies in the midline, with a slight anterior curve in the central portion. Into this curve runs the superior mesenteric artery at right angles to the posterior wall of the embryo. The lower, or inferior portion of the curve represents the terminal ileum, cecum and colon. This section of bowel lies inferior to the artery. This is the starting position for the cecocolic loop, or 0° rotation, as indicated on the dial.

During the fifth week, or when the embryo is about 10 mm. in length (Fig. 8), the central curve has formed a loop, and at the same time the cecocolic loop has moved from beneath the artery to the left of the artery, or through an arc of 90°. This position relationship of the caudal limb of the loop with the artery remains the same throughout the first ten weeks of embryonic life, or until the embryo is about 40 mm. in length. As the cecum drops back into the abdomen from the cord, it still lies to the left of the artery.

FIG. 4. Schematic ventrolateral view of 25 mm. embryo, indicating the further rotation of the duodenojejunal loop to a position inferior to the superior mesenteric artery, through an arc of 180°. The extension of the remainder of the intestines into the cord is not shown.

FIG. 5. Schematic ventrolateral view of the 40 mm. embryo, indicating the final rotation of the duodenojejunal loop to a position immediately on the left of the superior mesenteric artery. This loop having passed from a position superior, to the right, beneath and to the left, or through an arc of 270° in a counter-clockwise direction. This final rotation of the duodenojejunal loop takes place as the intestines return from the cord.

FIG. 7.

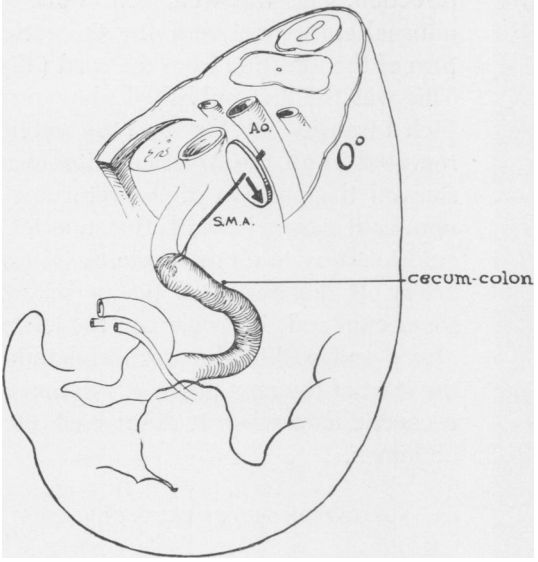

FIG. 8.

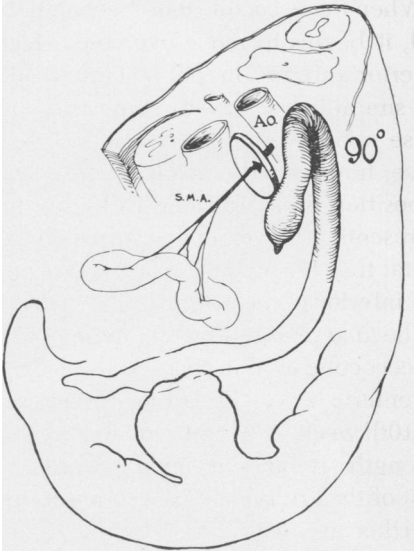

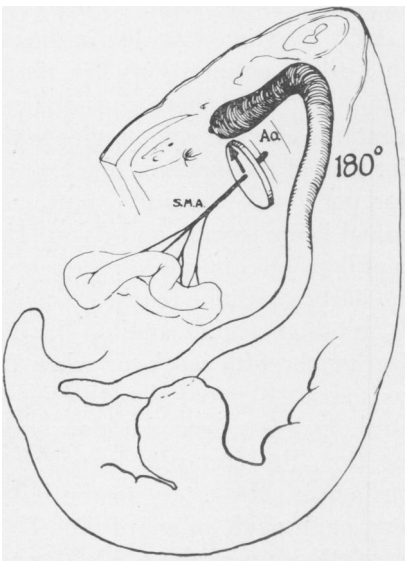

FIG. 9.

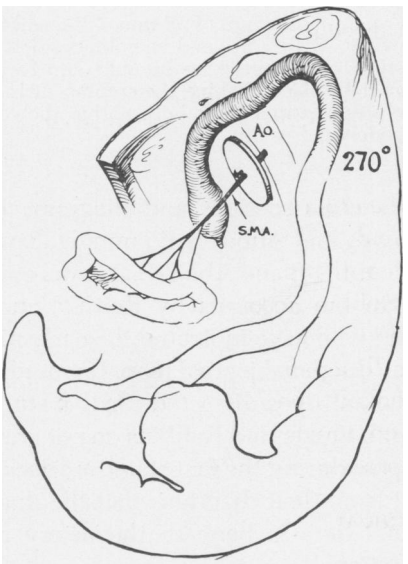

FIG. 10.

FIG. 7. Schematic ventrolateral view of 5 mm. embryo, indicating the forward bend of the intestinal tract. The cecocolic loop is emphasized as it lies inferior to the superior mesenteric artery, or in a position of 0° rotation, as indicated on the dial about the base of the artery. The 0° rotation position for this loop is inferior to the artery, whereas the 0° rotation position for the duodenojejunal loop is superior.

FIG. 8. Schematic ventrolateral view of 40 mm. embryo, showing the position of the cecocolic loop at the left of the superior mesenteric artery, having rotated through an arc of 90° from its starting position inferior to the artery (see dial at base of SMA). This phase of rotation is maintained while the intestines are in the cord and at the moment they drop back into the abdomen.

FIG. 9. Schematic ventrolateral view of 40 mm. embryo, indicating rotation of cecocolic loop to a position superior to the superior mesenteric artery, or a rotation through an arc of 180°, from the starting position inferior to the artery. This phase takes place immediately after the return of the intestines from the cord into the abdomen.

FIG. 10. Schematic ventrolateral view of 40 mm. embryo, showing final position of cecocolic loop to the right of the superior mesenteric artery. This loop, having passed from a position beneath, to the left, superior and finally to the right, or through an arc of 270°, in a counterclockwise direction.

When the cecocolic loop becomes abdominal, it begins to move over the artery in a superior anterior direction. This is, perhaps, too simplified a way to show rotation, because actually the artery itself is made to move; however, the result of these changes in position is as indicated in Figure 9. This represents a movement of a further 90°, or a total thus far of 180°, from a starting position inferior to the artery.

The final phase (Fig. 10) in the position of the cecocolic loop in relation to the superior mesenteric artery is reached shortly after the 10th week, or in embryos 40 mm. or more in length. It takes its final position to the right of the artery. This is a rotation through a further arc of 90°, or a total for this segment of bowel of 270°, in a counter-clockwise direction.

ATTACHMENT OF THE MESENTERY TO THE POSTERIOR ABDOMINAL WALL

The attachment of the mesentery of the small and large intestine to the posterior abdominal wall follows the normal rotation of the loops and occurs during what Frazer and Robbins have called "the third stage of rotation." This important stabilizing process is hardly a part of rotation, but rather should be looked upon as a completing phase of fixation which is not possible unless the normal process of rotation has transpired.

CLINICAL APPLICATION AND CORRELATION

Failure of this process of fixation accounts for the mobility of the entire mesentery of the intestine, and allows for volvulus which so frequently accompanies malrotation. The account of this step by step motion of the two leading loops of intestine about the superior mesenteric artery requires a mental visualization of the intervening loops for a more complete understanding. However, this knowledge of the movement of the loops of intestine, from their beginning until they reach the adult position, enables the surgeon to recognize quickly arrests in this normal process. Only those who have been faced with this problem can understand how important it is. The applications of embryology in surgery are numerous.[3, 11, 19, 25, 28] This particular aspect of it, namely, rotation, is concerned with omphalocele, right and left paraduodenal hernia, left sided colon and appendix, etc.; however, it is best studied clinically in a group of cases termed "malrotation." This group of cases includes Dott's classification of nonrotation, reversed rotation,[6, 21, 30] etc. An even wider coverage term would be "extrinsic duodenal obstruction," as discussed by Edwin Miller,[23] and others.[8, 17] The group here to be presented consists of 40 cases of malrotation treated at the Los Angeles Childrens Hospital during 1937 to 1952.*

ANALYSIS OF CASES

All 40 patients were operated upon with one exception, and in this child autopsy was performed, so that the anatomical findings in all cases are known. The position of the two loops are given diagramatically in Figure 11. Some of the earlier descriptions were inadequate, but this is a close approximation. It is obvious from this figure that arrest in rotation can occur at any phase. It is felt, however, that with further emphasis on a study of the position of the loops, especially the duodenojejunal loop at surgery, the number showing nonrotation of the duodenum will increase. In recent cases in which the entire duodenum and first part of the jejunum were dissected free, the majority were in the II position. Among the 40 cases of malrotation, all had duodenal obstruction either from a twist at the duodenum, or from adhesive bands. In 32 cases, a volvulus of the small intestine accompanied the anomaly. In 19 of them, the cecum and right colon were also involved in the twist. Gardner and Hart[6] found a somewhat similar distribution in a collected series.

This group, then, includes all cases of extrinsic duodenal obstruction occurring at the Childrens Hospital, except those pro-

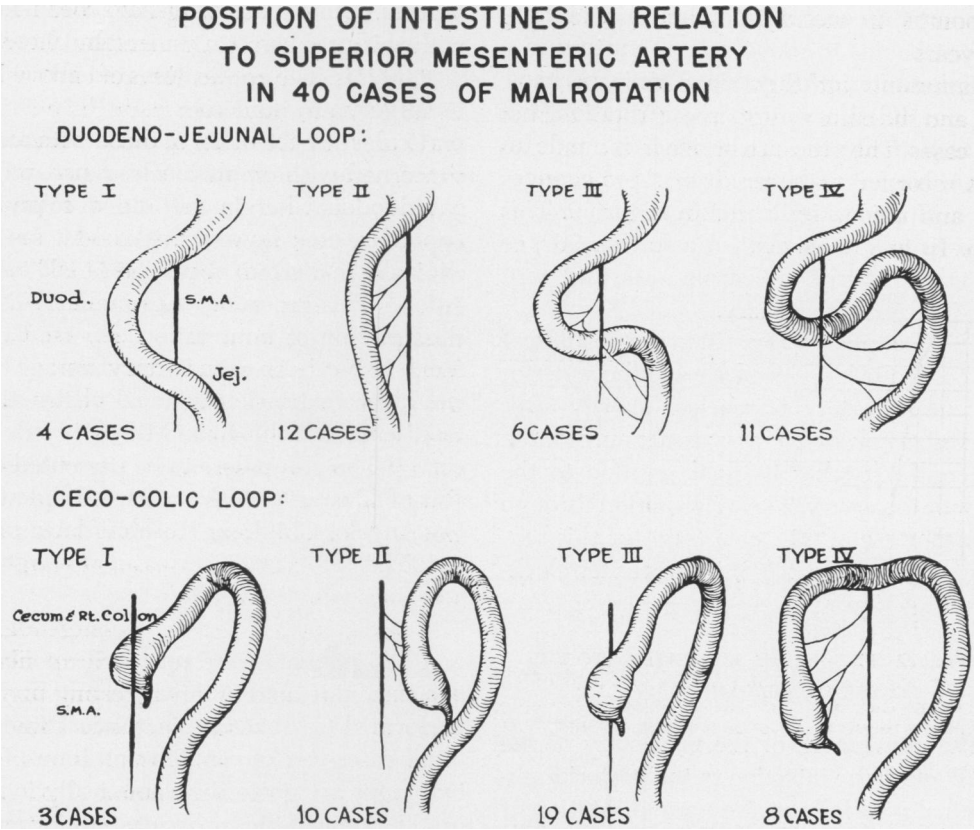

FIG. 11. Descriptions of the 40 cases of malrotation indicated that there were four (Type I) in which the duodenum and jejunum lay in a position anterior to the superior mesenteric artery; 12 (Type II) in which it extended to the right of the artery, etc. The cecocolic loop was in a position posterior, or behind the superior mesenteric artery in three cases (Type I). It lay to the left of the artery in ten cases (Type II).

Thus, the positions of the two leading segments in the clinical cases have been correlated with their positions found during embryonic development.

duced by annular pancreas, simple bands, external tumors, etc. They all gave evidence of some defect in the process of rotation. This, then, is the common denominator, both embryologically and clinically.

Incidence. During the 15 years covered by this report, 1937 to 1952, an estimated 3,861 abdominal operations, excluding hernias, were performed on infants and children. There were 40 cases of malrotation in this series, making an incidence of about 1 per cent. There have been reported over 300 cases of this entity in the literature, up to this time. There were, in this series, 26 males and 14 females, indicating a predominence of males of about two to one.

Family History. Only two of these infants were premature. Ten of the 40 represented the first child; three were cesarean sections, one for pre-eclampsia, one for fibroids, and one for low placenta. Five mothers had a history of miscarriage or previous death of a child in infancy. Four parents had a severe asthma and/or hay fever; two, diabetes.

Age. The age at the time of hospital admission is indicated in Figure 12. Seventy-five per cent of the patients had the onset of symptoms during the first week of life, although they were not admitted to the hospital until later, as indicated in Figure 12. Symptoms began in the remaining cases at 12 days, 14 days, 25 days, 26 days, 30 days,

8 months, 21 months, 2 years, 8 years, and 12 years.

Symptoms and Signs. Vomiting was present and the chief symptom in 100 per cent of the cases. The presence of bile in the vomitus was recorded 26 times. It was projectile in ten and amounted to regurgitation only in two. In two cases there was coffee ground

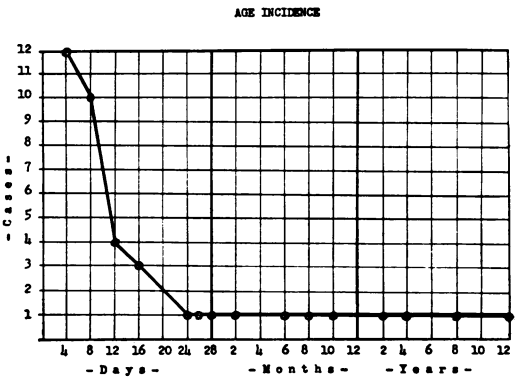

FIG. 12. The number of cases are indicated on the left, the age at hospital admission is below. It is evident that over half the cases had presenting symptoms requiring admission within the first week of life, and that over three-fourths were admitted to the hospital before the first month of life.

vomitus, and in one, gross blood. This finding has been previously reported by others.[21] This child had 90 cm. of gangrenous bowel resected at surgery. In three cases there were reversed gastric waves. About one-half of the patients showed evidence of dehydration and only five appeared gravely ill. Stools were absent or meager in 22, and normal in ten. Melena occurred in three. Two of these had gangrene, requiring resection, and the other child had a discolored bowel which became viable after release of the volvulus.

The abdomen was soft, not distended, and showed no evidence of tenderness or other abnormality to examination in 22 of the cases. There was marked distention in six, and moderate distention in 12; tenderness in only two, hyperperistalsis in five, and absent peristalsis in an equal number. In none was there clinical evidence of anomalies, although in one there was a history of an omphalocele at birth. There were none in which cretinism was suggested, and none in this series is known to be mentally defective.

The temperature was elevated above 100° F. in 14 cases, and the white blood count was above 10,000 in 26; of those with an elevated blood count all but four had accompanying volvulus. In the five with primary or secondary gangrene, the blood count was above 16,000 in four cases and 11,000 in one. In recent years, blood CO_2, chlorides, potassium and sodium have been taken, but have rarely been significantly altered. The urine has been examined in almost every case with the following findings: 2 to 4 plus albumin, seven cases; 2 to 4 plus acetone, three cases; 20 white blood cells per high power field, one case. No child later developed known urologic disease, although one had an absent kidney.

Roentgenologic Studies. Roentgenograms were taken in 35 patients. A Scout film, or flat film, was helpful in suggesting high obstruction in 18 cases, and indicating predominence of right sided small bowel in 11. The absence of normal amount of gas in the small bowel of the newborn was helpful in 12 cases. Small amounts of barium were administered by mouth in 11 cases, and was helpful in making the diagnosis by demonstrating duodenal obstruction in ten cases. In no case was there evidence of a harmful effect of this procedure. Barium enemas were administered to nine patients, and in all demonstrated a left sided, or abnormal position of the cecum.

Surgery. Surgery was performed on 39 of the 40 patients. The one unoperated infant was moribund on entry. Although it is important to take time to institute the necessary diagnostic studies and to prepare the child with proper fluids, electrolytes and blood, early surgery is important, as gangrene of the bowel was present in two cases, and in four additional patients the bowel was bluish but became viable after release of the volvulus.

The usual findings at surgery are the absence of the cecum and right colon from its

usual place, and a cord-like structure in the region of the mesentery of the small intestine. As the intestine is brought outside the abdomen, the volvulus of the entire mesentery, including the right colon, is evident. This typical state of affairs was present in 19 cases. In 13 additional cases of volvulus, however, the cecum and ascending colon were not involved in the twist. In eight cases, no volvulus existed. In all, however, the duodenum was obstructed either by the volvulus or by duodenal bands, or both. When the volvulus has been released, the cecum and ascending colon are freed and the adhesions obstructing the duodenum released, according to the Ladd procedure.[18] When the duodenal jejunal loop has not rotated, the upper part of the jejunum is freed and placed against the right posterior wall of the abdomen (Fig. 13). This relieves jejunal obstruction and stabilizes the mesentery of the jejunum by means of new attachments to the posterior abdominal wall. The authors feel that this added step will aid in preventing recurrent volvulus.

Other complicating anomalies occurred in this series as follows: Duodenal atresia or stenosis, two; Meckel's diverticulum, two; pyloric stenosis, one; omphalocele, one; absence of kidney and ureter, one. The co-existence of duodenal stenosis was not recognized at the first operation in one case and required a secondary procedure, but without recovery. This experience supports the suggestion by Glover[8] of passing the stomach catheter through the duodenum at the end of the operative procedure, before closing the abdomen.

If the duodenum and jejunum are completely freed, and the adhesions attaching the cecum and right colon severed and this part of the bowel placed in the lower abdomen, it is probably not necessary to fix the cecum to the right posterior wall, as has been suggested.[6, 21, 32] Two cases operated upon during the first year of this series did have recurrent volvulus; however, in neither of these was the complete Ladd operation performed. A third recurrent volvulus was operated upon in this hospital, but the first operation had been done elsewhere and the details of the procedure are not available. Thus, these three instances, and those recorded in the literature,[16, 21, 27] do not provide a valid argument for fixation of the cecum, as the initial operation for release of the volvulus and relief of the malrotation probably had not been complete. Fixation of the cecum and right colon to the posterior abdominal wall was performed four times in this series. Two of these cases developed postoperative obstruction, necessitating a second operation, and one case developed clinical evidence of obstruction which cleared on conservative management. This would suggest that fixation of the right colon and cecum may in itself be productive of further obstructions, and so is not routinely advised.

Mortality. There were nine deaths in this series of 40 cases, making a mortality of 23 per cent. The cause of these deaths is described below:

1. One of these patients was moribund on admission.
2. The second death was the result of a postoperative closed loop obstruction with gangrene, which was not suspected. The child died without operation.
3. One child with malrotation and an unsuspected atresia of the duodenum did not survive.
4. One child in whom 12 cm. of gangrenous bowel was resected had signs of continued obstruction, but no autopsy was performed.
5. Another child died with continued signs of obstruction.
6. One child had gangrene of 90 cm. of small intestine, which was resected. The child died three months later of inanition.
7. Another child died in shock following a second operation for continued obstruction.
8. There was one death from recurrent volvulus.

9. One child died eight days after a second operation for obstruction. Autopsy showed no obstruction or peritonitis, but cerebral sinus thromboses.

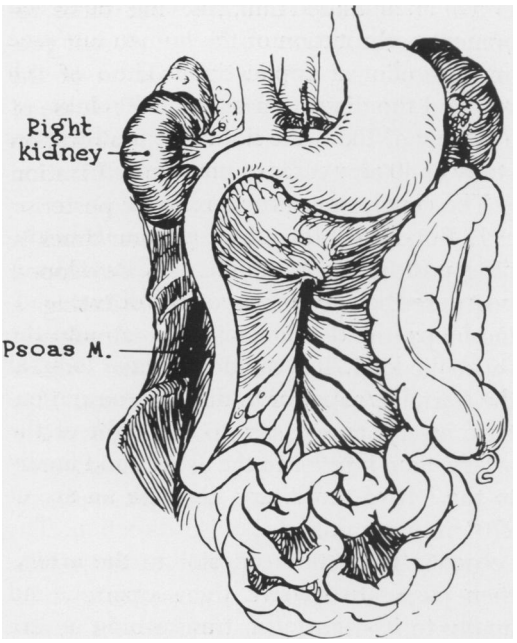

FIG. 13. The duodenojejunal segment has been freed from its attachment to the mesentery of the small intestine and placed against the psoas muscle in the right gutter. This step in the operative correction of malrotation is important. When the duodenojejunal loop has not rotated, it stabilizes the mesentery of the small intestine and prevents recurrence of volvulus.

This mortality of 23 per cent is comparable to that reported by Glover,[8] 25 per cent; Ladd,[17] 37 per cent; and by McIntosh and Donovan,[21] 33 per cent; and is identical with the mortality recently reported by Gross,[10] when all cases, including those with other anomalies, are included. During the last five years at this hospital, there have been 15 cases with one death, or a mortality of six per cent in this small series.

Comment. Rotation of the intestine in the embryo has been described as movement of the two leading loops, the duodenojejunal and the cecocolic loop, about the superior mesenteric artery through an arc of 270° in a counterclockwise direction. The duodenojejunal loop starts superior to the superior mesenteric artery and comes to lie to the left of the artery. The cecocolic loop begins inferior to the artery and ends up on the right of the artery. The artery runs in an anterior posterior direction, or at right angles with the posterior wall and is to be considered the axis of rotation. This is indicated in the accompanying diagrams. It is understood that the intervening bowel is included in this rotation, and this phase of the process is revealed in an unusual embryo, showing the intestine in the actual process of returning from the umbilical cord to the abdomen. An arrest in the process of rotation tends to prevent attachment of the mesentery of the small and large bowel, and results in a mobile entire intestine, subject to volvulus. Production of abnormal adhesions results in small bowel obstruction, most often duodenal. An understanding of this defective embryological process makes possible, at surgery, early recognition of the condition by tracing out the position of the two leading loops. Its correction results from releasing the volvulus and completely freeing up these loops, and allowing a fixation of the duodenojejunal limb to the right posterior abdominal wall.

Emphasis is placed in this account on the movement of the duodenum and jejunum from a starting position in the midline superior to the superior mesenteric artery in the 5 mm. embryo, to the final adult position on the left of the artery. This phase of the rotary process has not been stressed in the past, but an understanding of it and its application to clinical surgery should be of real value. The steps in the process and the timing of this motion have been worked out in many embryos and documented in the literature. The swing of this loop beneath the artery is evident in 25 mm. specimens long before the second stage of rotation. From an embryological standpoint, then, the "urge" for rotation is first evident in this segment of

the intestine, and an arrest in its motion probably lays the stage for arrest in the cecocolic segment and a failure in attachment of the mesentery to the posterior abdominal wall. This results in the clinical manifestations described, and reinforces the importance attached to the complete freeing up of the duodenojejunal segment in the surgery of malrotation.

An analysis of 40 new instances of malrotation at the Los Angeles Childrens Hospital indicates the primary failure of rotation of the two loops in various phases. It provides clinical examples of arrest in the rotatory process of the intestine in all stages of development. This correlation of embryology and clinical pathology aids in the grasp of both subjects.

This study indicates that among hospital admissions with malrotation, an incidence of 70 per cent occur in newborn infants. There is a predominance of males. The leading symptom is persistent vomiting, which was present in 100 per cent of the cases. Frequently there are minimal abdominal findings. A roentgenogram will suggest high obstruction if no gas is present in the small intestine of newborns. Barium enema almost always reveals an abnormally placed cecum.

Surgery brought about a cure in 77 per cent of the cases. An analysis of the deaths indicates that relief of the volvulus and complete freeing of the duodenum and cecum and right colon should bring about a decreasing mortality. In addition, freeing of the jejunum and placing it against the posterior abdominal wall should aid in preventing recurrent volvulus. Recognition of a concomitant duodenal atresia can be facilitated by passing the stomach tube through the jejunum at the time of surgery. The removal of all intestine from the abdomen will facilitate reduction of the volvulus. Attachment of the cecum and right colon to the posterior abdominal wall is usually not required, if the duodenojejunal loop and cecocolic loop are completely freed. The preparation of the patient is important. In the last 15 cases, the mortality was 6 per cent.

SUMMARY

This study is the outcome of the production of an animated film, showing the development and rotation of the human intestine and the clinical applications. The research entailed the dissection of some 50 embryos, a review of the basic literature, and a close study of 40 new cases of malrotation.

The conclusions are as follows:

1. Rotation of the intestine from its beginning position as a straight midline tube is best described as the movement of two leading loops, the duodenojejunal loop and the cecocolic loop. The duodenojejunal loop, at the start, lies superior to the superior mesenteric artery, and passes to the right of the artery, then inferior to the artery, and finally to the left of the artery, through an arc of 270° in a counter-clockwise direction. The cecocolic loop starts inferior to the artery, then passes to its left, then superior, and finally to its right, also transcribing an arc of 270° in a counter-clockwise direction about the artery.

2. Arrest of this process is clinically manifest as malrotation which may occur at any phase in either or both loops. Accompanying the arrest is a failure of attachment of the mesentery of the bowel to the posterior abdominal wall, and the formation of obstructing adhesions, especially about the duodenum and jejunum. The incompletely attached mesentery results in volvulus, and the adhesions in extrinsic obstruction.

3. Embryological and clinical correlation in 40 new cases of malrotation emphasizes the importance of early diagnosis of high intestinal obstruction and its correction by release of the volvulus and complete freeing of the adhesions of both loops, according to the Ladd procedure.

4. This study also supports the contention that when feasible, additional freeing of the jejunal loop and placing it against the posterior abdominal wall is important, from

an embryological and clinical standpoint, in maintaining stabilization of the mesentery and preventing recurrent volvulus.

BIBLIOGRAPHY

1 Bardeen, C. R.: The Critical Period in the Development of the Intestines. Am. J. Anat., **16:** 427, 1914.

2 Beeger, H.: Volvulus Caeci. Deutsche Ztschr. f. Chir., **178:** 240, 1923.

3 Coley, W. B., and J. P. Hoguet: Retrocecal Internal Hernia. Ann. Surg., **90:** 765, 1929.

4 Dott, N. M.: Anomalies of Intestinal Rotation: Their Embryology and Surgical Aspects: With Report of Five Cases. Brit. Jour. Surg., **11:** 251, 1923.

5 Frazer, J. E., and R. H. Robbins: On Factors Concerned in Causing Rotation of Intestine in Man. J. Anat. and Physiol., **50:** 75, 1915.

6 Gardner, C. E., Jr., and D. Hart: Anomalies of Intestinal Rotation as a Cause of Intestinal Obstruction: Report of Two Personal Observations; Review of 103 Reported Cases. Arch. Surg., **29:** 942, 1934.

7 Gardner, C. E., Jr.: The Surgical Significance of Anomalies of Intestinal Rotation. Ann. Surg., **131:** 879, 1950.

8 Glover, D. M., and F. M. Barry: Intestinal Obstruction in the Newborn. Ann. Surg., **130:** 480, 1949.

9 Graham, H. E.: Volvulus of the Cecum. Surg., Gynec. & Obst., **42:** 351, 1926.

10 Gross, R. E.: The Surgery of Infancy and Childhood. W. B. Saunders Co., Philadelphia and London, 1953.

11 Hamann, C. A.: Faulty Rotation of the Intestine. Ann. Surg., **76:** 491, 1922.

12 His, W.: Anatomie menschlicher Embryonen. Leipzig, Verlag Von F. C. W. Vogel 1880–1885, Part III, p. 12.

13 Huntington, G. S.: The Anatomy of the Human Peritoneum and Abdominal Cavity. Lea Bros. and Co., Philadelphia and New York, 1903.

14 Jackson, C. M.: On the Developmental Topography of the Thoracic and Abdominal Viscera. Anat. Rec., **3:** 361, 1909.

15 Keith, A.: Human Embryology and Morphology, Fifth Edition. William Wood and Co., Baltimore, 1933, p. 321 and 326.

16 Ladd, W. E.: Congenital Obstructions of the Duodenum in Children. New Eng. J. Med., **206:** 277, 1932.

17 Ladd, W. E.: The Choice of Time and Type of Operation in Surgery of Early Life. Pa. Med. & Surg. J., **46:** 677, 1943.

18 Ladd, W. E., and R. E. Gross: Abdominal Surgery of Infancy and Childhood. W. B. Saunders Co., Philadelphia and London, 1941.

19 Lower, W. E., and C. C. Higgins: Retroperitoneal Hernia. Ann. Surg., **82:** 576, 1925.

20 Mall, F. P.: Development of the Human Intestine and Its Position in the Adult. Bull. Johns Hopkins Hosp., **9:** 197, 1898.

21 McIntosh, R., and E. J. Donovan: Disturbances of Rotation of the Intestinal Tract. Am. J. Dis. Child., **57:** 116, 1939.

22 Meckel, J. F.: Biedungsgeschichte des Darmkanals der Saugethiere und namentlich des Menschen. Deutsches Archiv fur die Physiologie; Vol. III, Part I, 1817.

23 Miller, E.: Bowel Obstruction in the Newborn. Ann Surg., **110:** 587, 1939.

24 Pernkopf, E.: Development of the Form of the Stomach and Intestinal Canal in Man. Ztschr. f. Anat., **77:** 1, 1925.

25 Rixford, E.: Failure of Primary Rotation of the Intestine (Left Sided Colon) in Relation to Intestinal Obstruction. Ann. Surg., **72:** 114, 1920.

26 Snyder, W. H., Jr., and L. Chaffin: An Intermediate Stage in the Return of the Intestine from the Umbilical Cord. Anat. Rec., **113:** 451, 1952.

27 Stewart, J. S.: Congenital Extrinsic Duodenal Obstruction in the Newborn. South. Surg., **14:** 15, 1948.

28 Summers, J. E.: The Dilated Duodenum. Ann. Surg., **88:** 576, 1928.

29 Treves, F.: Lectures on the Anatomy of the Intestinal Canal and Peritoneum in Man. Brit. M. J., **1:** 417, 1885.

30 Truesdale, P. E.: Retroposition of the Transverse Colon: Report of Two Cases. J. A. M. A., **104:** 1697, 1935.

31 Vogt, W.: Morphologische u. kausalanalytische Untersuchungen uber die Lageentwicklung des menschlichen Darmes. Ztschr. f. Angew. Anat. u. Konstitutionsl, **2:** 87, 1917.

32 Wangensteen, O. H.: New Operative Technics in the Management of Bowel Obstruction. Surg., Gynec. & Obst., **75:** 675, 1942.