48. DEUCHER, W. G. AND LEIGH-SMITH, A.: *Schweiz. med. Wchnschr.*, 73: 1092, 1943.
49. LEBLOND, C. P. AND BÉLANGER, L. F.: *Anat. Rec.*, 94: 98, 1946.
50. LEBLOND, C. P. AND LACASSAGNE, A.: *Am. J. Roentgenol.*, 50: 801, 1943.
51. SEIDLIN, S. M., MARINELLI, L. D. AND OSHRY, E.: *J. Am. M. Ass.*, 132: 838, 1946.
52. PERCIVAL, W. AND LEBLOND, C. P.: (Unpublished results).

PNEUMOPERITONEUM IN THE TREATMENT OF PULMONARY TUBERCULOSIS[1, 2]

M. Aronovitch, B.Sc., M.D., C.M., F.R.C.P.[C.], F.C.C.P.[3]
Lloyd A. Caswell, M.D.[4] and
Jarrah A. Zadé, B.A., M.D., D.P.H.[5]

Montreal, Que.

PULMONARY collapse is the mainstay of active therapy for tuberculosis, and is tried in one form or another on most patients hospitalized with this disease. Methods of collapsing the lung must be varied to meet the condition of the patient, the stage of the disease, the location of the lesion in the lung, and the amount of pulmonary tissue involved. No single method can be applied indiscriminately to all cases, and it is unusual for any case to be benefited by only one method of collapse therapy. More often various methods must be tried in combination or in succession, and sometimes all methods may fail.

Any new procedure by means of which the diseased lung may be put at rest must be tested in many different types of cases before its proper place can be determined in the armamentarium of the collapse therapist. The more usual methods have attempted to collapse the lung directly by introducing air intrapleurally or extrapleurally, or by removing portions of the ribs and allowing the chest wall to fall in on the retracting lung. Operations on the phrenic nerve have long been known, and have found a limited use in certain types of cases.

In general we know the intra-thoracic pressure to be somewhat on the negative side. The intra-abdominal pressure, on the other hand, tends to be somewhat on the positive side, or at any rate not quite as highly negative as the intra-thoracic pressure. The muscular tone of the diaphragm is interposed between the differences in pressure of the abdominal and thoracic cavities and resists, as it were, the upward thrust of the intra-abdominal pressure against the thorax. If the phrenic nerve is interrupted, there is no muscular resistance between the two pressures, and the diaphragm rises in the chest, allowing the lung to collapse to a small extent. This is the basis for the familiar operations on the phrenic nerve in collapse therapy.

The concept of increasing the intra-abdominal pressure by an induced pneumoperitoneum, and thus raising the diaphragm still higher, is not new, but the method has only come into use slowly since it was first advocated by Banyai in 1931. It is evident that if the intra-abdominal pressure is raised to sufficiently high levels by air injections, the diaphragm will rise provided the muscles of the abdominal wall are not so flaccid as to absorb all the increased pressure. If one-half of the diaphragm is paralyzed, either before or after pneumoperitoneum is induced, the air will tend to collect under this paralyzed muscle and raise it to a higher level than the non-paralyzed half. It is evident therefore that with sufficiently high intra-abdominal pressures, collapse of certain parts of both lungs can occur, but that this collapse can be made predominantly unilateral by interrupting the phrenic nerve on one side. Fig. 1 shows an x-ray of the chest before the institution of a pneumoperitoneum and phrenic operation. Fig. 2 shows a rise in the level of both sides of the diaphragm, but the marked increase which occurs on one side by combining this procedure with a phrenic crush. The amount of pulmonary collapse which can be obtained is clearly considerable.

Our first cases of pneumoperitoneum were done at the Grace Dart Home Hospital in 1938.* A total of 42 cases forms the basis for this preliminary report. Before analyzing these cases, it would be well to examine more closely the advantages of this method of collapse therapy. We have already indicated that a measure of bilateral collapse is secured, and that in association with a phrenic operation, considerable unilateral collapse can be obtained. It is true that the familiar pneumothorax procedure might be more desirable in some cases, but this pro-

1. From the Grace Dart Home Hospital, Montreal, Que.
2. Read (in part) at a meeting of the Montreal Clinical Society, February 26, 1947.
3. Physician, Grace Dart Home Hospital; Lecturer in Medicine, McGill University.
4. Assistant Medical Director, Grace Dart Home Hospital.
5. Assistant Medical Resident, Grace Dart Home Hospital.

* During the war years, Dr. G. A. P. Hurley started several cases.

cedure often fails. In some bilateral cases it is undesirable due to the extent of the disease; in many other cases it is impossible to secure pulmonary collapse because of complete pleural symphysis or inoperable pleural adhesions. Pneumothorax had been tried and found wanting in most of the cases under consideration at present. In the past such cases have had to follow one of two courses: (1) a thoracoplasty or other major operative procedure on the involved side; or (2) sanatorium care only because the disease was too far advanced to consider a major operation. In many cases thoracoplasty is still the method of choice where a simpler measure like pneumothorax, fails, and this is especially true if the cavity is apical. If the cavity is lower down, especially if it is in the mid- or lower-zones of the lung, thoracoplasty becomes less desirable since there are greater chances of failure to close the lesion by this

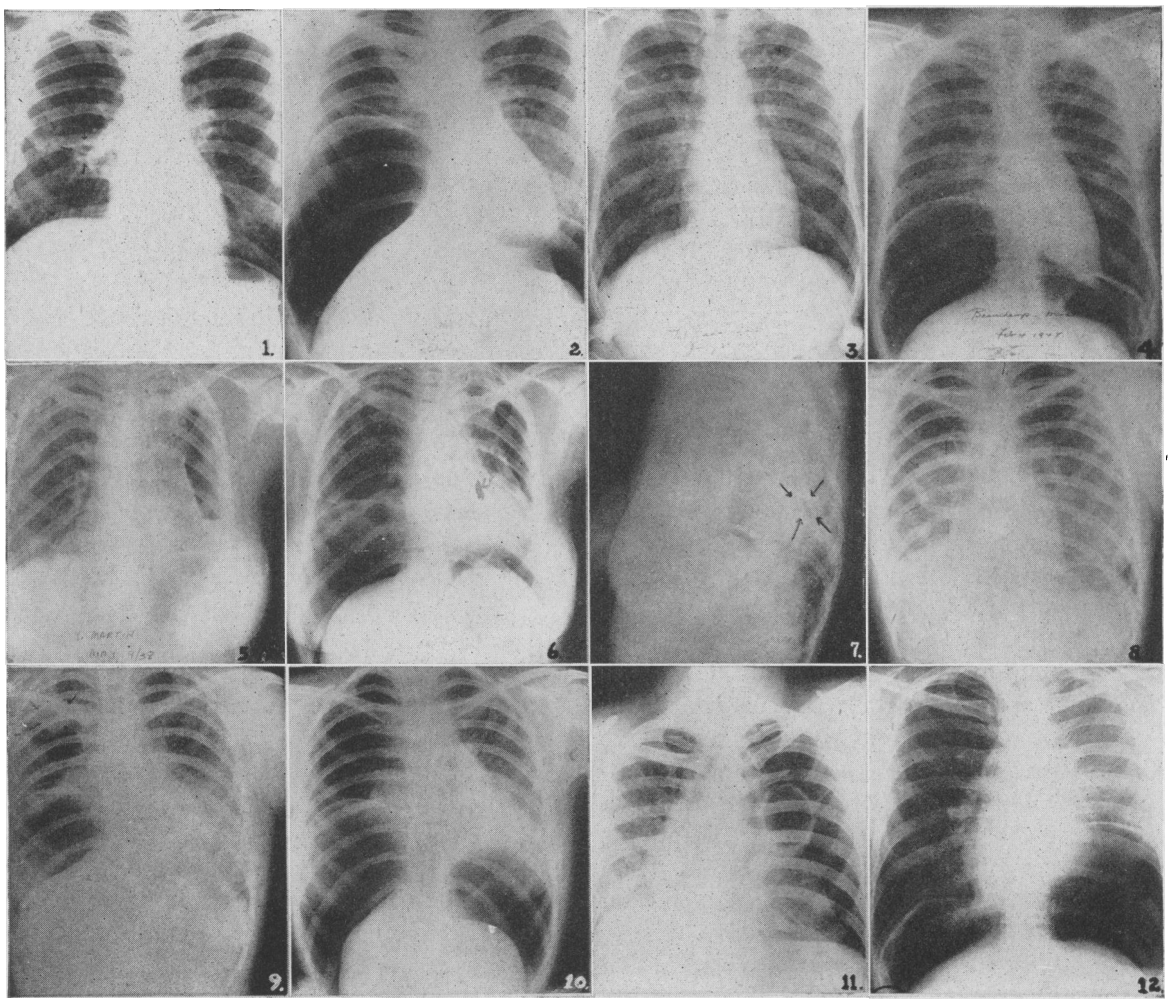

Fig. 1.—Before pneumoperitoneum was instituted. The arrows indicate the cavity. **Fig. 2.**—The same case as in Fig. 1. Pneumoperitoneum has been instituted and a phrenic crush done on the right side. Right hemidiaphragm has risen; the cavity can no longer be seen. **Fig. 3.**—Cavity in the right upper lobe, in the second interspace. **Fig. 4.**—The same case as in Fig. 3 after using a right phrenic crush and pneumoperitoneum. The cavity is now closed. **Fig. 5.**—Two cavities are shown just above the right dome of the diaphragm. A pneumothorax is present on the left. **Fig. 6.**—The same case as in Fig. 5 showing how some cavities fail to collapse with pneumoperitoneum. They are seen below the level of the dome of the diaphragm. **Fig. 7.**—The same case as in Fig. 5. The cavities have not closed because they are placed so far posteriorly as to slip between the ribs and the crura of the diaphragm. **Fig. 8.**—X-ray of Case 2 showing giant cavity on the right side. **Fig. 9.** Case 2.—A pneumoperitoneum and a right phrenic crush have obliterated the original giant cavity but a fresh one has appeared in the right upper lobe. **Fig. 10.** Case 2.—The pneumoperitoneum has been continued but a pneumothorax has been added to control the right upper lobe cavity. **Fig. 11.** Case 4.—Showing a giant cavity with adhesions on the left side. **Fig. 12.** Case 4.—After a left phrenic crush and pneumoperitoneum were done following a complicating effusion.

means. In these mid- or lower-zone lesions, lobectomies have been tried in recent years, but they too seem to be on the way out of favour.

A pneumoperitoneum may be eminently successful in these cases, and may collapse and close a cavity which might otherwise require a major operation. Another advantage of this procedure is that it is reversible, and that the amount of collapse may be controlled by the amount of air injected. It also may be tried for a limited period of time without damage to the lung and with very little danger. If it works, so much the better. If it does not work, the air may be withdrawn or allowed to absorb, and some other procedure tried. One of the disadvantages of pneumothorax has been that if it is long continued it causes pleural thickening and may render the collapsed lung useless in the future. Pneumoperitoneum, because it does not involve the pleura directly, is not likely to cause this eventual failure in lung function.

The relaxation of the lung by pneumoperitoneum is followed by an increased drainage of inflammatory products from cavities and from the bronchial tract. In many cases which, prior to therapy, had a difficult and non-effective cough, pneumoperitoneum was followed by an easy evacuation of sputum with a slight or even effortless cough. As in any surgical inflammatory collection of pus, drainage removes toxicity and thereby improves the patient's general condition. We have observed patients who have a marked basal emphysema which was secondary to a long-standing tuberculosis whose dyspnœa has been relieved by pneumoperitoneum. Obliteration of cavities is purely a mechanical effect attributable to the rise of the diaphragm. To obtain complete healing of these lesions it is necessary that pneumoperitoneum be maintained for an adequate period of time.

Some investigators have raised the objection that pneumoperitoneum cannot give complete rest to the affected lung. This objection may be true, but is just as valid for any collapse procedure. In fluoroscoping pneumothorax cases, for instance, it is uniformly observed that the collapsed lung moves beneath the instilled air. This continuing respiratory function of the lung collapsed by any of the usual procedures has also been proved in both pneumothorax and thoracoplasty cases by the bronchospirometric studies of Jacobaeus, Pinner, and others. The argument that pneumoperitoneum should not be used because it does not put the lung at complete rest cannot, therefore, be taken too seriously.

TECHNIQUE

The technique of air instillation is simple. The initial procedure may require a certain amount of experience, but this is not difficult to acquire. Essentially, it consists of careful local anæsthesia of the abdominal wall at some suitable site—usually in the left lower quadrant—until the peritoneum has been penetrated. Air is then allowed to enter the peritoneal cavity and pressures can be taken with the usual pneumothorax apparatus. The pressures tend to be on the positive side and the respiratory fluctuations are less marked than those in the chest.

Other sites than the left lower quadrant may be chosen for the initial induction and we have used all sites except the right lower quadrant, due to the fear of appendiceal adhesions. When the needle is immediately under the diaphragm, the pressures may tend to the negative side and the fluctuations may be more marked due to the adjacent diaphragmatic movements. Most authorities prefer to avoid the right upper quadrant for fear of penetrating the liver.

The amount of air injected at the initial filling varies from 100 to 700 c.c. Refills in carrying on therapy are usually given at weekly intervals, with amounts varying from 500 to 2,000 c.c. at positive pressures from 5 to 18 cm. of water. The wearing of an abdominal binder helps keep the diaphragm high after refills.

Complications are remarkably few. We have had only one major complication on induction—an air embolism with transient hemiplegia for four days, and subsequent recovery. This occurred in one of our earliest cases. In over 1,200 refills we have had no major complications. A moderate number of cases develop subcutaneous emphysema which is never of any serious moment. This is usually due to a faulty position of the needle. Mediastinal emphysema may occur due to the tracking of air up through the hiatuses of the diaphragm. Most cases complain of pain in the region of the shoulder blades after the first few refills. This is seldom sufficient to cause interruption of therapy.

Some cases develop minor peritoneal effusions which can be disregarded. We have one case with a considerable peritoneal effusion. This is probably due to a pre-existing tuberculous peritonitis, and is not interfering with continu-

ing therapy. It is likely that some cases will develop peritoneal adhesions necessitating cessation of therapy, but we have not run across this complication yet. Any fear of puncturing the bowel has been groundless in our cases so far.

INDICATIONS

So much for the procedure itself. What have been our indications for its use? Roughly speaking, we can divide our types of cases into two large groups. (1) The cases with predominantly unilateral lesions where pneumothorax has failed. In this group the situation of the disease has been such that we considered pneumoperitoneum the next best procedure of choice. These we have called our definitive cases; 23 cases have been treated in this manner and in 19 of them a phrenic crush was done on the side with most involvement. (2) The markedly bilateral cases with a poor prognosis. Here the patients were victims of far advanced disease and they were, for the most part, unsuitable candidates for pneumothorax or thoracoplasty, though in many cases pneumothorax had been tried and found unsuccessful. These patients were on the downgrade, and in most of them, phrenic interruption was not done because it was inadvisable to reduce their impaired vital capacity by an irreversible procedure. It was felt that pneumoperitoneum being reversible, could safely be tried in the presence of a low vital capacity, and could readily be abandoned if dyspnœa or other signs of anoxia appeared.

This second group of cases is again divisible into two: (*a*) The extremely far advanced cases with exceedingly poor prognosis. We have called pneumoperitoneum here "expectant therapy" using the procedure and waiting to see what would happen. We have had 14 cases in this group, and we have used a phrenic operation in only one. (*b*) A group of far-advanced bilateral cases in whom possibilities of major operative procedures could be considered on one side if the other could be got into shape to stand the operation. Here we have labelled pneumoperitoneum "adjunctive therapy", feeling that it was only being used as an adjunct to other collapse measures to be instituted at a later date. We have had only 5 cases in this group, in 2 of whom a phrenic operation was done.

CHART 1.

	Definitive cases		*Adjunctive cases*		*Expectant cases*	
	With phrenic	*Without phrenic*	*With phrenic*	*Without phrenic*	*With phrenic*	*Without phrenic*
Number of cases	19	4	2	3	1	13
Died	1	..	..	..	..	6
Worse	..	..	1	2	1	2
Unimproved	..	1	1	1	..	2
Improved (sputum not changed)	4	..	..	..	..	1
Improved (sputum converted)	14	3	..	..	..	2

CHART 2.

Total number of cases	*Died*	*Worse*	*Unimproved*	*Improved*	*Sputum converted*
42 (100%)	7 (17%)	6 (14%)	5 (12%)	5 (12%)	19 (45%)
	Total unimproved 18 (43)%			Total improved 24 (57%)	
Definitive cases 23 (100%)	1 (4%)	0	1 (4%)	4 (17%)	17 (74%)
Other cases 19 (100%)	6 (32%)	6 (32%)	4 (21%)	1 (5%)	2 (10%)

Charts 1 and 2 show our results in these groups of cases. It will be seen that in bilateral cases the results have not been strikingly good. However, since these are cases with a hopeless prognosis, even slight encouragement justifies us in continuing therapy.

In the predominantly unilateral group the results are strikingly good, insofar as there has been a high percentage of sputum conversion. Of course, these cases have not been followed to complete cure yet—that will take years—but we can see no reason why the sputum should not continue negative once it has become so. It is merely a matter of keeping on with the original therapy until the disease is healed.

In these cases the location of the lesion is important. Broadly speaking, the lesion should be in the mid- or lower-zone, and situated in the central or anterior part of the lung. In

this connection we might state that upper lobe lesions often appear to be in the mid-zone on the flat film, as illustrated by 9 cases in our definitive group with the lesions in the upper lobes. All of these cases were improved, and in 8 of them the sputum was converted from positive to negative. Even lesions in the first interspace may respond favourably to this type of therapy. Figs. 3 and 4 illustrate a lesion high in the lung and its improvement with a good pneumoperitoneum. Lateral figures or tomograms are desirable as basal posterior lesions may not collapse. Figs. 5, 6 and 7 show how such lesions may slip behind the crura of the diaphragm and remain patent.

In our experience, indications for pneumoperitoneum have been: (1) Moderately advanced bilateral pulmonary tuberculosis where artificial pneumothorax can not be given. (2) Cases of unilateral pulmonary tuberculosis in which pneumothorax is indicated but can not be carried out due to adhesions, age of the patient, or other serious complication. (3) To supplement a phrenic crush where a phrenic crush has failed to produce the desired effect. (4) As an adjunct to artificial pneumothorax in selected bilateral cases. (5) As a preliminary measure in early bilateral cases of pulmonary tuberculosis to render the patient suitable for other methods of collapse therapy later on. (6) Basal lesions in the lung with or without cavitation.

The results which may follow the use of pneumoperitoneum are illustrated in the following cases:

CASE 1

M.B., aged 26, first learned that he had pulmonary tuberculosis in 1944 when he was rejected by the Army. He received no active therapy until admission to the Grace Dart Home Hospital in July, 1946. Examination at this time showed bilateral far-advanced pulmonary tuberculosis with a 2.5 cm. cavity in the right upper lobe. Sputum was positive for tubercle bacilli. There was intermittent low grade pyrexia.

In August, 1946, right pneumothorax was induced. The sputum became negative in September. In spite of conversion of sputum, pneumothorax had to be abandoned in October because of extensive inoperable pleural adhesions. Pneumoperitoneum was induced in October 1946 and a right phrenic crush was done in November, 1946. Pneumoperitoneum has been continued to date with 800 to 1,500 c.c. of air given at 7 to 14 day intervals. Clinical improvement has been satisfactory, sputum has been negative consistently since September, 1946.

CASE 2

Miss M.I., aged 22, had a hæmoptysis in May, 1944. Examination in July 1944 revealed bilateral far advanced pulmonary tuberculosis. Sputum was positive. On admission to the Grace Dart Home Hospital in August, 1944, it was found that there were abnormal shadows in both lung fields. There was a giant cavity in the apex of the right lower lobe (Fig. 8). General condition was good. In October, 1944 a right phrenic crush was done. A pneumoperitoneum was induced in August, 1945. It is to be noted that sputum was converted in January, 1945, and has remained negative to date. We feel that pneumoperitoneum has produced greater relaxation of the involved lung and thus gives greater assurance of final healing. Pneumoperitoneum refills are being continued at approximately weekly intervals in amounts between 1,000 and 1,500 c.c. The phrenic nerve has been crushed twice since October, 1944 (Figs. 9 and 10).

CASE 3

In June, 1946, D.P., aged 19, was found on routine examination to have pulmonary tuberculosis. There was extensive disease in the right lower lobe with cavitation in the apex of this lobe (Fig. 1). The sputum was positive. He was afebrile and his general condition was excellent. Patient was admitted to the Grace Dart Home Hospital in July, 1946, when a right phrenic crush was done and pneumoperitoneum was induced (Fig. 2). Treatment has been well tolerated. The sputum has been consistently negative since July, 1946. Refills of 1,000 to 15,000 c.c. of air have been given at 7 to 14 day intervals.

CASE 4

The onset of pulmonary tuberculosis in J.C., aged 34, appears to have been in 1943. On admission to the Grace Dart Home Hospital in December 1944, patient had a left pneumothorax which was complicated by a band of adhesions (Fig. 11). There was a 4 cm. cavity in the upper part of the left lung. There were abnormal shadows throughout the right lung. Sputum was positive. Closed pneumonolysis was done in December, 1944. In spite of an apparently successful operation, extensive pleural effusion developed. Pneumothorax was discontinued and in May, 1945 a left phrenic crush was done. Pneumoperitoneum was induced in August, 1945. Pneumoperitoneum refills of 1,200 to 1,800 c.c. of air have been given at 7 to 14 day intervals (Fig. 12). It has been necessary to repeat the phrenic nerve crush twice. Sputum became negative in April, 1945, and has remained negative to date. He has been continuing therapy as an out-patient since July, 1946. In November, 1946, he had a slight peritoneal effusion discovered by x-ray which cleared spontaneously in three months and did not interfere with the maintenance of therapy.

CASE 5

In 1943, M.L., aged 27, consulted a physician because of weight loss and easy fatiguability. Bilateral pulmonary tuberculosis with a giant cavity in the apex of the left lower lobe was found. He was admitted to the Grace Dart Home Hospital in February, 1946. At this time there had been apparent arrest of the disease on the right side. The cavity on the left side had remained in spite of prolonged bed rest and pneumothorax, which was complicated by several inoperable adhesions. Sputum was positive. Temperature was normal, and general condition good. In March, 1946, a cavernostomy was performed and the cavity in the left lower lobe was drained by open drainage. In March, 1946, pneumoperitoneum was induced following the cavernostomy. A left-sided phrenic crush was performed in May, 1946. The sputum became negative in May, 1946, and remained so until January, 1947. At this time a lesion in the left upper lobe which appeared to be breaking down was thought to be responsible for the positive sputum. To date there has been no evidence of residual cavitation in the left lower lobe. It is likely that some other form of collapse will be required for the lesion in the left upper lobe.

In conclusion we feel that there are definite benefits to be derived from the use of pneumoperitoneum therapy and that by its means col-

lapse of tuberculous lesions can be secured and sputum converted in selected patients who would otherwise die or require extensive major surgery.

BIBLIOGRAPHY

1. BANYAI, A. L.: Pneumoperitoneum Treatment, C. V. Mosby Co., 1946.
2. BENATT, A. J.: *The Lancet*, August 17, 1946.
3. EDWARDS, P. W. AND LOGAN, J.: *Tubercle*, 26: 1, 1945.
4. HAWKINS, F. S. AND THOMAS, G. O.: *Tubercle*, 27: 82, 1946.
5. SCHMIDT, E. A.: *Am. J. Roentgenol.*, 54: 375, 1945.
6. SIMMONDS, F. A. H.: *The Lancet*, 250: 530, 1946.
7. STEEN, P.: *Brit. J. Tuberc.*, 39: 3, 1945.

INFLUENZA IN NORTHERN NEWFOUNDLAND*

E. H. J. Smyth, M.B., B.S.

Calgary, Alta.

A ROADLESS community, shut off from outside contact save by the to and fro of occasional dog-teams, offers for the study of epidemic disease facilities not found amongst densely populated areas served by modern communications.

When the influenzal stream of 1945-46 struck this part of Newfoundland, the St. Anthony Hospital, serving the entire northern peninsula of the island, was well placed to observe its flow from beginning to end. After the last mail-boat leaves in December or early January the resident populations of the northern settlements remain unchanged throughout the freeze-up; dog-team communication between villages a few miles apart is kept up, but longer journeys are almost confined to those occasioned by the three emergencies of accident, sickness or death. Perhaps twice a winter the drone of wings is heard over St. Anthony, and the *Norseman*, a ski-equipped plane belonging to the government, comes in to land on the harbour with a fresh batch of medical supplies. Otherwise, on all this coast, isolation from the rest of the world is unbroken from January until the end of June.

An epidemic virus, arriving here from some crowded city, finds itself among unprotected hosts, poor for the most part and often underfed. Houses are thinly built, and wood, the only fuel, has often to be fetched five to seven miles by dog-team. In December and January, 1945-46, three-quarters of the dogs of northern Newfoundland died of distemper; as a result many hearths were cold. Pulmonary tuberculosis is three times more frequent than in Canada. Though temperatures seldom go excessively low, humidity gives the cold a very penetrating quality. Thus it is not surprising that the virus of influenza, arriving in an atmosphere of "35-below" on the coldest day of the year, was received with even more than the usual large slice of hospitality associated with the people of this coast.

An account of the arrival, clinical behaviour, spread and disappearance of the epidemic in the town of St. Anthony forms the basis of this article. A community of a thousand people, the largest in the peninsula, the town had been visited by no epidemic of comparable magnitude since the pandemic of 1918. The tabulated figures are confined to the township itself, but mention is made of the clinical features of other cases, brought into hospital from elsewhere or seen on the winter medical journeys, as well as those who contracted the disease whilst in hospital for other causes.

The *S.S. Kyle* came butting through the harbour ice on January 14, 1946, on a special late trip extra to schedule. A few minutes after she tied up I was examining our local Ranger—as the Newfoundland police are called—returned home from St. Johns with high fever and pain in the back. (His illness was doubly unfortunate in that a fight had just taken place on the boat and, being weakened by fever, he had been unable to check it. Later I was able to provide evidence of his condition to silence the indignant protest of the defeated combatant!)

In the next five weeks, between January 14 and February 19, when the last case went down, 735 of the 946 people of St. Anthony contracted the malady. The ensuing tables are self-explanatory. Of the 168 family groups the residents of the Grenfell Hospital and of the Orphanage were the two largest and are shown separately. Hospital cases, except those from

TABLE I.

Group	*Population*	*Bed cases*	*Ambulant*	*Total*	%
St. Anthony.....	946	563	172	735	82
Hospital and Orphanage—adult staff.....	39	31	1	32	82
Orphanage children —all ages to 21...	62	56	0	56	89
Returned from Europe in the past 6 months.....	22	2	0	2	9

The 22 returned personnel consisted of 18 servicemen, 1 woman, 3 children. Both the cases were servicemen.

* From the International Grenfell Association Hospital, St. Anthony, Nfld.