Late Postoperative Intestinal Obstruction

ANGELO M. MAY, *M.D.*, San Francisco

• Early postoperative intestinal obstruction is most successfully treated with intestinal intubation with a long intestinal tube of the Miller-Abbott, Harris or Cantor type, and only when this fails is reoperation indicated. However, late postoperative intestinal obstruction is better treated by operation as soon as the diagnosis is established and the patient is prepared for the procedure.

Decompression of the bowel at the time of operation has become a procedure of choice and it is now possible to completely decompress the bowel in the course of the operation using a Foley catheter inserted through a stab wound in the bowel. Details of the technique are described in this article.

EVEN UNDER MODERN CONDITIONS the mortality from intestinal obstruction is high. Early observers, summarizing cases from various sources from 1907 to 1931, gave figures ranging from 32 to 61 per cent. Present experience is perhaps a little better. The cause of death in acute intestinal obstruction is a problem that has engaged the attention of physicians and investigators for over a hundred years. The disease is often dramatic in the suddenness of onset and the rapidity of course. The literature abounds with experimental as well as clinical laboratory data that indicate a variety of nefarious processes that work to deteriorate the condition of the patient.

It is generally recognized that the following factors contribute toward the circulatory failure resulting in early death in untreated or unsuccessfully treated intestinal obstruction:

1. *Disturbance of fluid and electrolyte balance.* As the intestine becomes distended with fluid and nitrogen, the reabsorption of water and electrolytes from the intestinal tract becomes impaired, which results in progressive depletion of water and electrolytes in the intracellular and extracellular compartments. Electrolyte studies of the serum readily reflect these changes.

2. *Circulatory changes.* Distention and incarceration occludes circulation of blood and hence interferes with motility and the functions of absorption and digestion. In these circumstances, the bowel wall is subject to invasion by pathogenic organisms of many kinds, as well as by bacteria ordinarily nonpathogenic, and a large surface of tissue thereby becomes involved in an acute inflammatory process.

3. *Toxins.* Bacterial toxins that develop from bacterial action in the bowel dissipate throughout the body and by action upon the vascular system cause shock and other manifestations of systemic poisoning.

4. *Abdominal distention and splinting of the thorax.* Abdominal distention, with its restriction of the motion of the diaphragm and splinting of the chest in general, results in cardiopulmonary changes which are of considerable importance in the presence of the already serious circulatory changes just mentioned.

5. *Local sepsis.* The embarrassment of the circulation of the distended incarcerated loop of the bowel involved may result in gangrene, rupture or abscess formation in the localized area of obstruction, a serious and potentially lethal situation in itself.

There are many more components in individual cases which join in the deteriorative process, but in the majority of cases, the factors mentioned should be considered first in the plans for management.

The work of Wangensteen, Cantor, Harris, Abbott and Maddock in our time, particularly their statistical studies indicating a low mortality rate if treatment is begun early, has developed a general awareness that prompt operation is the *sine qua non* in the late treatment of intestinal obstruction. Those investigators have also indicated that most other methods and features of treatment are ancillary, and mainly of great value in the preparation of the patient for the operative procedure or to sustain him during the period when diagnosis is indefinite. The features of early diagnosis and the laboratory and radiological data which confirm the clinical picture are so well documented that they need not be discussed here.

Wangensteen was the first to demonstrate clearly the value of decompression in the management of intestinal obstruction. He used a Levine tube and continuous suction. Miller, Abbott, Harris, Cantor and others furthered the treatment of intestinal obstruction with a long intestinal tube with a balloon feature that facilitates the threading of the tube through the intestinal tract. Maddock showed that in early postoperative obstruction, the mortality rate is lower with the long tube treatment than with im-

Submitted February 2, 1959.

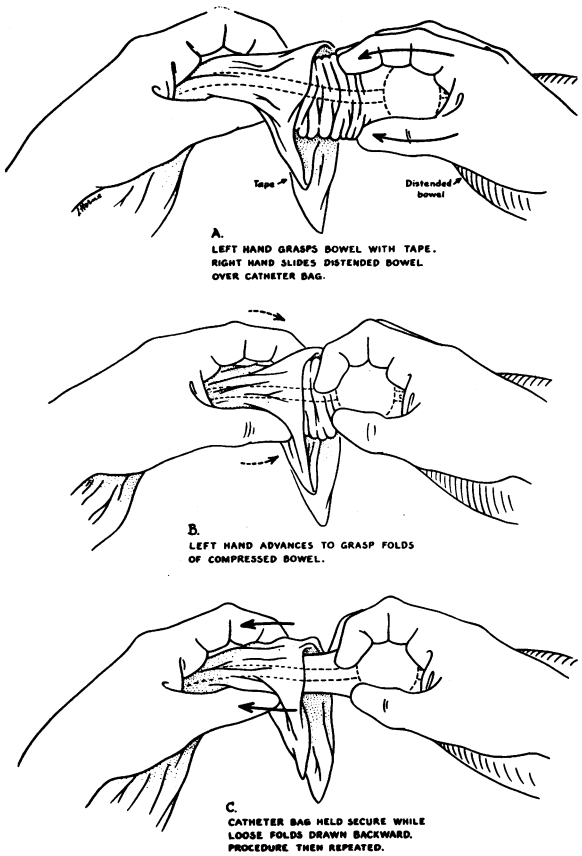

Figure 1.—Method of advancement of ball-tip of catheter through intestine.

mediate secondary operation, and that the reverse is true in cases in which a considerable time has elapsed between the initial operation and the development of obstruction.

Before the era of antibiotics, the opening of an intestine in the presence of obstruction was considered a formidable procedure owing to the hazard of spillage and peritoneal soiling. However, attempts were made to empty the bowel by means of a needle or trocar attached to suction. Cantor found it possible to thread the bowel on a special long decompression suction tip and emphasized the importance of this maneuver.

Wangensteen employed an ordinary French catheter with some degree of success, but this method was not widely applicable owing to difficulty in threading an ordinary catheter very far into the bowel. With the preoperative introduction of the ballooned long tube, it was advocated and occasionally found possible to manually thread the long tube through the bowel from its position in the upper bowel at the time of operation. However, this also sometimes was extremely difficult, particularly when the obstruction was in the lower abdomen.

In 1946, the author began to use the method of introducing a Foley catheter into the bowel at operation, and found the advantage that when the water bag on the catheter was distended, it was possible to draw the catheter through the entire length of the small bowel, first one way and then the other, and thereby completely deflate the intestine at the time of operation (see Figure 1). As experience with this method was obtained, it became apparent that it was possible to prevent spilling through proper introduction of the catheter into the intestine, possible to handle the intestine with great care, and to avoid shock in the handling of the intestine. By this means the bowel could be emptied in situ within the abdomen before it was threaded onto the catheter. Even with the abdomen greatly distended, it was possible to open it and apply this method quickly to empty the bowel and find the point of obstruction.

The procedure is begun by opening the abdomen through a right rectus incision (Figure 2). A distended loop of bowel always rises into the incision as soon as the peritoneum is opened. Whereupon, without delivering the loop, a segment is compressed by a surgical assistant between the forefinger and thumb of his right hand, then the left hand is placed in approximation to the right hand and a small segment of the bowel is emptied of gas and fluid by a pressing, stripping motion between the two forefingers and thumbs. In this emptied segment of bowel, a pursestring suture is placed by the surgeon, and the bowel then is opened and the Foley catheter, which has been attached to the suction, is introduced quickly into the opening and the pursestring suture made taut, closing the bowel snugly about the catheter. The water bag, already tested and attached to the syringe of fluid, is then injected with 10 cc. of sterile saline solution and the butt end secured first by clamping, then by ligation.

Only light suction is used lest the tip of the Foley catheter cleave to the mucosa of the bowel. It is not necessary to determine which way the tip is pointed. With the distended water bag used to advance it, the Foley catheter is pulled through the bowel until the segment is emptied. It is then easy to determine whether the catheter has traveled proximally or distally, for by then a considerable amount of bowel is threaded on it. The first objective in the introduction of the catheter, of course, is to reduce the distention; determining the site of obstruction comes later. If the obstruction is encountered during the first advance of the tube, well and good. It is then relieved and the tube need not be advanced far into the ileum, but it must be withdrawn and threaded into the proximal small bowel until satisfactory deflation is accomplished. Whatever the circumstances, the Foley catheter in each case is followed upward to the proximal jejunum and downward to the region of the ileocecal valve to assure the patency of

the entire length of the small intestine. As obstructions are encountered, adhesions are released and the bowel wall repaired as the occasion requires.

It is well to point out certain precautions to be taken in the use of this method. It is important not to place the pursestring suture until the segment of bowel to be used for insertion of the tube is emptied and kept collapsed by digital compression. Inser-

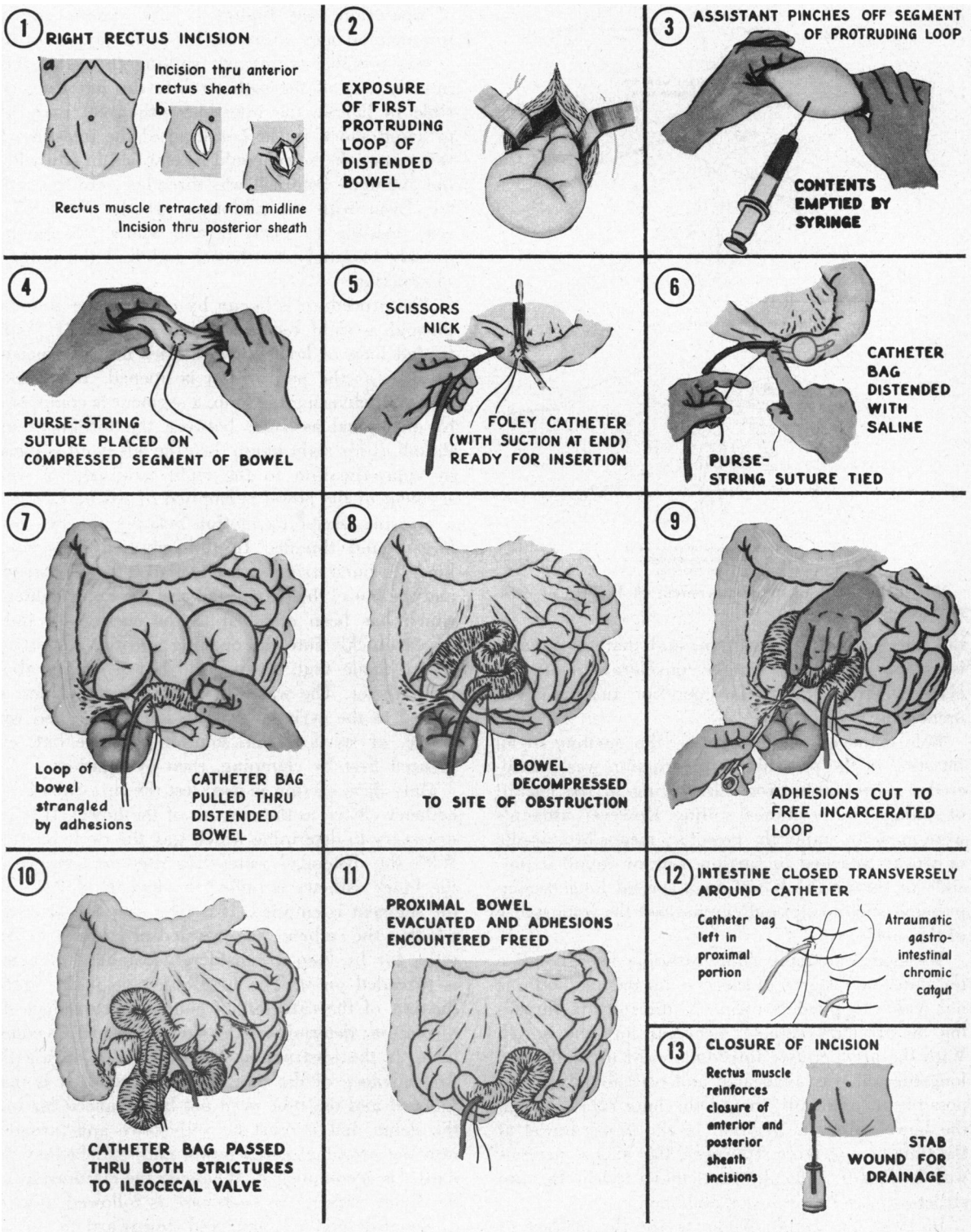

Figure 2.—Procedure for decompression of bowel and reduction of intestinal obstruction.

tion of the sutures while the bowel is still distended may cause material to spurt from it. Unless it pushes through the incision spontaneously, the bowel ought not be removed from the abdomen for introduction of the catheter, for laden and distended as it is it might split open or the mesentery might tear during manipulation. Once emptied, the bowel can easily be taken from the abdomen and inspected its entire length.

A laparotomy tape placed about the site at which the tube is to be introduced will absorb whatever leakage occurs. After decompression and the freeing of the obstruction, other adhesions which appear likely to lead to further obstruction should also be freed.

Besides serving for decompression, the Foley catheter is brought out through a stab wound in the side as a temporary ileostomy. When the time comes for closing the abdomen, a second layer of sutures is placed to form a valve about the Foley catheter. They are placed transversely from the mesentery border to the Foley catheter on either side as a Lembert suture. It is believed that transverse rather than longitudinal placement of the suture leads to greater patency in the bowel when the tube is removed. The butt end of the catheter is pulled out through the stab wound, the bowel being brought over near to the peritoneum. It is not necessary or advisable to sew the bowel to the peritoneum wall in this area. Indeed in many instances, particularly if the mesentery is short, it is permissible to leave a space of two or three inches between the bowel wall and the peritoneum rather than stretch the bowel to the peritoneal wall. The Foley catheter is connected to a simple gravity drain, and the catheter is irrigated frequently after the first four hours to prevent clogging. It may be secured to the skin by a three-tailed piece of adhesive strapping. The catheter is left in the bowel for at least eight days and preferably ten; then the water bag is emptied and the catheter removed. Leakage from the stab wound is controlled by a dressing, but before it is applied the skin is painted with aluminum paste for protection against the digestive juices.

If the abdomen was greatly distended before operation, considerable time may pass before the motility and secretory ability of the bowel is regained. Hence not much material will drain from the ileostomy tube at first, and it is wise in such circumstances to keep a Levine tube in the stomach attached to suction, mainly for the purpose of keeping nitrogen from entering the bowel through the oral route. With combined gastric suction and ileostomy drainage, the abdomen remains flat until peristalsis returns and the patient can be fed by mouth. Oral feeding may be begun when (1) peristalsis is stethoscopically audible over the abdomen, (2) flatus is passed per rectum, (3) a yellowish rather than black exudate drains from the ileostomy tube, (4) yellow bile is aspirated from the stomach tube, and (5) the patient feels hungry.

Thrombosis in the mesentery does not preclude satisfactory management of the patient with intestinal obstruction, or even management with the method herein described, provided the process is limited. One of the cardinal features of the syndrome of mesentery thrombosis of arterial or venous nature is the intestinal obstruction that results. In some cases, circulatory changes are so severe as to warrant resection of the bowel and anastomosis of the segments. However, even when mesenteric thrombosis is found to be the cause of obstruction, it is considered worthwhile in certain cases to try deflation with a Foley catheter before resorting to resection, for the small intestine is so well supplied with collateral circulation that often there is remarkable return of color to the bowel wall as soon as distention is relieved. If pink color returns and the bowel bleeds when scratched with a knife, it is unlikely resection will be necessary. Decompression ileostomy probably will suffice, care being taken that the tip of the catheter is above the involved area so that deflation of the small intestine continues. Sometimes it may be necessary to insert a second catheter for this purpose.
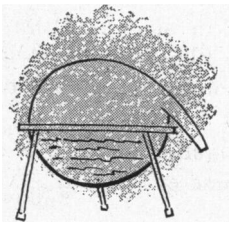
450 Sutter Street, San Francisco 8.