Use of Methocarbamol in Orthopedics

WILLIAM B. LEWIS, *M.D.*, Riverside

• A new skeletal muscle relaxant, methocarbamol, was used in the treatment of 38 patients with a variety of severe neurological disorders and skeletal muscle spasm states.

Eighty-two per cent of the patients studied obtained a beneficial result ranging from excellent to fair.

Mild side effects such as drowsiness were observed in five patients, mild weakness in three patients and excessive perspiration in one. In two of the five patients who complained of drowsiness, it disappeared upon reduction of dosage and did not reappear when original dosage was reinstituted.

FOR MANY YEARS, the problem of reflex skeletal muscle spasm has been a troublesome one in the fields of orthopedics and physical rehabilitation. There are three possible approaches to the treatment of this state: First, blocking of the afferent impulse by either intramuscular or perineural injection of a local anesthetic agent; second, the interruption of the transmission of information across the internuncial neurons in the spinal cord; and third, rendering of the motor end-plates temporarily incapable of transmission of the nerve impulse to the muscle. Of these possibilities, the second has for many years been most favored and numerous agents have been introduced in an attempt to achieve this end. Unfortunately, either they have been ineffective or the side effects have been pronounced.

In 1950, Ginzel[6,7] reported the efficacy of glyceryl guaiacolate as a skeletal muscle relaxant. However, the duration of its action was too short to consider it an effective therapeutic agent. Other studies by Burger[1] and Richardson and co-workers[12] indicated that the monocarbamate ester of mephenesin had a longer duration of action. In 1953, the carbamate of glyceryl guaiacolate (methacarbamol*) was synthesized and was found in pharmacological testing[8,9] to retain its potent skeletal muscle relaxant powers and at the same time proved to be sufficiently long acting to recommend its use clinically.

Pharmacological studies conducted on the carbamate of glyceryl guaiacolate demonstrated its main locus of action to be at the internuncial neurons of the spinal cord,[8,9] although it is also apparent from some of the pharmacological data that there is a supraspinal effect. This, however, would appear to be of a mild type.

Early investigators reported results from clinical trials[3,4,10,11] which indicated that further extensive study was warranted. Cailliet[2] found methocarbamol to be an excellent skeletal muscle relaxant in the treatment of 14 cases of acute lumbar disk herniation, nine cases of acute ligamentous lumbosacral strain, eight cases of shoulder pericapsulitis, 14 cases of cervical tension state, three cases of herniated cervical disk and two cases of acute torticollis. He also reported favorable results in decreasing the rigidity in two cases of Parkinsonism. No patient in the series had untoward side effects.

*Methocarbamol is the generic name of Robaxin® manufactured by the A. H. Robins Company, Inc., Richmond, Virginia.

Submitted July 14, 1958.

The present communication is a report on the use of methacarbamol in a series of 38 cases.

With regard to assessing the results of drug therapy, it should be emphasized that voluntary muscle disorders are reflections of disease states which may be classified into three major categories: (1) Acute skeletal muscle spasm due to strain, the muscle itself being the source of pain; (2) pathologic change involved in herniation of the nucleus pulposus, in which the basic difficulty is radiculitis with spasm reflexively referred from pressure on the spinal nerve roots; (3) disorders of motor function either due to spinal cord or supraspinal involvement. These broad definitions of disease involvements are emphasized because the response to drug therapy tends to vary so much in chronic neurological diseases. The series here reported upon was made up of five patients in the first category, two in the second and 31 in the third.

Rodriguez-Gomez and co-workers[13] observed that following administration of zoxazolamine and chlorpromazine the spasticity of spinal origin responded much better than that initiated from cortical or sub-cortical areas. Gibson and co-workers,[5] using the double blind technique, noted no amelioration of skeletal muscle spasticity of spinal cord origin following administration of these drugs. It is apparent, therefore, that the complexity of disordered neurophysiology in function and the method of study complicate the evaluation of drugs in patients with chronic neurological diseases.

The present study, which was initially of a browsing nature, was entered upon with a significant degree of skepticism as to the benefits to be obtained from the use of methocarbamol. It was a pleasant surprise to observe the improvement in patients,

several of whom were beyond assistance as far as physical therapy measures were concerned. The study was then amplified to include a wide variety of disorders with the objective of determining what change if any would be wrought in total functioning capability. In all, 38 patients were treated, for the following conditions: Multiple sclerosis, torticollis, congenital spastic right hemiplegia, acute and chronic herniated nucleus pulposus, paraplegia following neoplastic compression at T-3 with surgical removal, acute disseminated encephalomyelitis with paraplegia, residual paralysis of poliomyelitis, severe degenerative arthritis of the hip, amyotrophic lateral sclerosis, lower motor neuron lesion, epilepsy (petit mal), visual impairment and paraplegia secondary to postoperative neuroma removal and/or subsequent arachnoiditis.

The response obtained with methocarbamol was judged on a clinical basis by comparison of observations by the author, two physical therapists and the attending nurse. The patients served as their own controls since they had been observed for periods ranging from weeks to years before the drug was given. If the relief was dramatic, the response was graded as "excellent." If the response was obvious but still lacked the outstanding nature of the first group, it was graded as "good." Where the effect of the drug was to give relief of a recognizable nature but not as pronounced as in the first two groups, it was adjudged "fair." If there was no noticeable response, "negative" was used. An excellent response was obtained in 21 per cent of the cases, a good response in 45 per cent, a fair response in 16 per cent. In only seven cases was the result negative.

In adults, the dosage varied from 3 to 6 gm. a day, and in children proportionately smaller doses were administered.

The following case is typical of those in which the response was excellent.

The patient was a 42-year-old woman with paraplegia following neoplastic compression at the third thoracic vertebra treated surgically.

In 1951, the patient noted buckling of the left knee, which caused her to fall. She also observed poor coordination of the right lower extremity with sharp pains and muscle spasm in the left hip and below the knee on the left side. She was first treated as an outpatient and then admitted to hospital on April 20, 1955, with a diagnosis of spinal cord tumor. At operation it was removed from the level of the third and fourth thoracic vertebrae. After recovery the patient still had decided weakness and severe spasm in the lower extremities.

Upon physical examination the upper extremities were normal. In the lower extremities paresis of all muscular groups was noted, with mild heel-cord and toe extensor contractures on the left side. Babinski's sign was present. There was fair hip flexor power with some extensor thrust on the left side. Cutaneous stimulation on either side of the body from the waist down caused severe, painful mass reflexes.

Methocarbamol was given in a dosage of two tablets (0.5 gm: each) four times a day for a total daily dosage 4 gm., and by the fourth day it was noted that the spasms were fewer and less severe. After three weeks of treatment, the dosage was increased to three tablets four times a day (6 gm.) and was continued at that level for a period of more than two years at the time she was last observed. During that time, the patient was able to have her legs passively extended and noted a return of sensation down to her toes. The muscle spasms were decidedly relieved and she was able to extend the left knee actively, to dorsiflex and plantarflex the left foot and to partially flex the left hip without arousing a mass reflex.

No abnormalities were noted in the urine during the period of therapy. The hemoglobin content of the blood was 13 gm. per 100 cc. and erythrocytes numbered 4.5 per cu. mm. Leukocytes numbered 12,000 per cu. mm.—64 per cent polymorphonuclear cells and 36 per cent lymphocytes.

In reviewing the seven cases in which no clinical response was obtained, it was noted that in one of them there was some evidence of a preexisting tightness and muscle contractures with history of a possible previous attack of poliomyelitis in childhood. There were also in this group three cases of multiple sclerosis and one case of probable multiple sclerosis. Another patient who obtained no response had left hemiplegia secondary to a cerebral vascular accident, and she had had complications owing to repeated transient vascular cerebral episodes. Also all muscle groups in the lower extremities showed atrophy. A seven-year-old patient in this group had mild cerebral palsy but there was no spasm associated with it. His ability to coordinate was not improved.

Five patients in the series had mild drowsiness associated with the drug; and in two cases it disappeared when the dosage was reduced and did not reappear upon reinstitution of the initial schedule. Three patients noticed some weakness, and one patient reported excessive perspiration.

6876 Magnolia Avenue, Riverside.

REFERENCES

1. Berger, F. M.: Central depressant properties of o-toloxypropyl carbamates, Pharmacol. Exper. Therap., 104:468, April 1952.

2. Cailliet, Rene, M. D.: Personal communication.

3. Carpenter, Earnest B.: Methocarbamol as a muscle relaxant—its clinical evaluation in acute trauma and chronic neurological states, Southern Med. J., 51:627, May 1958.

4. Forsyth, H. Francis: Methocarbamol (Robaxin) in orthopedic conditions—preliminary report of one hundred cases, J.A.M.A., 167:163, May 10, 1958.

5. Gibson, J. W., Bluestone, S. S., and Lowman, E. W.: Zoxazolamine and/or chlorpromazine for muscle spasm, J.A.M.A., 165:18, September 7, 1957.

6. Ginzel, K. H.: Comparative examination of some anticonvulsive glycerin ester, Arch. Exptl. Pathol. Pharmakol. (Naunyn-Schmiedeberg's), 212:330, April 1951.

7. Ginzel, K. H., Leupold-Lowenthal, H., and Weis, W.: Animal experiments with Myocain, Wien. Med. Wchnschr., 99:299, June 25, 1949.

8. Little, J. M., and Truitt, E. B., Jr.: A comparison of some CNS effects of 3-(o-methoxyphenoxy)-1,2, propanediol monocarbamate (methocarbamol) with some chemically related interneuronal depressant drugs, J. Phar. & Exper. Therap., 119:161, 1957.

9. Morgan, A. M., Truitt, E. B., Jr., and Little, J. M.: Plasma levels of mephenesin, mephenesin carbamate, guaiacol glyceryl ester and methocarbamol (AHR-85) after oral and intravenous administration in the dog, J. Amer. Pharm. Assn., 46:374, 1957.

10. O'Doherty, Desmond S., and Shields, Charles D.: Methocarbamol—new agent in treatment of neurological and neuromuscular diseases, J.A.M.A., 167:160, May 10, 1958.

11. Park, Herbert W.: Clinical results with methocarbamol, a new interneuronal blocking agent, J.A.M.A., 167:168, May 10, 1958.

12. Richardson, A. P., Jones, P. S., and Walker, H. A.: Physiological disposition of mephenesin and mephenesin carbamate, Federal Proc., 12:361, 1953.
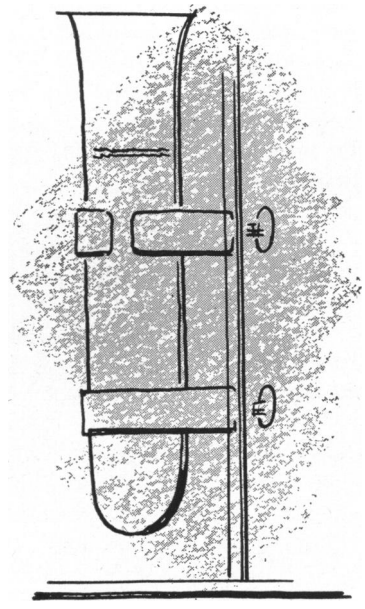
13. Rodriguez-Gomez, M., Valdez-Rodriguez, A., and Drew, A. L.: Effect of zoxazolamine (Flexin) in treatment of spasticity, Preliminary Report, J.A.M.A., 160:752, March 3, 1956.