J. Anat. (2002) **201**, pp513–519

BRIEF COMMUNICATION

Coracoclavicular joint: osteologic study of 1020 human clavicles

S. Gumina,[1] M. Salvatore,[1] P. De Santis,[1] L. Orsina[2] and F. Postacchini[1]

[1]*Institute of Orthopaedics and Traumatology,* [2]*Department of Mathematics, University 'La Sapienza', p.le Aldo Moro 5, 00185 Rome, Italy*

Abstract

We examined 1020 dry clavicles from cadavers of Italian origin to determine the prevalence of the coracoclavicular joint (ccj), a diarthrotic synovial joint occasionally present between the conoid tubercle of the clavicle and the superior surface of the horizontal part of the coracoid process. Five hundred and nine clavicles from individuals of different ages were submitted to X-ray examination. Using radiography, we measured the entire length and the index of sinuosity of the anterior lateral curve, on which the distance between the conoid tubercle and the coracoid process depends. We also used radiography to record the differences in prevalence of arthritis in two neighbouring joints, the acromioclavicular and sternoclavicular joints. Of the 1020 clavicles, eight (0.8%) displayed the articular facet of the ccj. No statistical correlation was found between clavicular length and the index of sinuosity of the anterior lateral curve. The prevalence of arthritis in clavicles with ccj was higher than that revealed in clavicles without ccj. The prevalence of ccj in the studied clavicles is lower than that observed in Asian cohorts. Furthermore, ccj is not conditioned by either length or sinuosity of the anterior lateral curve of the clavicle. Finally, the assumption that ccj is a predisposing factor for degenerative changes of neighbouring joints is statistically justified.

Key words acromioclavicular; degenerative changes; dry bones; morphometry; sternoclavicular.

Introduction

A diarthrotic synovial joint between the conoid tubercle of the clavicle and the superior surface of the horizontal part of the coracoid process of the scapula (coracoclavicular joint, ccj) was meticulously described at the end of nineteenth century (Gruber, 1861; Bennet, 1873; Lane, 1888; Poirier, 1890). In subsequent years, a few papers reported sporadic cases of ccj, occasionally revealed on chest radiograms (Frasseto, 1921; Giongo, 1927; Gradoyevitch, 1939; Slocum, 1941). Further investigations, carried out on skeletons (Ray, 1959; Bainbridge & Tarazaga, 1956; Abe, 1964; Fischer et al. 1971) or on cadavers (Lewis, 1959; Abe, 1964; Pillay, 1967), analysed the prevalence of this anomalous joint, which is more common in Asians than in other races. Over time, interest in this joint focused on the causes of its development. Cho & Kang (1998) observed that frequency of the ccj increases with age, and raised the possibility that the joint may develop as a result of degenerative changes. Cockshott (1979) thought that the presence of ccj was genetically determined.

Two recent studies, performed on a small number of skeletons (Nalla & Asvat, 1995) and cadavers (Cho & Kang, 1998), have tried to correlate the ccj to the size of the scapula and clavicle, but the results were conflicting. No studies have been carried out with the aim of investigating whether the distance between the conoid tubercle and the coracoid process may condition the development of the ccj, being the tubercle located at the apex of the lateral curve of the clavicle, whose sinuosity is enormously variable. Furthermore it is still open to discussion whether the ccj may predispose to degenerative changes of the acromioclavicular (AC) and sternoclavicular (SC) joints, and whether the ccj itself may undergo arthritis.

Correspondence
S. Gumina, via Tacito 74, 00193 Rome, Italy. Tel. 0039 06 3207073; e-mail: s.gumina@tiscalinet.it

Accepted for publication *1 October 2002*

© Anatomical Society of Great Britain and Ireland 2002

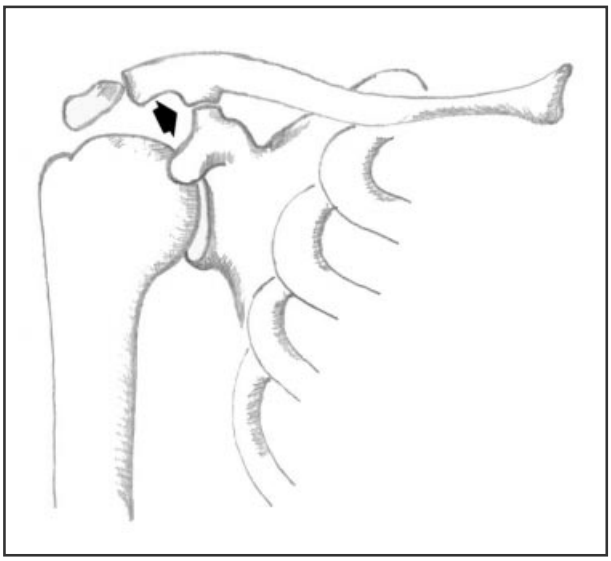

Fig. 1 Diagram showing coracoclavicular joint (arrow).

To clarify whether: (a) the occurrence of the ccj is similar in European and Asian populations, (b) the occurrence of ccj is related to the length and/or sinuosity of the clavicle, and (c) the presence of a ccj is associated with a higher rate of arthritic change in the clavicle, we scrutinized a large number of dry clavicles on which we performed morphological and morphometric evaluations.

Materials and methods

One thousand and 20 dry clavicles from Italian skeletons, dating from the eighteenth and nineteenth centuries and belonging to four collections, were separately scrutinized by each author in order to reveal the presence of the roundish and bulging clavicular facet of the ccj on the conoid tubercle (Figs 1 and 2). Of 1020 clavicles, 650 belonged to male subjects and 238 to females; in the remaining 132 samples gender was unknown. Thirty-seven of 1020 clavicles were of skeletally immature subjects.

We were not allowed to perform radiography on 380 of the 1020 clavicles, because they belonged to a private collection. Of the remaining 640, at least one of the two ends was not integral in 131 cases, and these were therefore discarded.

The remaining 509 clavicles were all adult specimens: 363 males and 146 females (mean age 49.2, range 21–84 years). The inferior surface of the bone was laid on the cassette, positioning the major axis of the AC joint facet parallel to the table. Distance between focus and cassette was 1.2 m; magnification = 9%. A supero-inferior view of each clavicle was obtained. The following measurements were performed on the radiograms: (1) length of the lateral curve of the clavicle (LL), calculated measuring the distance between the anterior margin of the clavicular lateral end and the apex of the convexity of the anterior margin of the medial end; (2) height of the lateral curve (LH), calculated measuring the greater distance of the line traced perpendicularly from LL to clavicle (Fig. 3). The ratio I = LL/LH was considered as the index of sinuosity of the anterior lateral curve. Furthermore, to compare the morphometry of the specimens with and without ccj (3) the clavicular length of the 509 specimens was measured (L) (Fig. 3).

We assigned the adult clavicles to one of three age groups: 20–40 years old, 41–60 years old and more

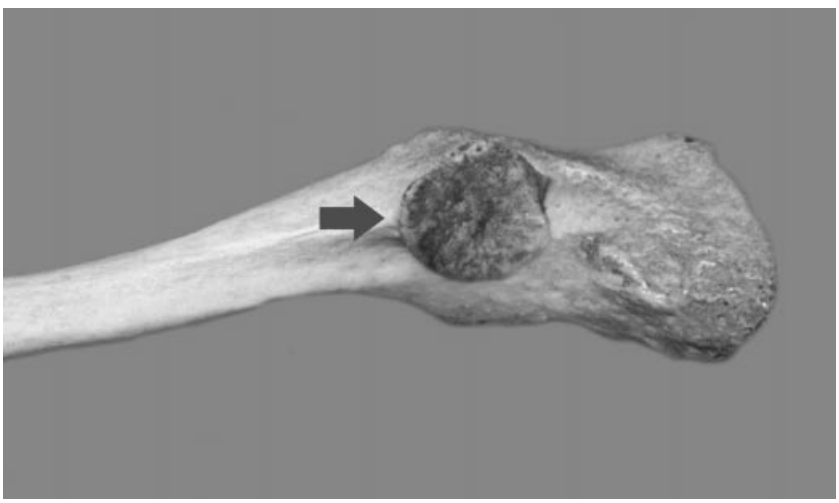

Fig. 2 Inferior surface of a right clavicle. The arrow shows the clavicular facet of the coracoclavicular joint.

© Anatomical Society of Great Britain and Ireland 2002

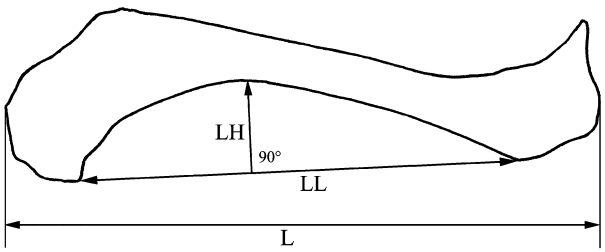

Fig. 3 Measurements that were performed on the radiograms. L, clavicular length; LL, length of the anterior lateral curve; LH, height of the anterior lateral curve.

than 60 years old. In each group, we recorded any degenerative changes of the clavicular facet of the anomalous joint and AC and SC joints.

On the basis of macroscopic examination and of radiographic evaluation, three major patterns of arthritic changes were determined: slight (slight unevenness of the eburneated articular surface, single small cyst), moderate (osteophytes less than 2 mm with moderate unevenness of the articular surface or single large or multiple small cysts), and severe (prominent osteophytes forming a beard-like excrescence around the deformed articular surface or many large cysts).

Statistical analysis was performed using the chi-squared test to assess the relationship between the examined variables. A level of significance of $P < 0.05$ was used. Furthermore, we used Pearson's correlation coefficient to analyse the relationship between the prevalence, in males and females, of degenerative changes of the clavicular facet of the AC and SC joints, respectively. In order to compare the prevalence of arthritis in clavicles with and without ccj, we constructed a mathematical model of arthritis diffusion based on the binomial distribution law (using the percentage of clavicles with arthritis in our sample of 509 clavicles as a parameter) to calculate the probability of finding a certain number of arthritic clavicles in a small fixed size sample.

Table 1 Age and gender distribution of the 509 clavicles on which measurements were performed and evaluation of AC and SC clavicular facet carried out

Age	Male (%)	Female (%)	Total (%)
21–40 year	67 (59.8)	45 (40.2)	112 (22)
41–60 year	110 (64.3)	61 (35.7)	171 (33.6)
> 61 year	187 (82.7)	39 (17.3)	226 (44.4)
Total (%)	364 (71.5)	145 (28.5)	509 (100)

Results

Out of the 1020 examined clavicles, eight (0.8%) (six and two, respectively, of the right and left side of eight different subjects) showed an articular facet for the anomalous joint with the coracoid process. Six of the eight clavicles with ccj were from male subjects and two from females (age range 37–54, mean: 49.2 years). Seven of the eight clavicles belonged to the sample constituted by the 509 skeletrically mature and entire clavicles, whose age and gender distribution is reported in Table 1.

The index of sinuosity of the anterior lateral curve (LL/LH) of the 509 adult clavicles ranged from 4.0 to 18.9 (average 7.2). Table 2 shows how we assigned these different measurements into five groups, obtaining five classes of value corresponding to groups of clavicles whose index of sinuosity of the lateral curve progressively (from 1 to 5) decreases. Ninety-eight per cent of clavicles without ccj (range 4.0–18.9, mean 7.2) belonged to the first three classes (range 4.0–12.9). Analogously, although these data are not statistically significant ($P = 0.15$), all clavicles with ccj (range 4.7–12.3; mean 7.7) belonged to the same classes.

Table 2 Index of sinuosity of the anterior lateral curve of the clavicles with and without ccj. Classes 1–5 correspond to clavicles whose index progressively decreases

	Sinuosity (range LL/LH)				
	most (4.0–6.9)	more (7.0–9.9)	straight (10.0–12.9)	less (13.0–15.9)	least (16.0–18.9)
without CCJ (502)					
N (%)	268 (53.4)	187 (37.3)	36 (7.2)	5 (1.0)	6 (1.1)
LL/LH (avg)			7.2		
with CCJ (7)					
N (%)	3 (42.8)	2 (28.6)	2 (28.6)	0 (0.0)	0 (0.0)
LL/LH (avg)			7.7		

© Anatomical Society of Great Britain and Ireland 2002

Table 3 Length of the clavicles with and without ccj

	Length: range (mm)				
	109–121	122–134	135–147	148–160	161–173
without CCJ (502)					
N (%)	54 (10.7)	134 (26.7	191 (38.0)	111 (22.2)	12 (2.4)
Male (%)	2 (3.7)	47 (35.0)	187 (97.9)	110 (99.1)	12 (100)
Female (%)	51 (96.3)	87 (65.0)	4 (2.1)	1 (0.9)	0 (0)
mean length (mm)					
502			138 ± 12.3 (SD)		
Male (358)			144 ± 8.7 (SD)		
Female 144			123 ± 6.0 (SD)		
range					
Male (358)			114–169		
Female (144)			109–139		
with CCJ (7)					
N (%)	0 (0)	3 (42.8)	2 (28.6)	1 (14.3)	1 (14.3)
Male (%)	0 (0)	1 (33.6)	2 (100)	1 (100)	1 (100)
Female (%)	0 (0)	2 (66.7)	0 (0)	0 (0)	0 (0)
mean length (mm)					
502			139 ± 16.0 (SD)		
Male (358)			145 ± 15.8 (SD)		
Female 144			125 ± 0 (SD)		
range					
Male (358)			131–173		
Female (144)			125–125		

The length of the 509 clavicles varied from 109 to 173 (mean 138) mm, which again we divided into five groups (Table 3). Eighty-six per cent of the clavicles without (range 109–169, mean 138 mm) and with (range 125–172, mean 139 mm) ccj belonged to the second, third or fourth categories ($P < 0.05$). Again, the mean length of the 358 clavicles without ccj of males was 144 mm (range 114–169 mm) compared with 145 (range 131–173) mm of the five with ccj. The mean length of the 143 clavicles without the anomalous articulation in females was 123 (range 109 mm–139) mm, compared with 125 mm of the two with ccj.

Degenerative changes of the AC and SC joint clavicular facet were present in six (85.7%) of these seven clavicles (Table 4); no signs of arthritis were observed in the clavicle facet of the ccj. In four specimens, arthritic changes of the articular facets of the two ends were moderate.

The prevalence and magnitude of degenerative changes of the AC and SC clavicular facets in the remaining 502 entire clavicles without ccj are shown in Table 4. The percentages of clavicles from subjects aged 41–60 years old, without ccj and with degenerative changes of the AC and SC joint clavicular facet, were 64.4% and 60.4%, respectively. In specimens aged between 21 and 40 years of age, the prevalence was lower than in the remaining groups for both joints, and when degenerative changes were present they were more minor. Furthermore, significant differences in rates between the two sexes were not observed, and the prevalence of degenerative changes of the AC clavicular facet was significantly higher than that of SC joint (Pearson correlation = 0.85). In age groups 41–60 and > 61 years, arthritic changes of both joints were more frequent ($P < 0.001$) and severe ($P < 0.001$) in males.

Discussion

It is known that the ccj is an anomalous roundish joint, easily observable in primates (Haramati et al. 1994), which on osteological evaluation appears very different from the cone-shaped ossification of the conoid ligament. In humans, this articulation is extremely rare in Europe, but is common in Asia. Cockshott (1992), in a study based on a survey of published material, observed that frequency decreases as the distance from the epicentre in China increases, and suggested using studies of the ccj as a way of understanding patterns of migration. The prevalence of ccj ranged from 0.7% to

© Anatomical Society of Great Britain and Ireland 2002

Table 4 Normal and arthritic facet of AC and SC joints of clavicles with and without ccj

				Acromio-clavicular joint with					Sterno-clavicular joint with				
	Age class (year)	Sex	All clavicles *N* (%)	Normal *N* (%)	Arthritis *N* (%)	Slight *N* (%)	Moderate *N* (%)	Severe *N* (%)	Normal *N* (%)	Arthritis *N* (%)	Slight *N* (%)	Moderate *N* (%)	Severe *N* (%)
without CCJ	21–40	M	67 (59.3)	29 (43.3)	38 (56.7)	28 (73.7)	9 (23.7)	1 (2.6)	34 (50.7)	33 (49.3)	27 (81.8)	5 (15.2)	1 (3.0)
		F	46 (40.7)	20 (43.5)	26 (56.5)	23 (88.4)	2 (7.7)	1 (3.9)	28 (60.9)	18 (39.1)	17 (94.4)	1 (5.6)	0 (0)
		Tot.	113 (22.5)	49 (43.3)	64 (56.7)	51 (79.7)	11 (17.2)	2 (3.1)	62 (54.8)	51 (45.2)	44 (86.3)	6 (11.7)	1 (2.0)
	41–60	M	104 (63.8)	30 (28.8)	74 (71.2)	46 (62.1)	22 (29.7)	6 (8.2)	35 (33.7)	69 (66.3)	46 (66.7)	17 (24.6)	6 (8.7)
		F	59 (36.2)	28 (47.5)	31 (52.5)	24 (77.4)	7 (22.6)	0 (0)	29 (49.2)	30 (50.8)	28 (93.4)	2 (6.6)	0 (0)
		Tot.	163 (32.5)	58 (35.6)	105 (64.4)	70 (66.7)	29 (27.6)	6 (5.7)	64 (39.6)	99 (60.4)	74 (74.8)	19 (19.2)	6 (6.0)
	> 61	M	187 (82.7)	67 (35.8)	120 (64.2)	63 (52.5)	38 (31.7)	19 (15.8)	68 (36.3)	119 (63.7)	74 (62.2)	34 (28.6)	11 (9.2)
		F	39 (17.3)	20 (51.3)	19 (48.7)	13 (68.4)	6 (31.6)	0 (0)	26 (66.7)	13 (33.3)	11 (84.7)	2 (15.3)	0 (0)
		Tot.	226 (45.0)	85 (37.6)	141 (62.4)	72 (51.0)	50 (35.4)	19 (13.6)	94 (41.6)	132 (58.4)	85 (64.4)	36 (27.3)	11 (8.3)
with CCJ	21–40	M	0	0	0	0	0	0	0	0	0	0	0
		F	0	0	0	0	0	0	0	0	0	0	0
		Tot.	0	0	0	0	0	0	0	0	0	0	0
	41–60	M	5 (71.4)	0	5 (100)	2 (40)	2 (40)	1 (20)	0	5 (100)	2 (40)	2 (40)	1 (20)
		F	2 (28.6)	1 (50)	1 (50)	1 (100)	0	0	1 (50)	1 (50)	1 (100)	0	0
		Tot.	7 (100)	1 (14.3)	6 (85.7)	3 (50)	2 (33.3)	1 (16.7)	1 (14.3)	6 (85.7)	3 (50)	2 (33.3)	1 (16.7)
	> 61	M	0	0	0	0	0	0	0	0	0	0	0
		F	0	0	0	0	0	0	0	0	0	0	0
		Tot.	0	0	0	0	0	0	0	0	0	0	0

© Anatomical Society of Great Britain and Ireland 2002

10% (Ray, 1959; Pillay, 1967; Fischer et al. 1971; Kaur & Jit, 1991), according to data derived from osteological studies or dissection, and from 0.6% to 21% (Wertheimer, 1948; Cockshott, 1963; Fischer et al. 1971) in radiological studies. In our series, we observed eight clavicles (0.78%) with ccj. The size of the sample implies that the actual prevalence of clavicles with ccj is $0.78 \pm 0.71\%$ ($P < 0.01$); this confirms that the occurrence of ccj in Europeans is lower than that observed in Asian cohorts. However, since our study was carried out on dry bones, the proportion of clavicles with ccj may be a slight underestimate. In fact, the presence of cartilaginous facets on the clavicle and coracoid, often regarded as evidence of a joint, may be revealed only during wet dissections (Lewis, 1959).

All of the seven clavicles with ccj belonged to subjects aged from 41 to 60 years old, which tallied with the results of Cho & Kang (1998), whose study of 102 paired clavicles of cadavers indicated that presence of the ccj is related to ageing. All these data suggest that ccj is not a condition related to traumatic sequelae, as postulated by Lane (1888).

The coracoclavicular joint has been considered, at various times, to be responsible for humeral head fracture (Frasseto, 1921), cervicobrachial syndrome (Del Valle & Giordano, 1943) and decrease in movement (Wertheimer, 1948; Hall, 1950). Ray (1959) and Nutter (1941), studying, respectively, skeletons and unselected roentgenograms of adult shoulders taken under various conditions, concluded that the significance of this joint was merely academic. Except for the case described by Possati (1926), of a 63-year-old workman who also sustained a shoulder injury on the same side of the ccj and who underwent AC degenerative changes, no other authors have reported on degenerative effect of ccj on neighbouring joints. Furthermore, DePalma (1973), who studied the osteological causes of AC arthritic changes (AC articular facet orientated downwards and inwards; small lateral clavicular facet), did not consider ccj to be a risk factor, although Kier et al. (1986) did, summarizing the causes that predispose to SC degenerative changes (systemic diseases or trauma). In our sample, six of the seven clavicles with ccj (all belonging to the age group 41–60 years), and 64.4% ($P < 0.05$) of the 105 clavicles of the same age group without ccj, had arthritis of the AC joint. These data – despite the fact that the sample of clavicles with ccj is very small – suggest that ccj may predispose to AC degenerative changes; indeed, since AC arthritis distribution follows the binomial law (whose parameter we assume here to be 0.644 since 64.4% of the 105 clavicles had arthritis), the likelihood of there being – as in our case – at least six of seven clavicles with AC degenerative changes is less than one in four (probability = 0.22). Hence, since six of the seven clavicles with ccj, and 60.4% ($P < 0.05$) of the 105 clavicles of the same age group without ccj, had arthritis of the SC joint, the likelihood of having at least six clavicles out of seven with SC degenerative changes is less than one in six (probability = 0.16). We do not know why ccj may predispose neighbouring joints to arthritic changes; nevertheless, it is plausible that the anomalous articulation plays a part in the stiffness of the AC and SC joints, reducing the capacity to absorb the different stresses applied on them.

At present, it is not completely clear whether the ccj undergoes arthritic changes. Hall (1950) suggested not only that joint degeneration is possible but also that, since the ccj is in very close proximity to the main trunk of the brachial plexus, degenerative deformation might be responsible for cervicobrachial syndrome. Cockshott (1979), however, revealed that ccj is subject to osteophytic marginal lipping but that degenerative changes are unable to develop symptoms or disability. None of our clavicles with ccj had signs of arthritis of the clavicular facet of the anomalous joint. Nevertheless, these specimens belonged to relatively young subjects; therefore, it is possible that development of ccj was a recent event, or that degenerative changes occur later.

Whether the morphometric characteristics of clavicle and scapula may condition ccj development is still a matter for discussion. Nalla & Asvat (1995), performing an osteological study on 240 skeletons, observed that individuals possessing ccj showed larger scapulae, longer first ribs and longer clavicles. These affirmations were completely neglected by Cho & Kang (1998) who, in their study of 102 cadavers, stated that occurrence of ccj is not related to the size of the scapulae, clavicle length or to the slope and heights of some coracoacromial arch elements. We have studied the possible relationship among ccj, clavicle length and index of sinuosity of the anterior lateral curve. The latter conditions the spatial disposition of the conoid tubercle (where ccj is located) and, consequently, the distance between it and the coracoid process. We observed no statistically significant differences between the mean length and the mean index of sinuosity of the anterior lateral curve of clavicles with and without ccj.

© Anatomical Society of Great Britain and Ireland 2002

Therefore, our data suggest that neither parameter studied is related to the development of ccj.

References

Abe K (1964) On the coracoclavicular joint and its incidence. *Acta Anat Nippon*. **39**, 227–231.

Bainbridge D, Tarazaga SG (1956) A study of the sex differences in the scapula. *J. R. Anthropol. Inst*. **86**, 109–134.

Bennett EH (1873) Congenital malformations of the clavicle. *Dublin J. Med. Sci*. **56**, 413–414.

Cho BP, Kang HS (1998) Articular facets of the coracoclavicular joint in Koreans. *Acta Anat*. **163**, 56–62.

Cockshott WP (1963) Carpal fusions. *AJR*. **89**, 1260–1271.

Cockshott WP (1979) The coracoclavicular joint. *AJR*. **131**, 313–316.

Cockshott WP (1992) The geography of coracoclavicular joints. *Skeletal Radiol*. **21**, 225–227.

Del Valle D, Giordano A (1943) Sindrome doloroso cervico-brachial originado por articulacion coracoclavicular. Operacion-curacion. *Rev. Argentino-Norteamericana Cien Med*. **1**, 687–693.

DePalma AF (1973) Normal regional and variational anatomy of the shoulder. In *Surgery of the Shoulder*, 2nd edn. Philadelphia: JB Lippincott Company, 42–48.

Fischer L, Vuillard P, Blanc JF, Bouchet A (1971) L'articulation coraco-claviculaire. *Lyon Med*. **225**, 1257–1260.

Frasseto F (1921) Tre casi di articolazione coraco-clavicolare osservati radiograficamente sul vivente. *Chir. Org. Mov*. **5**, 116–124.

Giongo F (1927) Un caso di articolazione coraco-clavicolare bilaterale. *Radiologia Med*. **14**, 186–191.

Gradoyevitch B (1939) Coracoclavicular joint. *J. Bone J. Surg*. **21**, 918–920.

Gruber WL (1861) Die Oberschulterhakenschleimbeutel (bursae mucosae, supracoracoideae) Eine Monographie mit Vorbemerkungen enthaltend: Beitrage zur Anatomie der Regio infraclavicularis und deltoidea. *Mém. Acad. Imp. Sci. St Pétersbourg*. **3**, 11 (Series 7).

Hall FJS (1950) Coracoclavicular joint; rare condition treated successfully by operation. *Br. Med. J*. **1**, 766–768.

Haramati N, Cook RA, Raphael B, McNamara TS, Staron RB (1994) Coraco-clavicular joint: normal variant in humans. A radiographic demonstration in the human and non-human primate. *Skeletal Radiol*. **23**, 117–119.

Kaur H, Jit I (1991) Brief communication: Coracoclavicular joint in Northwest indians. *Am. J. Phys. Anthropol*. **85**, 457–460.

Kier R, Wain SL, Apple J, MartineZ. S (1986) Osteoarthritis of the sternoclavicular joint. Radiographic features and pathologic correlation. *Invest. Radiol*. **21**, 227–233.

Lane WA (1888) The anatomy and physiology of the shoemaker. *J. Anat.* 22, 593–628.

Lewis OJ (1959) The coracoclavicular joint. *J. Anat*. **93**, 296–303.

Nalla S, Asvat R (1995) Incidence of the coracoclavicular joint in south african populations. *J. Anat*. **186**, 645–649.

Nutter PD (1941) Coracoclavicular articulations. *J. Bone Joint Surg*. **23**, 177–179.

Pillay VK (1967) The coracoclavicular joint. *Singapore Med. J*. **8**, 207–213.

Poirier P (1890) La clavicule et ses articulations. *Journal l'Anatomie (Paris)*. **26**, 81–103.

Possati A (1926) Un caso di articolazione coraco-clavicolare osservato radiograficamente. *Chir. Org. Mov*. **10**, 533–536.

Ray LJ (1959) Bilateral coraco-clavicular articulation in the Australian aboriginal. *J. Bone Joint Surg. (Br.)* 41-B, 180–184.

Slocum DB (1941) Coracoclavicular joint. *Northwest Med*. **40**, 16.

Wertheimer LG (1948) Coracoclavicular joint. Surgical treatment of a painfull syndrome caused by an anomalous joint. *J. Bone Joint Surg. (a)*. **30-A**, 570–578.

© Anatomical Society of Great Britain and Ireland 2002