Environmental Health Perspectives
Vol. 85, pp. 187–208, 1990

Normal Histology of the Nasal Cavity and Application of Special Techniques

by Linda C. Uraih*† and R. R. Maronpot*

There are three major epithelial types in the nasal mucosa, in addition to numerous accessory structures, some of which are species specific. Without careful and consistent processing of the nose tissue, histopathologic assessment of lesions in the nasal cavity may be compromised. While formalin fixation may be used for routine review of the nasal cavity, Bouin's fixation provides better histologic detail and fewer artifacts. Decalcification is not recommended for nasal tissues to be examined by transmission electron microscopy because of the detrimental effect of decalcifying solutions on sensory cells. Three levels of the nasal cavity may be used for routine histologic review of the nasal cavity, but four or five levels may be more appropriate for certain studies.

Introduction

Many of earlier rodent toxicity and carcinogenicity studies did not routinely examine the nasal cavity. More recently, studies performed by the National Toxicology Program or other institutes in which animals were exposed either parenterally (*1*) or via inhalation (*2*) highlighted the importance of the nasal cavity as a potential target organ. However, the integrity of some of these studies was challenged when the nasal cavity, although suspected, could not be verified as the primary site of tumor development for metastatic lesions found in the brains of affected animals, due simply to failure to collect the nasal tissues. In addition, some epithelial types in the nasal cavity have been shown to exhibit susceptibility to certain gases or chemicals (*3–5*) that could account for the site specificity of the lesions induced. These observations indicate the need for histologic review of nasal tissues for toxicity and carcinogenicity studies and consistency in sectioning and properly documenting the nature and distribution of nasal lesions. The anatomical complexity of the nose, however, may present a challenge to workers that are not routinely engaged in reviewing this organ. Accurate assessment of pathological findings or recognition of site-specific changes cannot be achieved unless there is thorough knowledge of the normal microanatomy of the nasal cavity. Inconsistency in trimming nasal tissues could further complicate the task.

This paper reviews the normal microscopic anatomy of the nasal cavity. For an in-depth review, however, the reader is referred to any histology texts, or to references cited in this paper. A procedure for sample collection of rodent nasal cavity for light microscopy has been published (*6*) and will be used with several modifications as a guide for examining the normal histology of the nose. A comparative review of histologic preparation of the nasal cavity using 10% neutral buffered formalin, Bouin's, Zenker's, or Fowler's fixatives, in addition to two decalcification solutions and two embedding media, will be presented. Recommendations for preparing the nasal cavity for transmission electron microscopy requested are also discussed.

Materials and Methods

Thirty-four male F344 rats, 12 to 14 weeks of age, were obtained from Charles River Breeding Laboratory (Kingston, NY). Rats were housed three per cage and allowed *ad libitum* access to NIH 31 diet (Ziegler Brothers, Gardners, PA). All animals had unrestricted access to filtered tap water. The rats were euthanized by overdosing with sodium pentobarbital and exsanguination. The heads were removed and the lower jaw discarded. Thirty-two rats were used to review techniques for light microscopy and two were used to demonstrate procedures for transmission electron microscopy.

Fixation, Decalcification, and Trimming for Light Microscopy

The nasal cavities from groups of eight rats were flushed with 10% neutral buffered formalin (NBF), Bouin's, Zenker's or Fowler's (a glutaraldehyde-paraformalde-

*National Toxicology Program, National Institute of Environmental Health Sciences, P.O. Box 12233, Research Triangle Park, NC 27709.
†Present address: Pfizer Central Research, Bldg. 174, Eastern Point Rd., Gordon, CT 06340.
Address reprint requests to R. R. Maronpot, National Institute of Environmental Health Sciences, P. O. Box 12233, Research Triangle Park, NC 27709.

hyde preparation) solutions (*7*) formulated to standard composition (*8,9*). The flushing was accomplished via a gavage needle, attached to a 20 mL syringe, inserted 2 to 3 mm into the posterior opening of the nasopharynx in the roof of the oral cavity.

Excess skin, muscle, and other soft tissues were removed from the skulls. They were subsequently immersed in their respective fresh fixative, and agitated for 24 hr. Heads placed in Bouin's solution were fixed for 24 hr, rinsed in 50% ethanol until clear, and then stored in 70% ethanol. Heads in Zenker's solution were fixed for 24 hr, subsequently washed in running tap water for 24 hr, and stored in 70% alcohol.

Following fixation, heads were rinsed in running tap water for 4 hr and decalcified in either a commercially available decalcifying reagent prepared by S/P American Scientific Products (Div. of American Hospital Supply Corp., McGaw Park, IL) (Decal 1) or a resin-formic acid solution (Decal 2) formulated to standard composition (*8*). The heads were placed in teabags and identified by fixative, decal solution, and an arbitrary number. Heads placed in Decal 1 were left for approximately 7 hr, held in running tap water overnight and replaced in Decal 1 the next day for 10 to 12 hr to complete decalcification. Heads in Decal 2 were suspended in the solution to prevent resin particles from embedding in tissues; these heads took 2 to 3 days to decalcify. Rat heads were then rinsed in running water for 4 hr in preparation for trimming.

The upper incisor teeth, incisive papilla, first palatal ridge, second palatal ridge, first upper molar teeth, and posterior opening of the nasopharyngeal duct (Fig. 1) were used as guides for trimming nasal tissues (*6*). It is important to hold the trimming scapel firmly to make good transaxial slices perpendicular to the plane of the hard palate. The National Toxicology Program routinely samples three levels (levels I, II, III) of the nose for light microscopy in their toxicity and carcinogenicity studies. The three slices permit review of all epithelial cell types. The present procedure yields four nasal slices (levels I, II, III, and IV) to review the majority of internal accessory structures, in addition to the various epithelial cell types. Following trimming, head slices were returned to their respective fixatives and remaining tissue was stored.

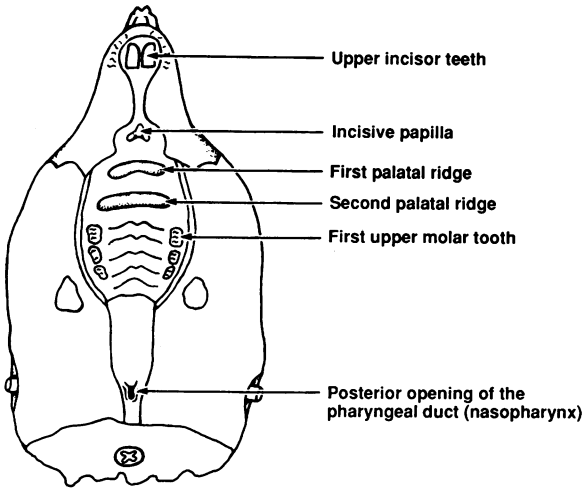

FIGURE 1. Ventral view of the rat hard palate region. Landmarks used as guide for trimming nasal tissues are upper incisor teeth, incisive papilla, first palatal ridge, second palatal ridge, first upper molar teeth, and posterior opening of the nasopharyneal duct.

Rat heads were embedded in paraffin (Paraplast, obtained through Fisher Scientific Products, Pittsburgh, PA) after dehydration through graded alcohols or embedded in glycol methacrylate (GMA) following processing to 95% alcohol according to instructions from the Sorvall Instruction Manual (Bio-Rad Embedding Medium, Polaron Instrument, Cambridge, MA). All blocks were cut at 5 μm (paraffin) or 3 μm (GMA). Slides from Zenker's fixed tissues were rinsed in 0.5% sodium iodide solution for 10 min and cleared in 5% sodium thiosulfate solution for 5 min before staining with hematoxylin and eosin. The GMA-embedded tissues were stained according to methods described by Castro (*10*). A summary of the methods for the comparative histologic review of rat heads for light microscopy is presented in Table 1.

Fixation and Trimming for Transmission Electron Microscopy

The nasal cavities of two rats were fixed by infusing Fowler's fixative (*7*) into the posterior nasopharynx as previously described. The heads were then held in 50 mL of fixative at 4°C for not less than 24 hr. After proper fixation and using palatine structures as references, three transverse sections of the skull were made by using a Buehler's isomet low-speed saw (Buehler LTD., Lake Bluff, IL). Decalcification of the skull was not required.

For transmission electron microscopy (TEM) three levels (level I, II, and IV) of the nasal cavity were taken to review the major epithelia types — respiratory and olfactory epithelia. The following levels were taken: level I through the incisive papilla anterior to the first palatal ridge, level II at the second palatal ridge, and level IV at the level of the first upper molar tooth. The head sections were subsequently rinsed with and placed in 0.2 M phosphate buffer (4°C). After 24 hr, samples of the nasal mucosa were collected from each animal by microdissection with the aid of a dissecting microscope, fine tip forceps, and No. 15 surgical steel scalpel blades (Bard-Parker, Becton-Dickinson and Co., Rutherford,

Table 1. Summary of preparative methods for rat nasal cavity.

	Embedding media			
	Paraffin		GMA	
fixatives	Decal 1[a]	Decal 2[a]	Decal 1	Decal 2
10% NBF	2[b]	2	2	2
Bouin's	2	2	2	2
Zenker's	2	2	2	2
Fowler's	2	2	2	2

[a]Decal 1 = S/P American Scientific Products Decalcifying solution. Decal 2 = resin-formic acid solution.
[b]Number of rat heads in each preparation.

NJ). At levels I and II, samples were taken of the respiratory epithelium from the nasal septum and lateral aspects of the naso- and maxilloturbinates. At level IV, samples were taken from the olfactory epithelium of the nasal septum, dorsal meatus, and ethmoid turbinates. Tissue samples were placed in fresh phosphate buffer overnight, postfixed in 1% osmium tetroxide in 0.1 M phosphate buffer for 2 hr, dehydrated through graded concentrations of ethanol, infiltrated, and embedded in Epon. Semithin sections (0.5–1 μm) were cut on a Sorvall MT-1 ultramicrotome (DuPont Company, Newton, CT) and stained with toluidine blue for light microscopic evaluation. Ultrathin sections, stained in an LKB ultrastainer (LKB Instruments, Gaithersburg, MD) using 0.5% uranyl acetate and 2.7% lead citrate, were examined in a Philips 400 transmission electron microscope (Philips Electronic Instrument, Inc., Mahwah, NJ).

Results and Discussion

Preparative Method for Nasal Cavity — Light Microscopy

Parameters used to judge histologic quality included chromatin aggregation, cell shrinkage, loss of cell-to-cell contact, and tissue resolution by light microscopy. Decalcification solutions were reviewed, generally, with respect to decalcification time. It was determined that Bouin's, Zenker's, and 10% NBF fixatives, in that order, produced the fewest artifacts (Plate 1*A–D*), while Fowler's fixative was the least desirable for light microscopy. Although no observable difference was noted during microtomy between Decal 1 and Decal 2, the decalcification time for rat heads was shorter in Decal 1. In addition, heads fixed in Bouin's and Zenker's solution required shorter decalcification time than those fixed in 10% NBF or Fowler's fixative. There was more observable shrinkage of the total head sections (Plate 2*A,B*) after embedding in paraffin versus GMA. In addition, the resolution of tissue structure was substantially better for heads embedded in GMA. Overall, Bouin's fixative combined with Decal 1 and GMA embedding was most desirable for light microscopy of the nasal cavity. However, for handling large volumes of tissues where time is crucial and technical assistance limited, 10% NBF and paraffin embedding is recommended.

Preparative Method for Nasal Cavity — Transmission Electron Microscopy

Immersion fixation rather than whole body perfusion for TEM of the nasal cavity is recommended. After flushing the nasal cavity, immediate immersion of the tissues in Fowler's fixative (*7*) helps to maintain cell-to-cell contact and eliminates artifacts such as cytoplasmic vacuolation that may interfere with evaluation of fine structures. To prevent the harsh effects of decalcification on neurons or other sensitive tissues, we recommend sectioning the skulls on a low-speed saw instead of decalcifying the heads before trimming. This approach has been extended to other studies in our laboratory and found to give excellent results (unpublished observations).

Review of Normal Histologic Anatomy of Nasal Cavity

Consistency in trimming nasal tissues is essential to accurately document pathological changes. Prominent landmarks (Fig. 1) are used as guides for maintaining this consistency. Modifications may be made with respect to the number of levels trimmed. Where detailed study of nasal tissues is required, microscopic examination of four levels of the nose is recommended.

Level I. The first level of examination is immediately posterior to the upper incisor teeth (Fig. 2). The roots of the teeth are shown laterally. The nasal cavity is divided sagittally into equal halves by the nasal septum, which is supported by a plate of hyaline cartilage. The cavities contain a dorsal meatus that extends into the dorsal part of the ethmoid recess, a middle meatus that terminates at the maxillary sinus, and a ventral meatus that extends along the floor of the nasal cavity and terminates at the nasopharyngeal duct. The naso- and maxilloturbinates have a hooklike shape.

At this level, approximately 90% of the nasal cavity is lined by respiratory epithelium and 10% by mildly keratinized stratified squamous epithelium that lines the vestibule and ventral meatus. The squamous epithelium consists of five to six layers of flattened cells similar to stratified squamous epithelium lining other mucosal surfaces (Plate 3). The fibrovascular lamina propria, in contrast to that in humans, is devoid of sebaceous glands and hair follicles.

Respiratory epithelium covering the septum, dorsal meatus, and turbinates varies not only in height, but also in its population and distribution of cell types. The epithelium on the tips of the naso- and maxilloturbinates is low cuboidal and sparsely ciliated (Plate 4). The tip of the turbinates is one of the first areas where mild squamous metaplasia may be seen, and care should be taken to not misinterpret the low cuboidal epithelium as squamous metaplasia. Basically, however, the respiratory mucosa is covered by a ciliated pseudostratified columnar epithelium (*11–13*). A typical section taken from the septum or medial aspect of the turbinates has a preponderance of ciliated columnar and goblet cells (Plate 5). In general, there are no unique ultrastructural features in these cells aside from the cilia and large secretory granules (Plate 6). The basal cells, which lie on the basal lamina but do not reach the lumen, represent a third cell type. A section taken from the anterior lateral aspect of the maxilloturbinate shows three additional cell types: a nonciliated columnar with a microvillous border, cuboidal, and brush (Fig. 3) (*14,15*). Brush cells are pear shaped, have dense microvilli, and are usually found between noncilated columnar cells.

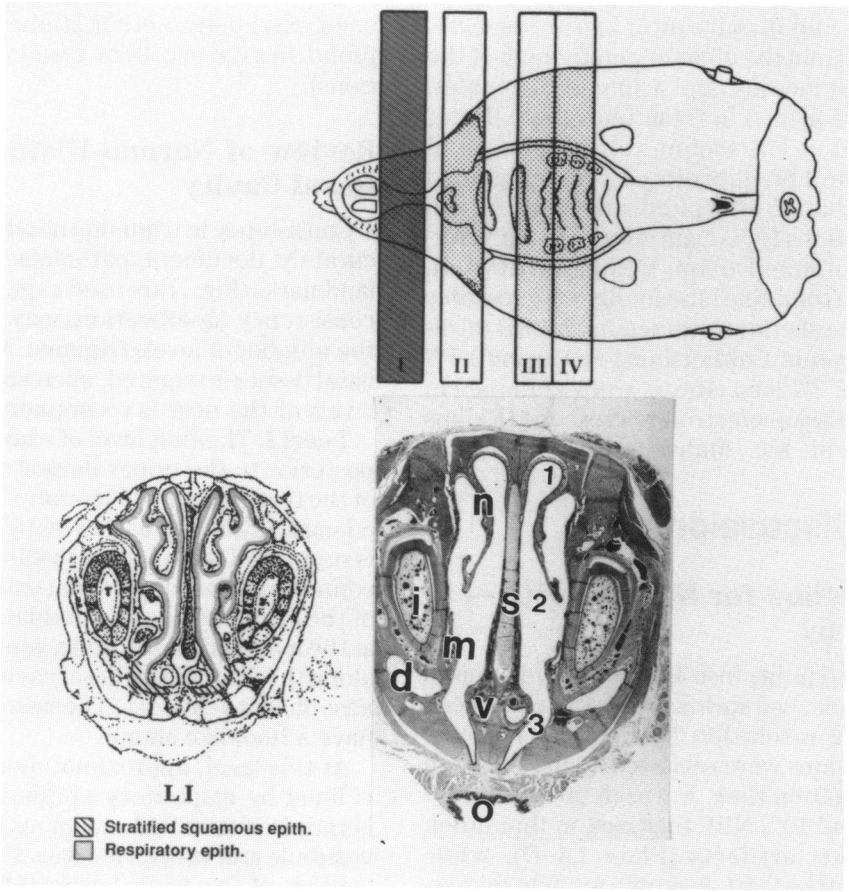

FIGURE 2. This section of the rat nasal cavity is posterior to the upper incisor teeth. (1) Dorsal meatus, (2) middle meatus, (3) ventral meatus, (d) nasolacrimal duct, (n) nasoturbinate, (m) maxilloturbinate, (s) septum, and (v) vomeronasal organ. Drawing of Level I shows respiratory epithelium and stratified squamous epithelium covering the nasal mucosa.

They have many long mitochondria, microfilaments and vesicles.

The paired vomeronasal organs (Jacobson's organ), nasolacrimal ducts, and septal glands are present in level I. The vomeronasal organs (VO) are paired tubular diverticula that open laterally into the vestibule via a duct. (*16*). Their precise function is unknown but is believed to be associated with pheromonal recognition and food flavor perception (*17*). The ablation of the VO in hamsters resulted in loss of mating behavior (*18*). The VO are lined by ciliated columnar epithelium on one side and olfactory bipolar neurons and sustentacular cells on the opposite wall (Fig. 4). The olfactory neurons do not possess cilia, and there are no basal cells lining the basal lamina, as in the olfactory epithelium covering the posterior regions of the nasal cavity. Replacement cells for the VO neurons are displaced from the two edges of the olfactory epithelium where this area interfaces with the columnar epithelium. The axons form the vomeronasal nerve and connect to accessory olfactory bulbs located on either side of the olfactory bulb proper (*16*). The VO rotates in the canal of the vomer bone so that at level I the VO appears in a c-shape position, and at level II it is a cup-shape (Plate 7*A,B*). Neutrophils are normally seen emigrating through the columnar epithelium.

The paired nasolacrimal ducts originate from the lacrimal apparatus that is formed by the infra- and extraorbital lacrimal glands (*19*). The lacrimal ducts originate as openings in the dorsal conjunctival sacs and fuse to form the nasolacrimal duct and pass through the nasolacrimal canal. The nasolacrimal duct terminates in the ventromedial wall of the nasal vestibule.

Stratified squamous epithelium is normally found at the origin and termination of the nasolacrimal duct. Elsewhere, the duct is lined by pseudostratified nonciliated columnar epithelium (Plate 8). However, squamous metaplasia of the columnar epithelium is so frequently observed that many workers regard it as normal. Plate 9 shows patches of stratified squamous epithelial cells among columnar type epithelial cells. Stratified squam-

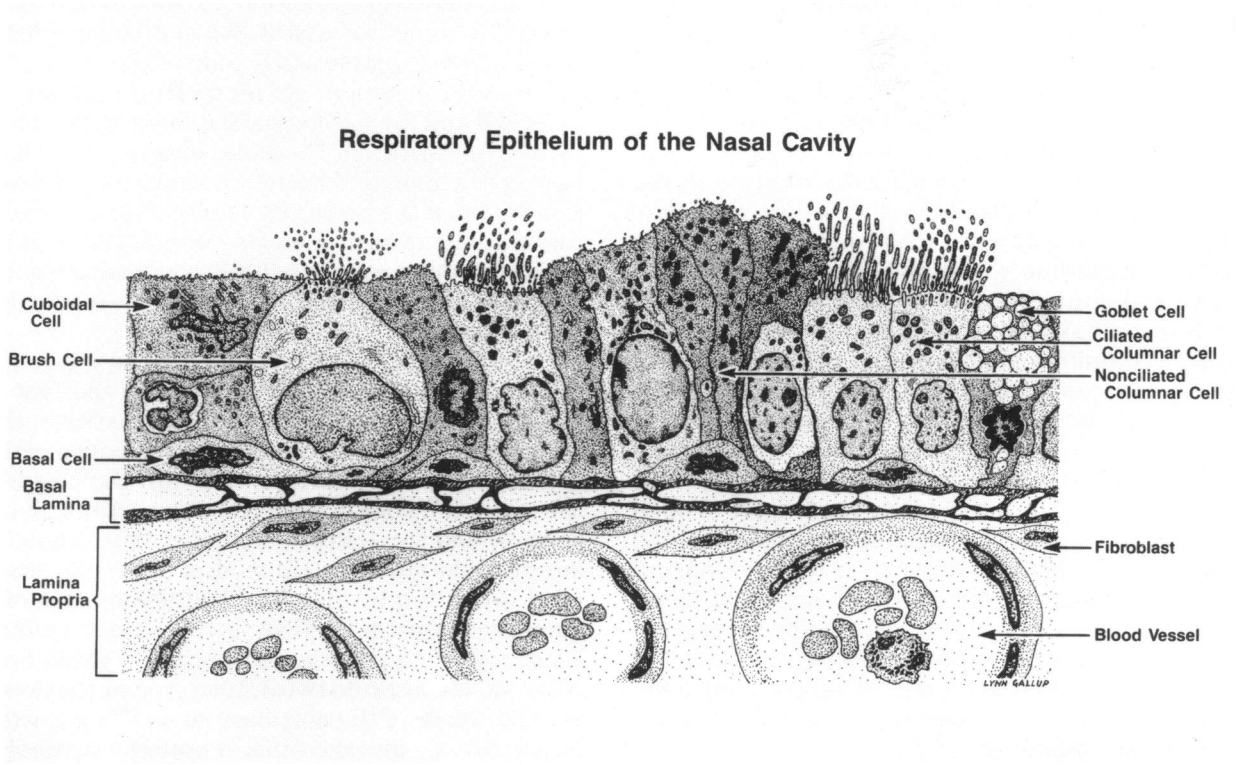

FIGURE 3. Schematic drawing of anterio-lateral aspect of maxilloturbinate shows six morphological cell types.

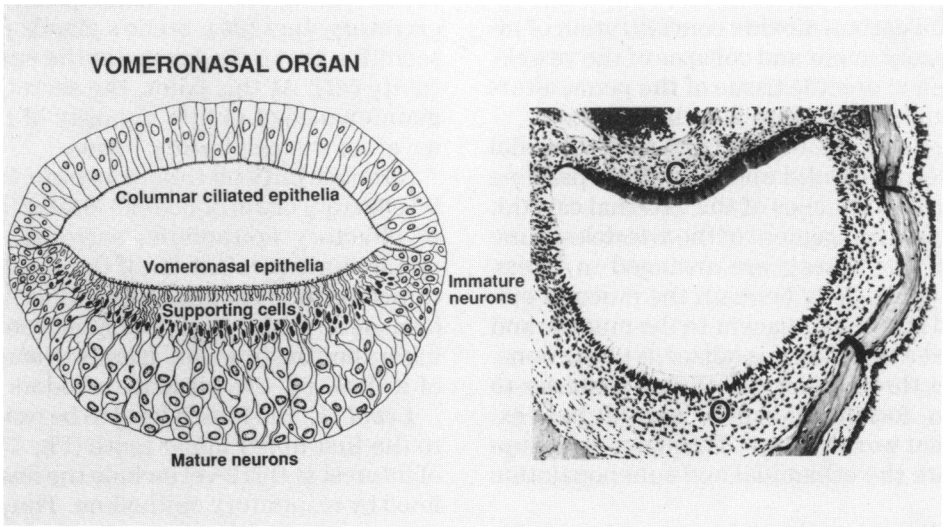

FIGURE 4. Vomeronasal organ of the rat nasal cavity is covered by ciliated columnar epithelium (C) on one side and nonciliated olfactory epithelium (O) on the opposite side. The schematic drawing shows immature cells which give rise to mature neurons at the junction of the columnar and olfactory epithelia.

ous epithelium at this level represents a metaplastic change resulting from irritation associated with infectious agents or exposure to irritants in the environment. Age-related metaplasia should also be considered.

The nasal fluid is composed of secretory products originating from nasal glands, lacrimal duct, and transudation across blood vessels. The respiratory part of the nasal passage is equipped with a particularly complex system of glands. These glands produce a variety of secretory products that may assist in protection of the lower airways, through their role in the humidification of inspired air and through provision of a functioning mucociliary transport system to clean and protect the nose.

In level I, the anterior and posterior glands of the nasal septum are prominent (Plate 10). The anterior glands of the nasal septum are of the tubulo-alveolar type; their secretory cells have round, basally located nuclei and finely granular cytoplasm, and they produce a serous secretion (*20–22*). The ducts extend anteriorly to open into the nasal vestibule. The posterior glands are of the branched acinar type. They lie partly within the vomeronasal capsule. Their secretory cells have spherical, basally located nuclei and granular, basophilic cytoplasm. Most of the ducts of the posterior glands open into the cavity of the vomeronasal organ along the groove between the olfactory and columnar epithelia of the VO. Their secretion is mucoid (*23,24*).

Prominent venous sinuses commonly referred to as swell bodies (Kiesselbach's plexus in humans) are found in level I (Plate 11) (*25*). The latter are often the source of excessive nose bleeds in humans. The largest swell bodies are located in the lateral wall between the naso- and maxilloturbinates, and smaller ones, in the maxilloturbinates and septum extending into the VO. The distension of this venous tissue varies with the temperature, humidity, and carbon dioxide concentration of inspired air (*26*). Engorgement and collapse of the vessels, similar to that seen in erectile tissue of the penis, alters the air flow through the nose in a cyclical manner.

The arterial supply to the nose is from the ethmoidal branch of the internal carotid and the sphenopalatine and anterior palatine branches of the external carotid. There is a functional arrangement of the arterioles in the nasal cavity (*25*). The vessels are arranged in layers, beginning most superficially beneath the mucosal epithelium; a second layer lies adjacent to the mucous and serous glands; and a third layer is adjacent to the bone. The blood courses through the vessels in a posterior to anterior direction, forming a counter current heat exchanger system that warms the air. The major veins supplying the nose are the ethmoidal and sphenopalatine (*25*).

Level II. Level II is taken through the incisive papilla (Fig. 5). At this level bilateral communication with the oral cavity via the incisive ducts can be seen. The ducts are lined by stratified squamous epithelium, and occlusion by inflammatory exudate or foreign bodies such as hair shafts or plant fibers may occasionally be seen. The precise function of the incisive ducts is not known. The communication between the nasal and oral cavities, however, may serve as a route for mucus flow from the nose to the mouth, as well as allowing for immediate food flavor perception through the aid of the sense of smell. The roots of the upper incisor teeth are still prominent at level II and the nasolacrimal ducts are seen lateral to the teeth at this level. The dorsal meatus is lined by olfactory epithelium, and there is a sharp line of demarcation between the respiratory epithelium and the olfactory epithelium on the dorsal septum at this level. Recognizing this demarcation will aid in assessing respiratory metaplasia of the olfactory epithelium commonly seen in this location.

Level III. The third level for examination is through the second palatal ridge and includes the first upper molars (Fig. 6). Important internal landmarks are the septal window that allows communication between the two halves of the nasal cavity and is also the beginning of the nasopharyngeal duct (*27*); the paired maxillary sinuses; and the nasolacrimal duct that is now dorsolateral to the maxillary sinus. Most of the mucosa at this level is covered by olfactory epithelium, whereas the maxillary sinus is lined by a respiratory epithelium. Glands situated in the lamina propria of the lateral wall of the sinus constitute two distinct groups: the dorsal and ventral glands of the maxillary sinus. Their ducts open either directly into the sinus or onto the vestibule (*28*). These glands produce serous and mucous secretions.

The lateral nasal glands, Steno's glands, form a prominent group on the lateral wall ventral to the maxillary sinus and extend deeply into the connective tissue of the lateral wall. Their cytological features are similar to serous salivary glands (*29*). The duct system is well developed and consists of intercalated and branched striated ducts (Plate 12). These ducts drain into one major excretory duct (*30*). Steno's glands produce a mucous secretion that is discharged at the entrance of the nasal cavity (*31*). At this point, the secretion contributes to maintenance of proper viscosity of the mucus blanket covering the respiratory region.

Although difficult to demonstrate, Masera's organ (septal olfactory organ of Rodolfo Masera) is an isolated patch of olfactory epithelium, surrounded by respiratory epithelium near the base of the nasal septum at the entrance of the nasopharyngeal duct. The structure has been described as part of a chemosensitive system serving an alerting function. It is also thought to be a monitor of airflow for the presence of odors (*32,33*).

Level IV. The fourth level to be examined is posterior to the first upper molar tooth (Fig. 7). Internal feature of interest at this level include the nasopharyngeal duct lined by respiratory epithelium. The prominent lymphoid tissue in the lamina propria on either side of the duct consists of follicular structures and is covered by lymphoepithelium. This lymphoepithelium contains membranous cells or M cells. The lymphoid structures contain T-cell and B-cell areas and are akin to gut- and bronchus-associated lymphoid tissue (GALT and BALT, respectively). A designation of nose associated lymph-

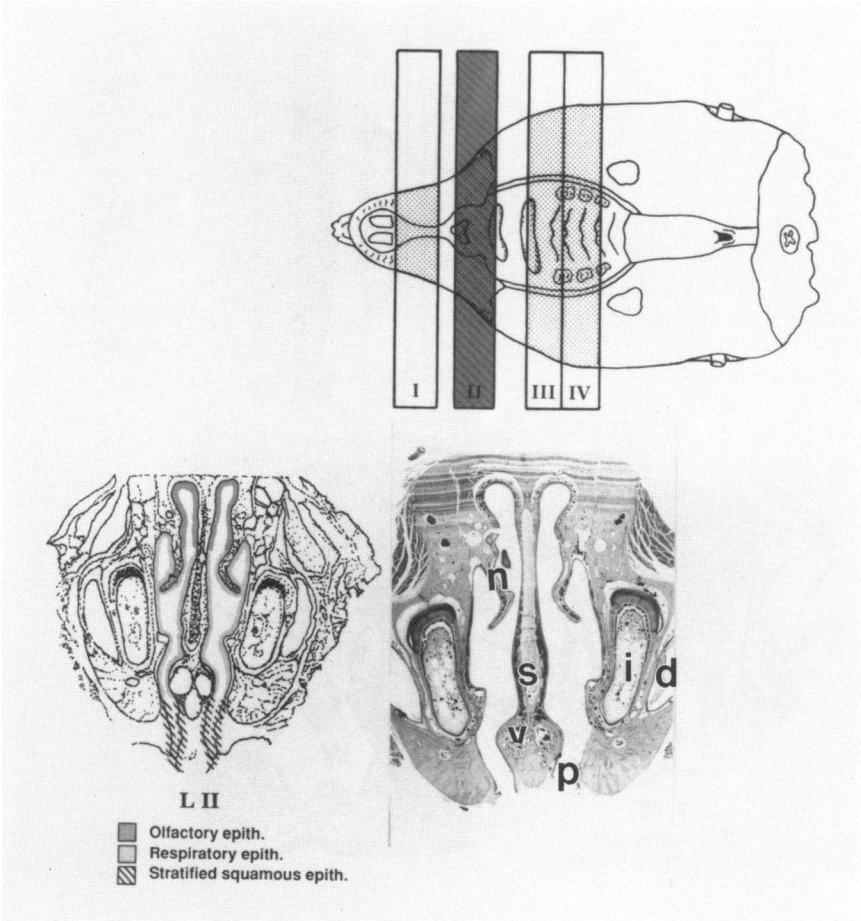

FIGURE 5. Level II of the rat nasal cavity is taken at the incisive papilla (p). (n) Nasoturbinate, (s) septum, (i) root of the incisor tooth, (d) nasolacrimal duct, and (v) vomeronasal organ. Line drawing shows three epithelial cell types: olfactory, respiratory, and stratified squamous.

oid tissue (NALT) has been proposed. It has also been considered to be the homolog of the human tonsil (*15*).

The complex system of ethmoid turbinates located at level IV includes endo- and ectoturbinates. Except for small areas of respiratory epithelium on the lateral aspects of some ectoturbinates and the lateral wall, the epithelium in this region is entirely olfactory. This ciliated pseudostratified columnar epithelium is composed of three major cell types: supporting cells (sustentacular), olfactory neurons, and basal cells (Plate 13) (*11–13*).

Basal cells are located in the lower third of the olfactory epithelium along the epithelial side of the basal lamina. The cells are flattened to ovoid and elongated. By TEM they have an electron-dense nucleus and prominent intermediate filaments but are otherwise morphologically similar to basal cells of the respiratory epithelium (Fig. 8, Plate 14). The cell body of basal cells can often be seen wrapped around or cuffing bundles of axons just above the basal lamina.

The supporting cells have large ovoid to round vesicular nuclei that form a distinct layer in the upper third of the olfactory epithelium (Plate 13). By TEM the supporting cell is tall and columnar with branching microvilli on the apical border and distal attachments to the basal lamina (Fig. 8, Plate 14). The nuclei are euchromatic. Fine structures seen in the cytoplasm include moderate numbers of mitochondria, electron dense pigment, and smooth endoplasmic reticulum.

The olfactory neurons are present as a layer approximately five to six cells thick and are distributed between supporting cells (Plate 13, Fig. 8). The nuclei are prominent throughout the middle third of the epithelium. Ultrastructurally (Fig. 8, Plate 14), the olfactory neuron has a cell body with a round, electron dense nucleus. A long dendrite arising from the apex of sensory neurons extends to the epithelial surface and ends in a bulbous enlargement, the olfactory vesicle, that rises above the apical surface. Moderately long, nonmotile cilia radiate from basal bodies in the apical cytoplasm of the olfactory vesicles (Plate 15). These cilia are believed to act as receptive elements for a variety of odors (*9,11,12,16,34*). The basal end of each sensory cell tapers

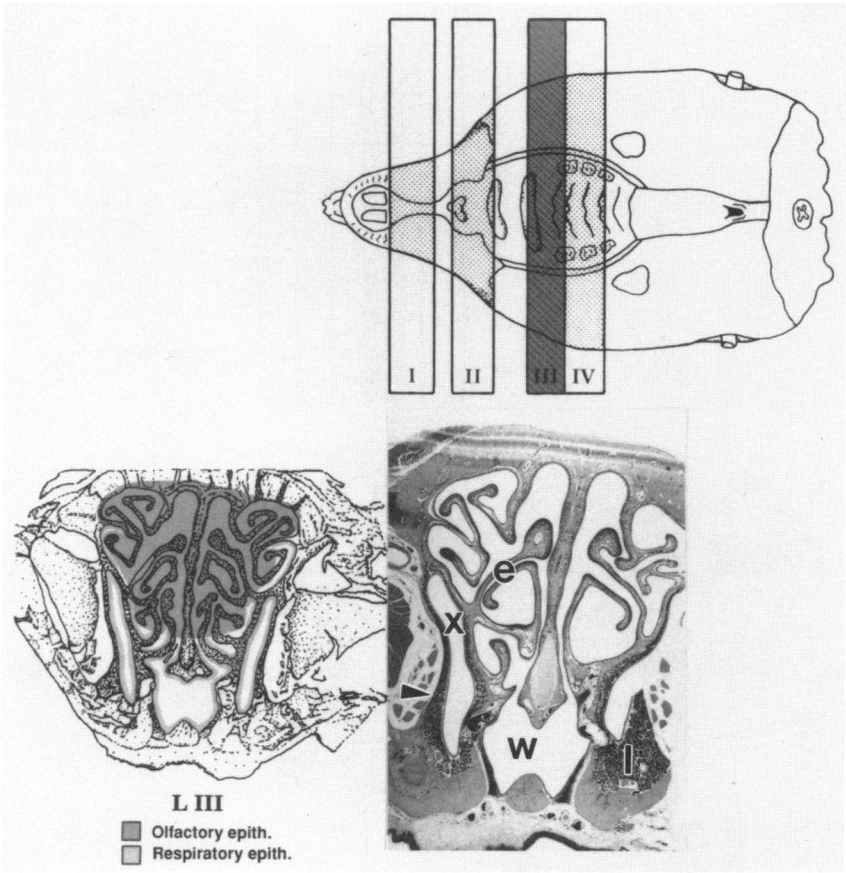

FIGURE 6. Level III of the rat nasal cavity is taken at the level of the second palatal ridge and features the ethmoid recess, (e) ethmoid turbinates, (1) lateral nasal (Steno's) gland, (w) septal window, (x) maxillary sinus and (arrow), and glands of the maxillary sinus. Line drawing of this level shows two epithelial types, olfactory and respiratory.

to a slender axon that passes through the basal lamina and into the lamina propria. Here the axons collect into small bundles to form a glomerulus, the fila olfactoria, which then passes through fine canals of the cribriform plate of the ethmoid bone to synapse with second order neurons in the olfactory bulb.

Although it is not the purpose of this paper to discuss in great detail the physiology of smell, some mention of present-day theories of that mechanism may be appropriate. It is thought that molecules of odorous substances that reach the cilia trigger nerve impulses in the receptor cells (olfactory neurons). Nerve impulses from the olfactory mucosa travel in the nerve fibers that pass through openings in the ethmoid bone and enter the cranial cavity. Here, the fibers join to form the paired olfactory bulbs and tracts of the first cranial nerve, which terminate in the frontal lobe of the brain. Each tract divides into medial and lateral striae, which transmit the information to the olfactory cortex, where smell is perceived (*34*). Recent evidence suggests that some odors are recognized subliminally—that is without our being consciously aware of their effect on our behavior. This is a well-recognized phenomenon in rodents and other lower forms of animals. Certain chemicals known as pheromones are secreted as sexual attractants. The VO, discussed earlier, is thought to play a major role in this function. Although the VO is not present postnatally in man, it is has been suggested that there are human pheromones that subconsciously influence sexual instincts and behavior (*34*).

Compared to lower forms of animals, man has a relatively poorly developed sense of smell. It has been further proposed that there are seven primary odors that exist and a combination of these gives rise to all other smells. One classification suggests that the seven primary odors are camphoraceous, musky, floral, pepperminty, ethereal, pungent, and putrid (*34,35*). Before a chemical can be smelled, however, it has to be volatile to diffuse

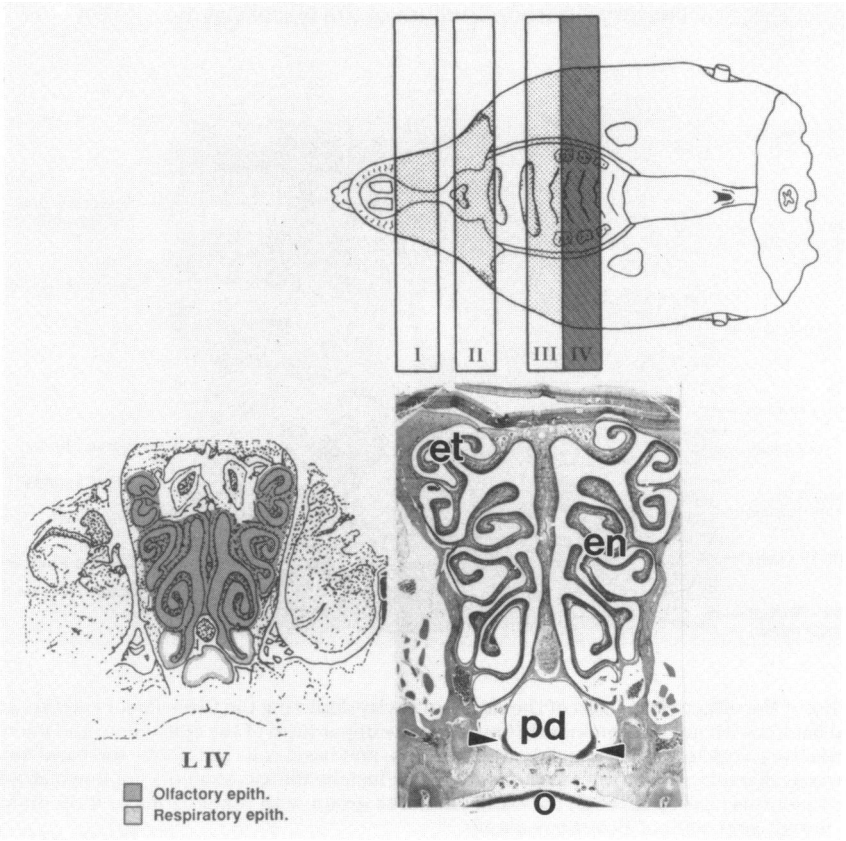

FIGURE 7. Level IV of the rat nasal cavity is taken at the level of the first and second molar teeth and into the posterior region of the ethmoid recess. The complex ethmoid turbinates are designated as endoturbinates (en) and ectoturbinates (ec). Lymphoid tissue (arrows) in the lamina propria of the nasopharyngeal duct (pd) may be a homolog of the human tonsil.

into the air, it should be slightly water-soluble to dissolve in the mucus that covers the olfactory epithelium, and it has to be fat-soluble to enter the cilia of the receptor cells (*33*).

One of the more interesting aspects of the study of the olfactory neurons is related to their recently proven ability to periodically replace themselves and to regenerate after injury. Olfactory cell renewal in rats is said to occur every 20 to 28 days. Other neurons of the mammalian nervous system do not undergo a continuous turnover and are not replaced when the cell body is destroyed. Although there has been general agreement that the basal cell is the stem cell for the olfactory neuron (*36–39*), there are conflicting views about the progenitor of the supporting cell.

The lamina propria in the ethmoid region of the nasal cavity contains many large unmyelinated nerve bundles from the olfactory nerve and simple tubulo-alveolar glands, Bowman's glands. Bowman's glands are found only in the lamina propria of the olfactory region. The ducts of these glands penetrate the basal lamina, pass through the olfactory epithelium, and open onto the mucosal surface. There is some controversy over whether these are serous or mucous glands, or both. Positive PAS stains indicate that they contain a neutral mucopolysaccharide product. Secretions of Bowman's glands function to moisten the surface of the olfactory epithelium and also serve as a solvent for odoriferous substances as previously described. Large secretory granules and laminated smooth endoplasmic reticulum are prominent ultrastructural features (Plate 16). Bowman's glands are also targeted by some nitrosamines, e.g., NNK, resulting in degeneration, necrosis, or neoplasia (*5*).

The technical assistance of Fred Talley, John Horton, and Mary Hicks is acknowledged. The author also thanks Kevin Morgan for his critical review of the manuscript and Marva Preatty for her secretarial assistance.

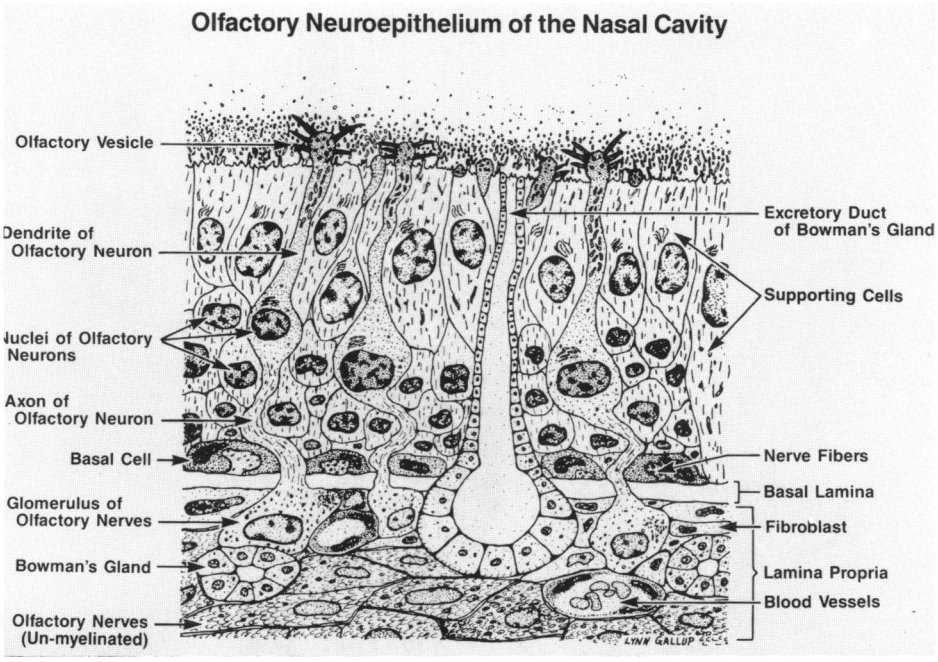

FIGURE 8. Schematic drawing of the olfactory mucosa of the rat nasal cavity depicting the three major cell types: tall, columnar supporting cells attached to the basal lamina with nuclei prominently located in the upper third of the epithelium and microvilli on the apical surface; olfactory neurons with olfactory vesicle, dendrite, cell body, and axon; and basal cells just above the basal lamina. The cytoplasm of the basal cell occasionally enwraps olfactory axons. Other features of interest include the excretory duct of Bowman's gland within the epithelium proper; axons of olfactory neurons passing through the basal lamina to group with other axons to form unmyelinated olfactory nerves (glomerulus of olfactory nerve); and acini of Bowman's glands.

REFERENCES

1. NTP. Toxicology and Carcinogenesis Studies of Dimethylvinyl Chloride (1-Chloro-2-Methylpropene) in F344/N Rats and B6C3F$_1$ Mice. Technical Report No. 316. National Toxicology Program, DHHS, Research Triangle Park, NC, 1988.
2. NTP. Toxicology and Carcinogenesis Studies of 1,2-Dibromo-3-Chloropropane in F344/N Rats and B6C3F$_1$ Mice. Technical Report No. 206. National Toxicology Program, DHHS, Research Triangle Park, NC, 1986.
3. Kerns, W. D., Pavkov, K. L., Donofrio, D. J., Gralla, E. J., and Swenberg, J. A. Carcinogenicity of formaldehyde in rats and mice after long-term inhalation exposure. Cancer Res. 43: 4382–4392 (1983).
4. NTP. Toxicology and Carcinogenesis Studies of Propylene Oxide in F344/N Rats and B6C3F$_1$ Mice. Technical Report No. 267. National Toxicology Program, DHHS, Research Triangle Park, NC, 1986.
5. Belinsky, S. A., Walker, V. E., Maronpot, R. R., Swenberg, J. A. and Anderson, M. W. Molecular dosimetry and DNA adduct formation and toxicity in rat nasal mucosa following exposure to the tobacco specific nitrosamine 4-(N-methyl-N-nitrosamino)-1-(3-pyridyl)-1-butanone and their relationship to induction of neoplasia. Cancer Res. 47: 6058–6065 (1987).
6. Young, J. T. Histopathologic examination of the rat nasal cavity. Fundam. Appl. Toxicol. 1:309–312 (1981).
7. Fowler, B. A., Kardish, R. M., and Woods, J. S. Alteration of hepatic microsomal structure and function by indium chloride. Lab. Invest. 48: 471–478 (1983).
8. Preece, A. A Manual for Histologic Technicians, 3rd edition. Little, Brown & Co., Boston, 1972.
9. Lillie, R. D., and Fullmer, H. M. Histopathologic Technic and Practical Histochemistry, 4th edition. McGraw-Hill, New York, 1976.
10. Castro, M. D., A hematoxylin-eosin phloxine stain for tissues embedded in glycol methacrylate. J. Histotechnol. 8: 23–24 (1985).
11. Leeson, T. S., and Leeson, C. R. The respiratory system. In: Histology (T. S. Leeson and C. R. Leeson, Eds.), W. B. Saunders Co., Philadelphia, PA, 1981, pp. 402–405.)
12. Bloom, W., Respiratory system. In: A Textbook of Histology (W. Bloom and D. Fawcett, Eds.), W. B. Saunders Co., Philadelphia, PA, 1975, pp. 743–746.
13. Rhodin, J.A.G. (Ed.). Histology: A Text and Atlas. Oxford University Press, New York, 1977, pp. 608–614.
14. Montiero-Riviere, N. A., and Popp, J. A. Ultrastructural characterization of the nasal respiratory epithelium in the rat. Am. J. Anat. 169: 31–43 (1984).
15. Spit, I. B. J., Hendriksen, J. P., Brujntjes, J. P., and Kuper, C. F. Electron microscopy of nasal brush cells and nose-associated lymphoid tissue (NALT). Toxicology Tribune 3: 3 (1988).
16. Sorokin, S. P. The respiratory system. In: Histology, Cell and Tissue Biology (L. Weiss, Ed.), Elsevier Biomedical, NY, 1977, pp. 796–797.
17. Negus, V. The Comparative Anatomy and Physiology of the Nose and Paranasal Sinuses. E. & S. Livingstone, Edinburgh, 1958.
18. Powers, J. B., and Winans, S. S. Vomeronasal organ: critical role in mediating sexual behavior of the male hamster. Science 187: 961–962 (1975).
19. Hebel, R., and Stromberg, M. W. (Eds.). Anatomy and Embroyology of the Laboratory Rat. The Williams & Wilkins Co., Baltimore, MD, 1986, p. 219.
20. Cuschieri, A., and Bannister, L. H. Some histochemical observations on the mucosubstances of the nasal glands of the

mouse. Histochem. J. 6: 543–558 (1974).
21. Kuijpers, W., Klaassen, A. B. M., Jap, P. H. K., and Tonnaer, E. Secretory characteristics of the rat nasal glands. Acta Otolaryngol. 95: 676–687 (1983).
22. Klaassen, A. B. M., Kiujpers, W., and Denuce, J. M., Morphological and histochemical aspects of the nasal glands in the rat. Anul. Anz. 149: 51–63 (1981).
23. Klaassen, A. B. M., Jap, P. H., and Kuijpers, W., Ultrastructural aspects of the nasal glands in the rat. Anat. Anz. 151: 455–466 (1982).
24. Tandler, B., and Bojsen-Moller, F. Ultrastructure of the anterior medial glands of the rat nasal septum. Anat. Rec. 191 (2): 147–151 (1978).
25. Ritter, F. The vasculature of the nose. Ann. Otol. Rhino. Larynogo. 79: 468–474 (1970).
26. Dawes, J. D. K., and Prichard, M. M. L. Studies of the vascular arrangement of the nose. J. Anat. 87: 311 (1953).
27. Kelemen, G. The junction of the nasal cavity and the pharyngeal tube in the rat. Arch. Otolaryngol. 45: 159–168 (1947).
28. Bojsen-Moller, F. Topography of the nasal glands in rats and some other mammals. Anat. Rec. 150: 11–24 (1964).
29. Warshawsky, H., Investigation of the lateral nasal glands of the rat. Anat. Rec. 147: 443–455 (1963).
30. Moe, H., and Bojsen-Moller, F. The fine structure of the lateral nasal gland (Steno's gland) of the rat. J. Ultrastruct. Res. 36: 127–148 (1971).
31. Vidi'c, B., Taylor, J. J., Rana, M. W., and Bhagat, B. D. The respiratory glandular system in the rat's lateral nasal wall in normal and polluted environments. Verh. Anat. Ges. 66: 83–85 (1971).
32. Marshall, D. A., and Maruniak, J. A. Masera's organ responds to odorants. Brain Res. 366: 329–332 (1986).
33. Graziadei, P. P. C. Cell dynamics in the olfactory mucosa. Tissue & Cell 5: 113–131 (1973).
34. Rhodes, P. The senses: The nose and smell. In: Time Atlas of the Body (C. Rayner, Ed.), Rand McNally & Co., New York, 1976, pp. 90–91.
35. Sicard, G., and Holley, A. Receptor cell responses to odorants: Similarities and differences among odorants. Brain Res. 292: 283–296 (1984).
36. Fusch, D. Ultrastructure of mouse olfactory mucosa. Am. J. Anat. 121: 87–120 (1967).
37. Cancalon, P. Degeneration and regeneration of olfactory cells induced by $ZnSO^4$ and other chemicals. Tissue & Cell, 14: 717–733 (1982).
38. Graziadei, P. P. C., and Graziadei, G. A. M. Neurogenesis and neuron regeneration in the olfactory system of mammals. I. Morphological aspects of differentiation and structural organization of the olfactory sensory neurons. J. Neurocytol. 8: 1–18 (1979).
39. Uraih, L. C., Talley, F. A., Mitsumori, K., and Boorman, G. A. Ultrastructural changes in the nasal mucosa of Fischer 344 rats and $B6C3F_1$ mice following an acute exposure to methyl isocyanate. Environ. Health Perspect. 72: 77–88 (1987).
40. Harkema, J. R., Hotchkiss, J. R., and Henderson, R. F. Effects of 0.12 and 0.80 ppm ozone on rat nasal and nasopharyngeal epithelial mucosubstances. Toxicol. Appl. Pharmacol., submitted.

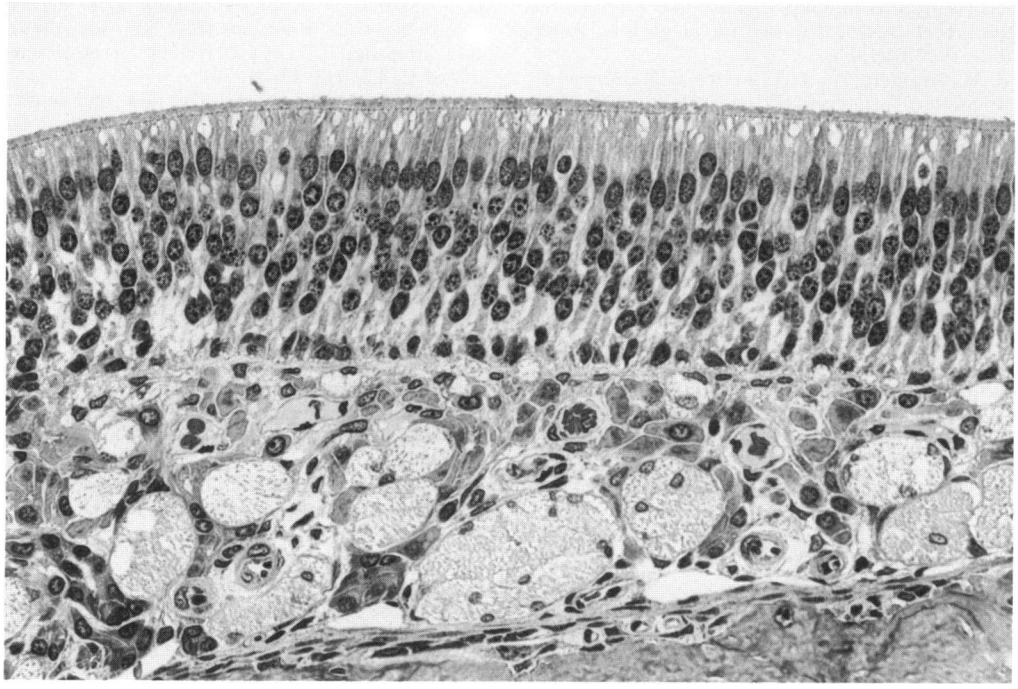

A

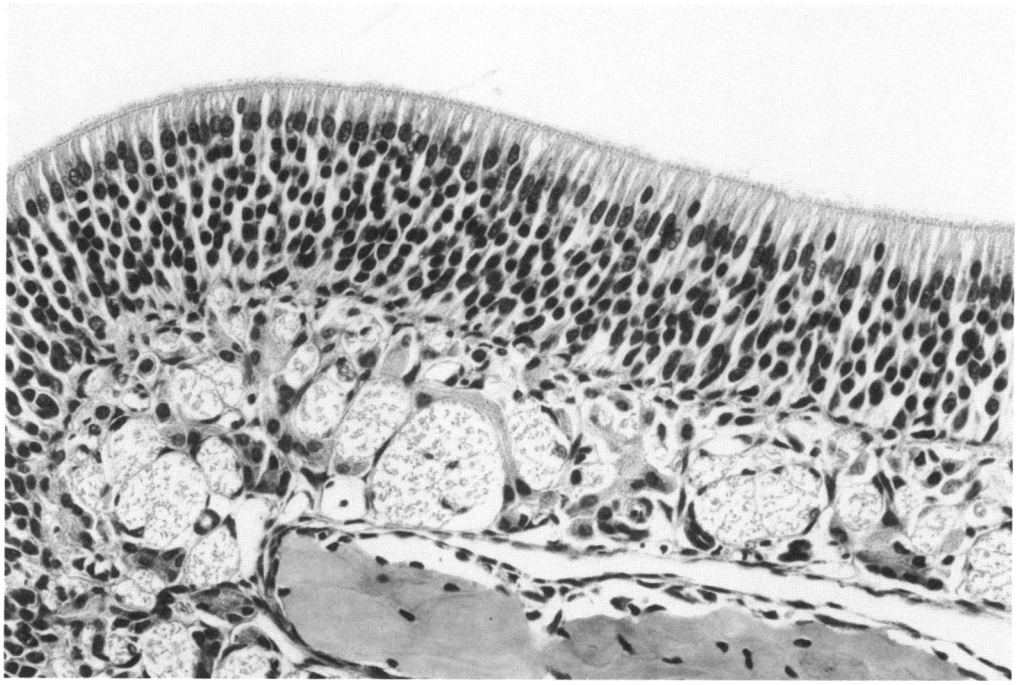

B

PLATE 1. Olfactory epithelia of rat nasal cavity. (*A*) Olfactory epithelium fixed in Bouin's, embedded in GMA. Note maintenance of cell-to-cell contact, good cytological detail, as well as good detail of nerve bundles and acini of Bowman's glands in the lamina propria. (*B*) Olfactory epithelium from rat fixed in Zenker's solution, embedded in GMA shows slight nuclear shrinkage and loss of cytological detail of nerves and Bowman's gland. (*C*) Olfactory epithelium from rat fixed in 10% NBF, embedded in GMA. Note cell shrinkage, cytoplasmic vacuolization of olfactory epithelial cells, secretory cells of Bowman's gland, and olfactory nerve bundles. (*D*) Olfactory epithelium from rat fixed in Fowler's (glutaraldehyde-paraformaldehyde) solution and GMA-embedded. Note maintenance of cell-to-cell contact but loss of cytological detail with coagulation of protein and cell shrinkage. (*Continued on next page*).

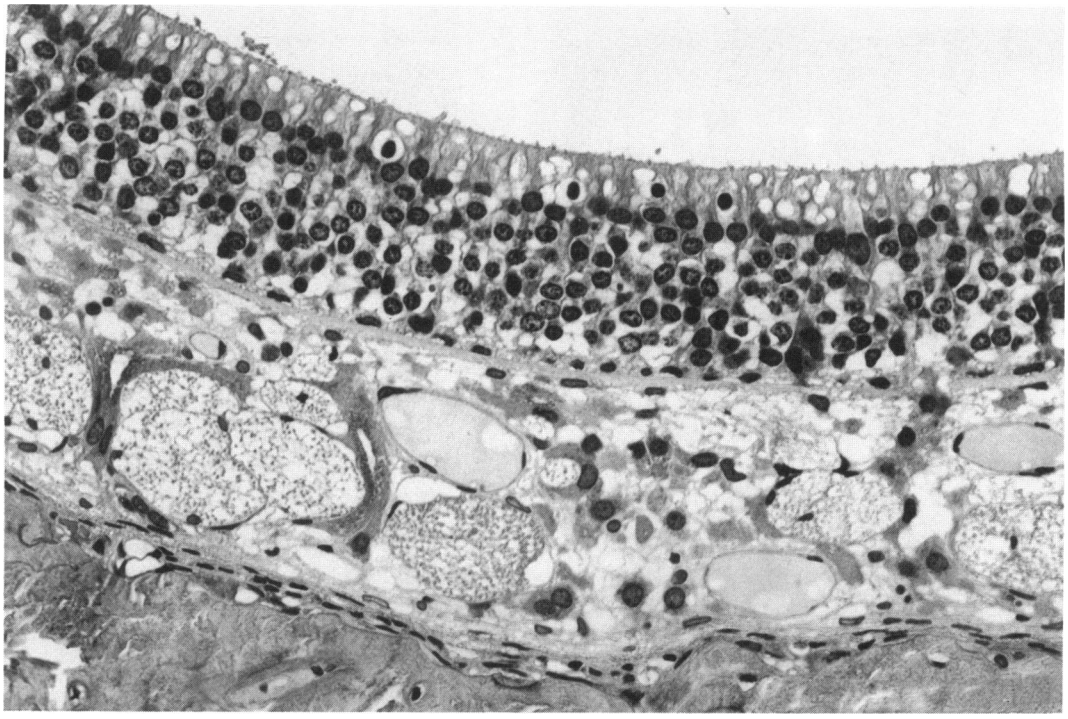

C

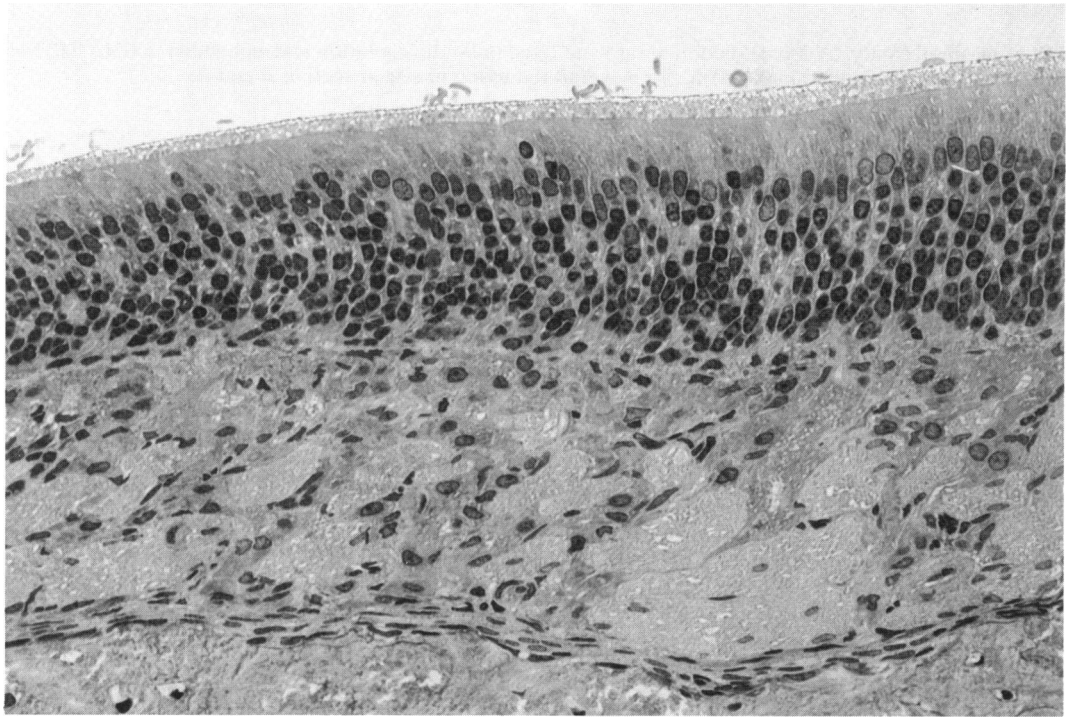

D

PLATE 1. *Continued.*

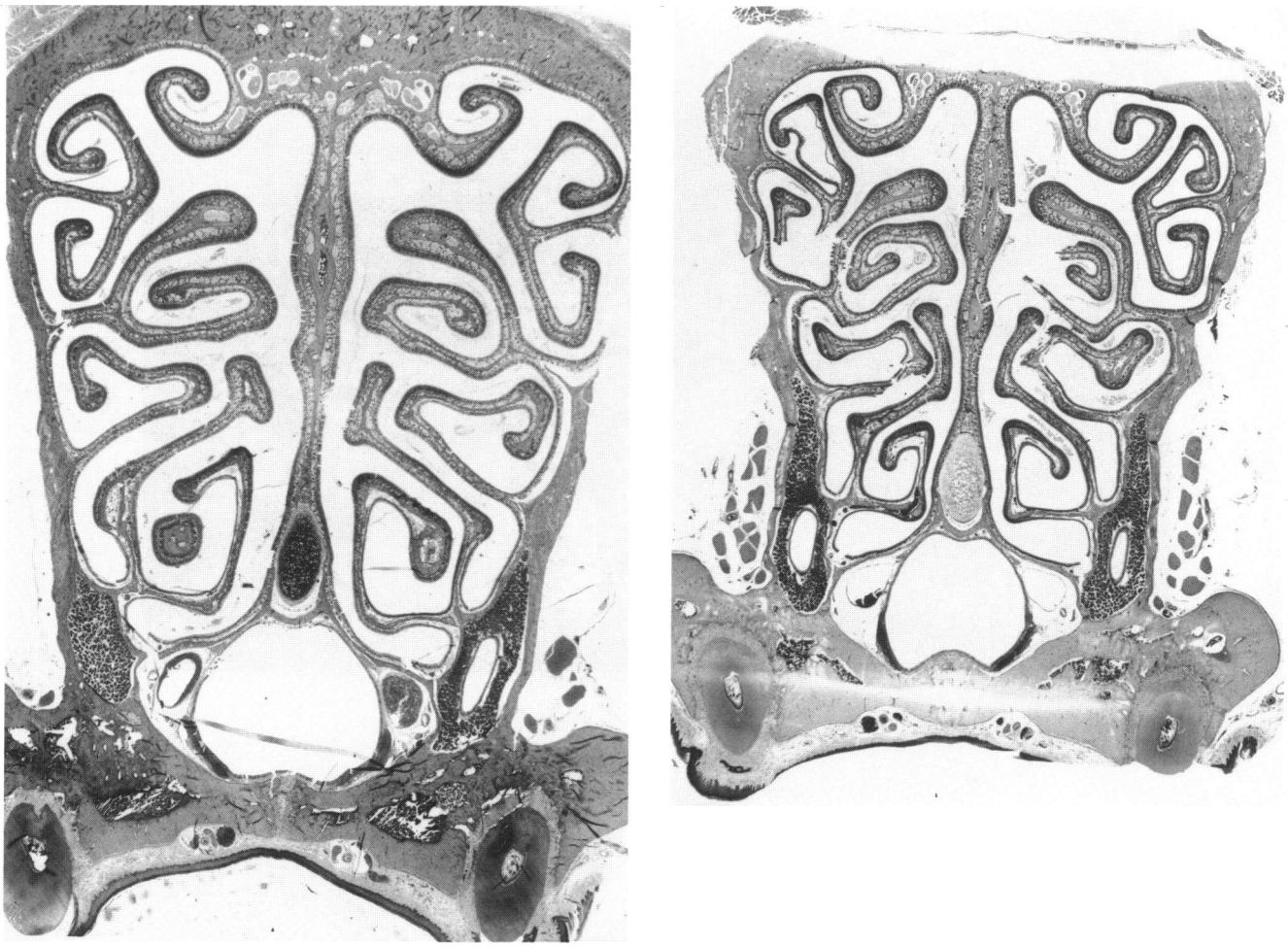

PLATE 2. Level IV of rat nasal cavity. (*A*) Nasal section of rat head fixed in Boulin's solution and embedded in GMA. (*B*) Nasal section of rat head fixed in 10% NBF and embedded in paraffin. Note overall reduction in size of section *B* and *A*.

PLATE 3. A higher magnification of stratified squamous epithelium (SS) from the nasal vestibule. There are five or more cell layers of which the most superficial layer consists of squamous cells. Cells of the basal and intermediate layer are columnar or polyhedral. The lamina propria (L) is a collagenous stroma devoid of glands and hair follicles. (B) Bone.

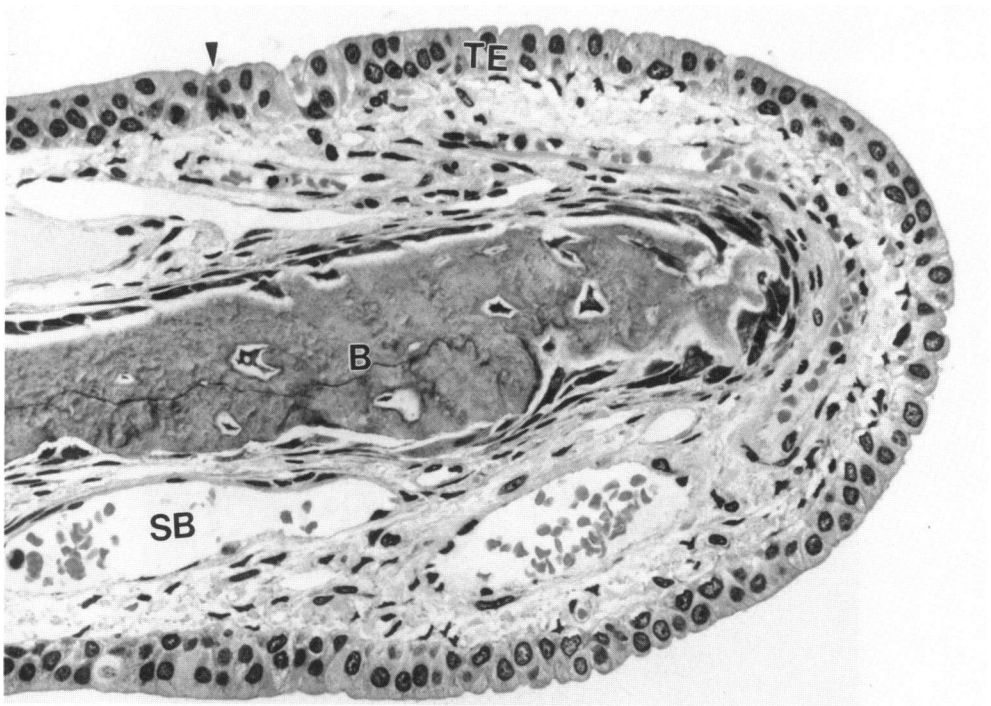

PLATE 4. Maxilloturbinate from level I of the rat nasal cavity. Tip of the maxilloturbinate is covered by a sparsely ciliated (arrow) cuboidal epithelium that is referred to as transitional epithelium (TE) by Harkema et al. (*40*). Bone (B) and venous sinus (SB).

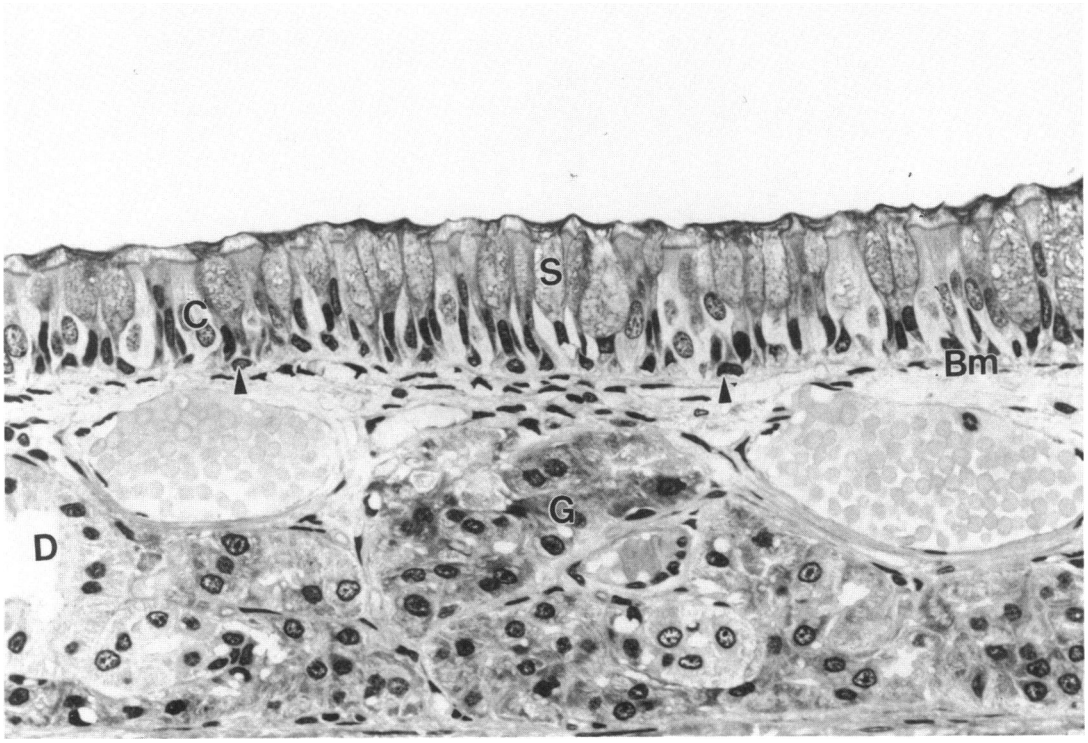

PLATE 5. Respiratory mucosa from the region of the nasal septum is covered by pseudostratified ciliated columnar epithelium. A preponderance of goblet cells (S), and ciliated columnar (C) cells attach to a basal lamina. Basal cells (arrows) are observed just above the basal lamina. Basement membrane (Bm), septal glands (G) in lamina propria, and duct of septal gland (D) are also present.

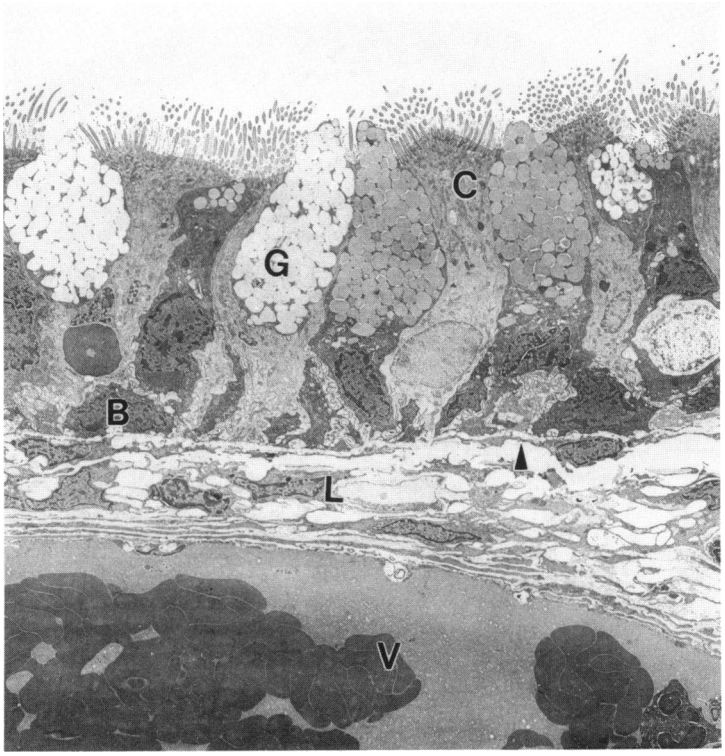

PLATE 6. Ultrastructure of pseudostratified ciliated columnar epithelium from respiratory region of the rat nasal cavity. Basal (B), goblet (G), and ciliated columnar (C) cells, lamina propria (L), venous sinus (V), and basal lamina (arrow). ×2024.

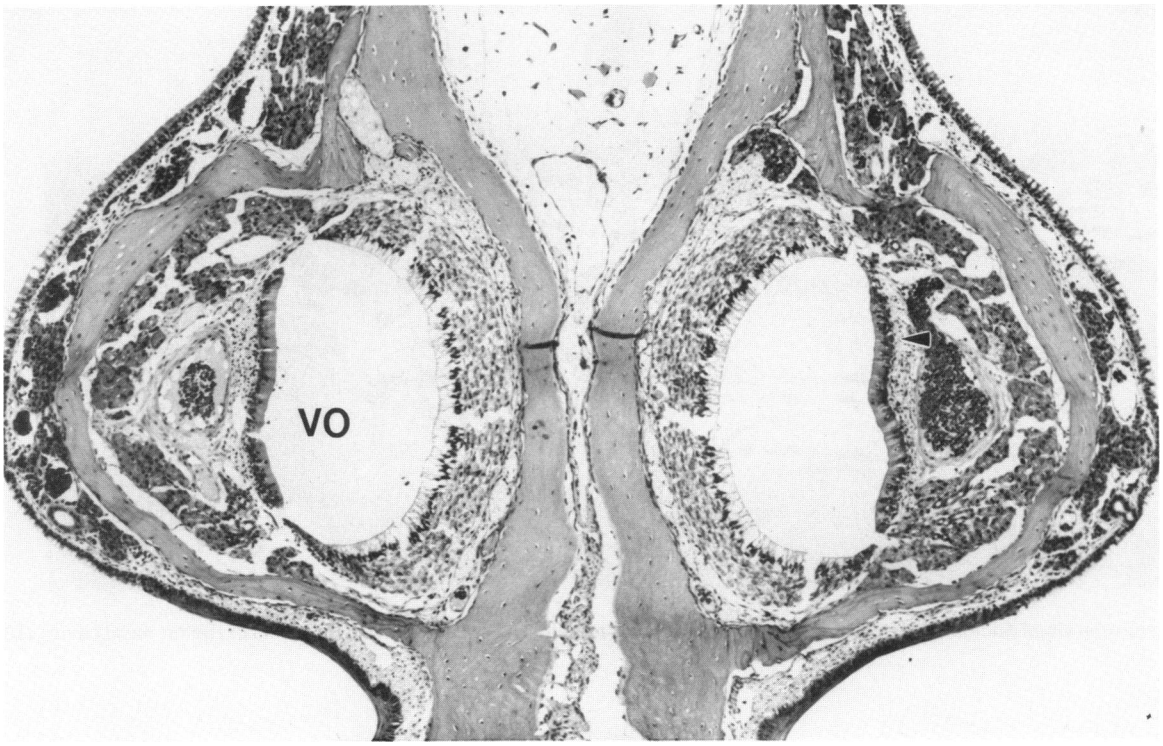

A

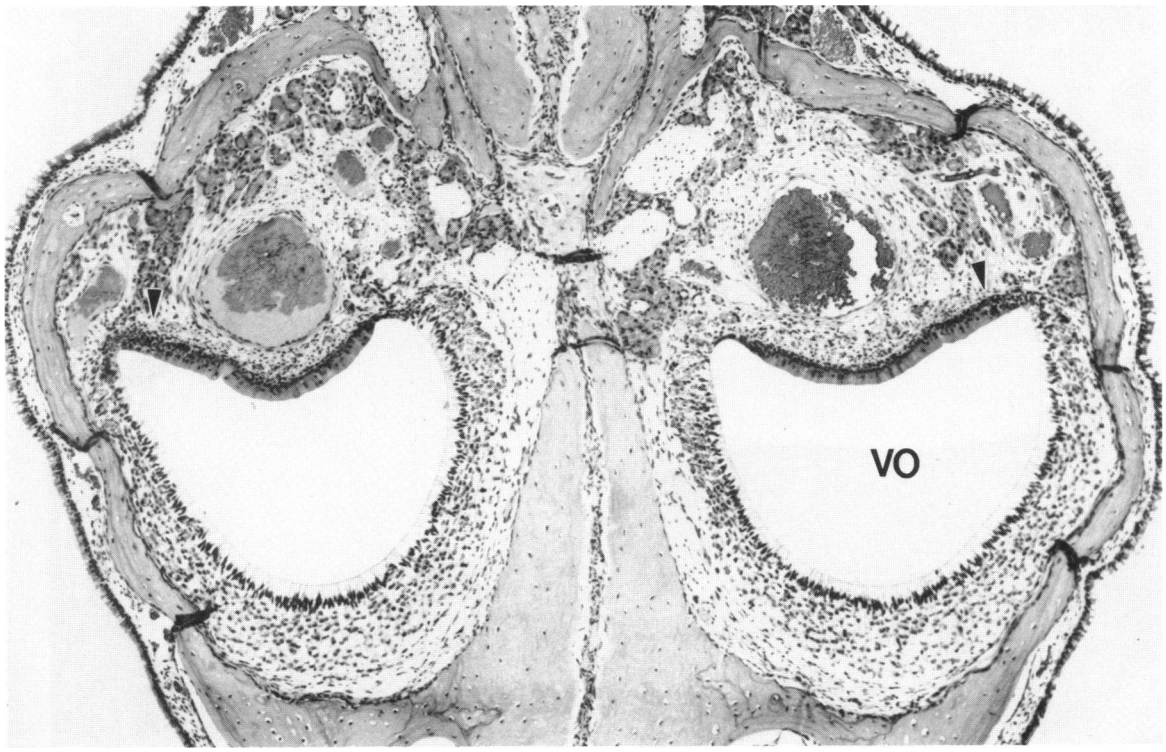

B

PLATE 7. Vomeronasal organ in the rat rotates in the canal of the vomer bone. (*A*) At level I the VO is in a C-shape position. (*B*) At level II the VO in a cup-shape position. Neutrophils commonly emigrate through the columnar epithelium (arrows on a and b).

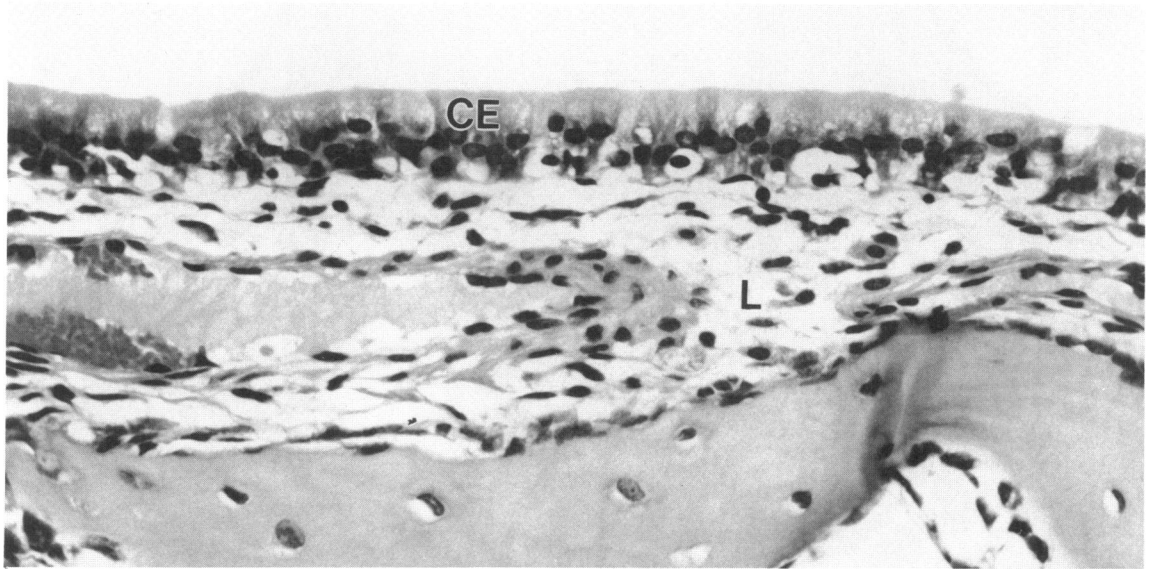

PLATE 8. The nasolacrimal duct is lined by pseudostratified columnar nonciliated epithelium (CE) at level I of the rat nasal cavity. (L) lamina propria.

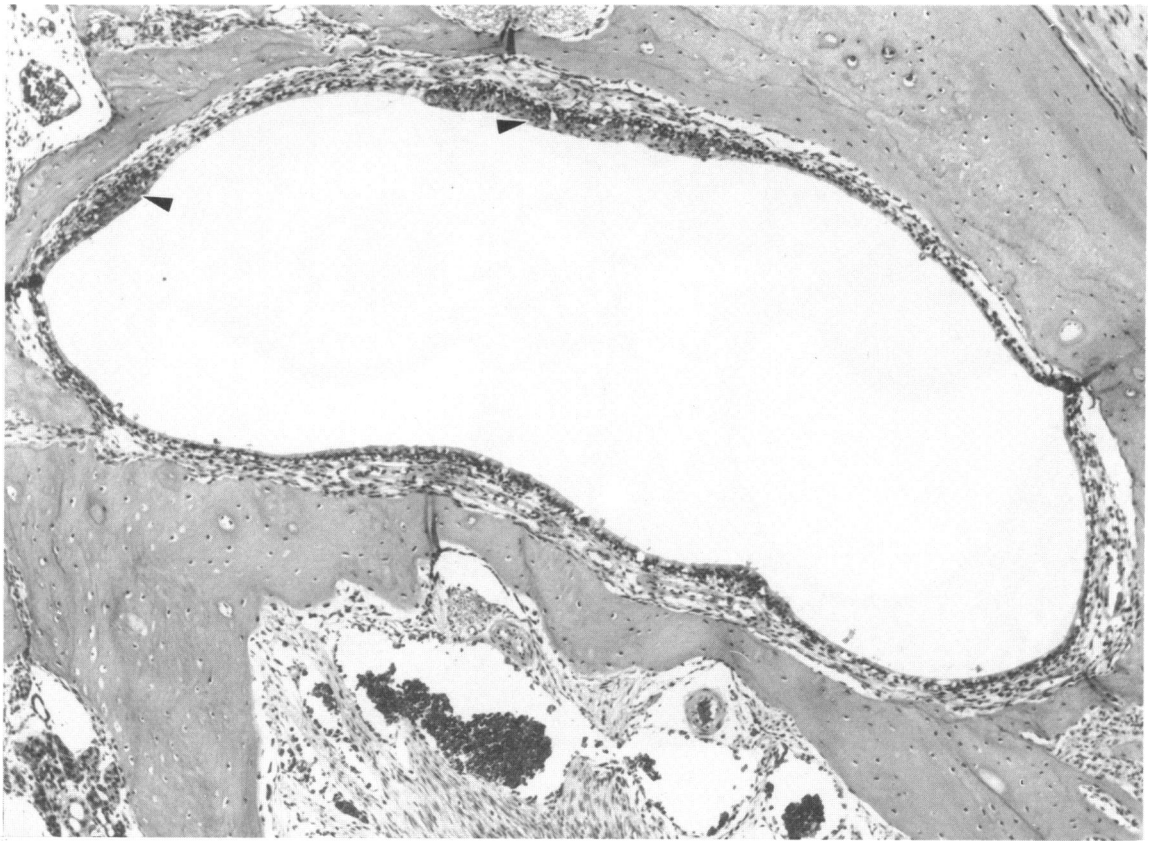

PLATE 9. Squamous metaplasia (arrows) of pseudostratified columnar epithelium is commonly observed in the nasolacrimal duct of the rat.

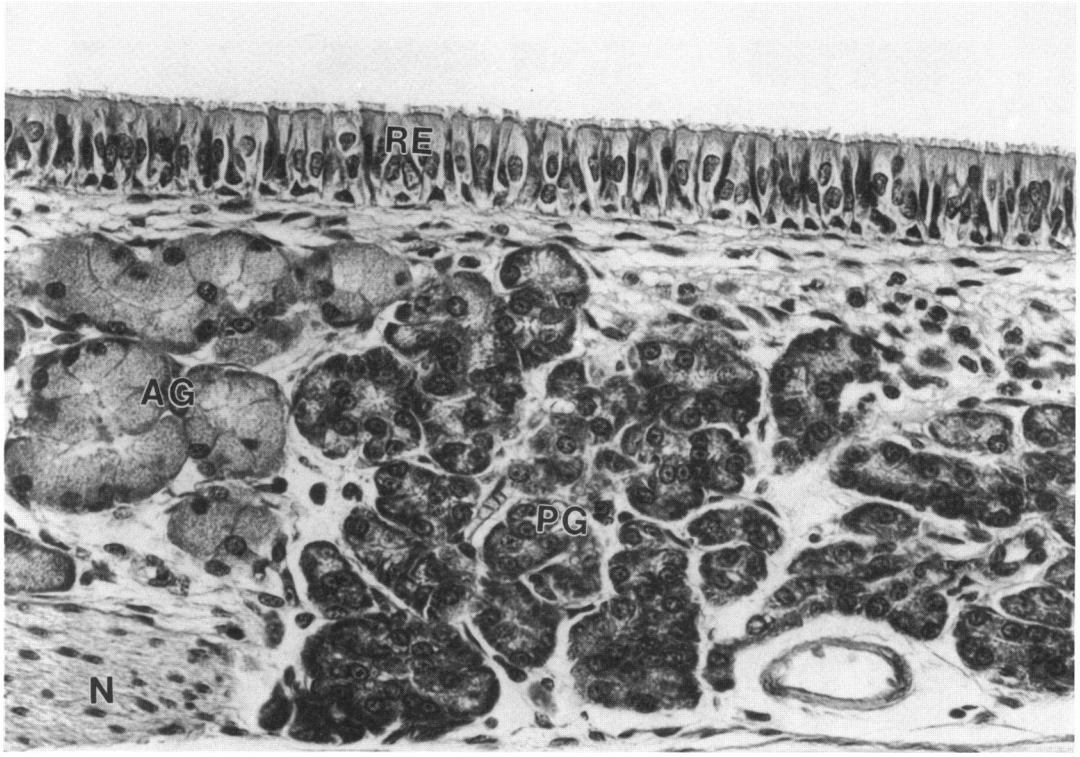

PLATE 10. Respiratory mucosa from the region of the nasal septum in the rat nasal cavity has anterior glands (AG) with finely granular cytoplasm; and posterior glands (PG) with coarse granular cytoplasm in the lamina propria. (RE) respiratory epithelium and (N) nerve.

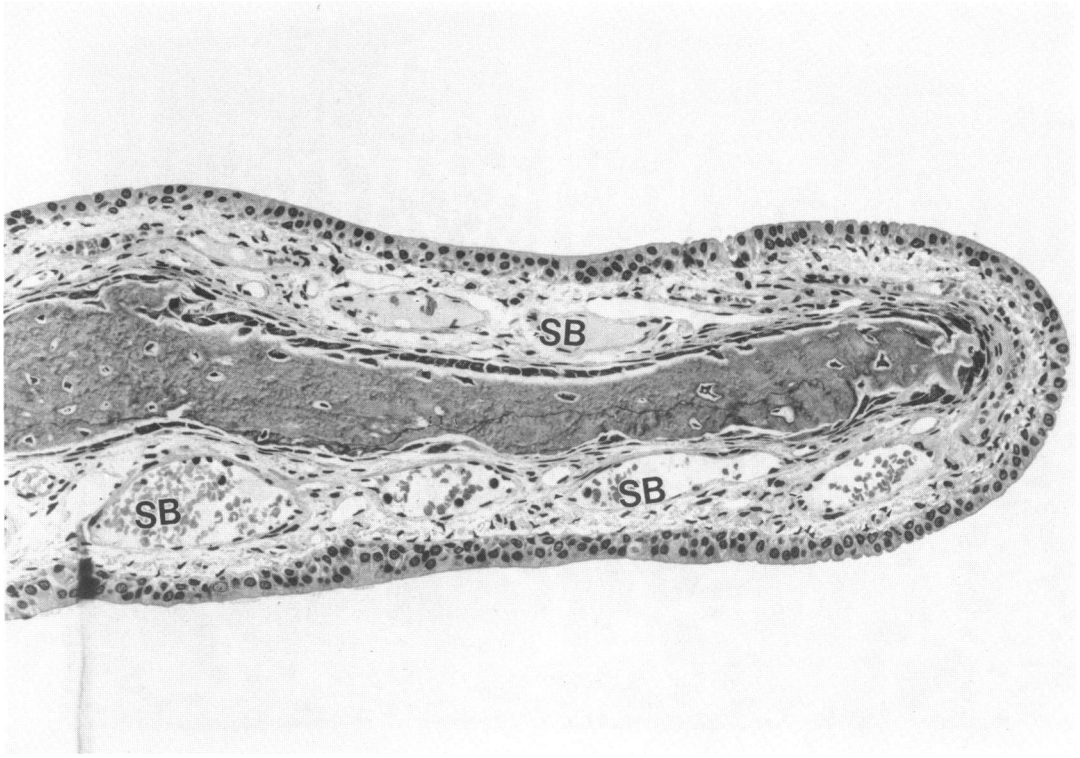

PLATE 11. The maxilloturbinate of the rat nasal cavity has large venous sinuses in the lamina propria known as swell bodies (SB) because of their similarity to erectile tissue in other parts of the body.

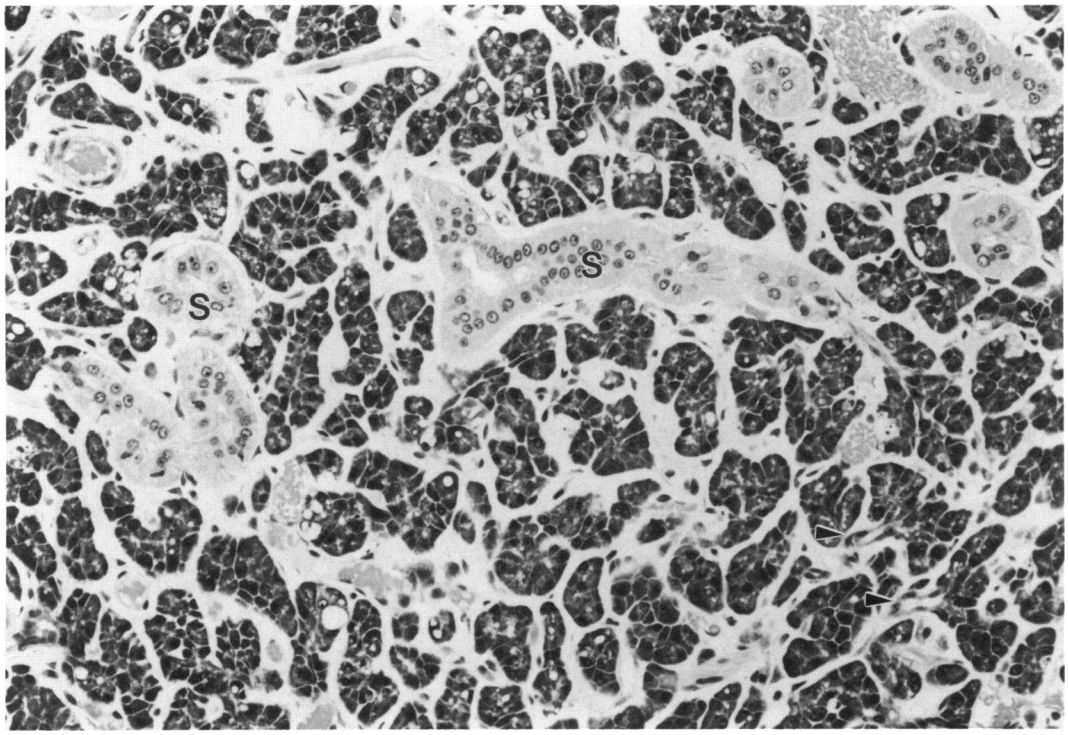

PLATE 12. Higher magnification of lateral nasal glands of the rat nasal cavity. The cytological features are similar to serous salivary glands. The well-developed duct system consists of intercalated (arrows) and striated (S) ducts.

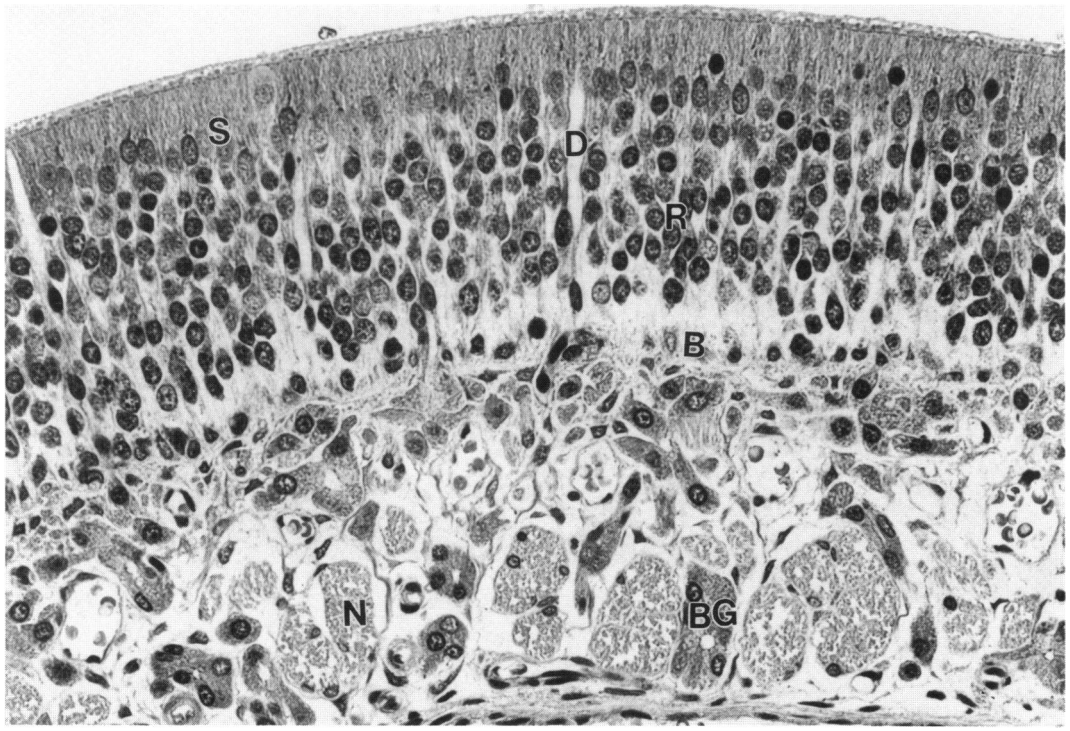

PLATE 13. The olfactory epithelium of the rat nasal cavity is ciliated pseudostratified columnar and is comprised of three cell types: supporting cells (sustentacular) (S), olfactory neurons (R), and basal cells (B). Bowman's glands (BG) and unmyelinated nerve bundles (N) are found in the lamina propria. (D) Excretory duct of Bowman's gland.

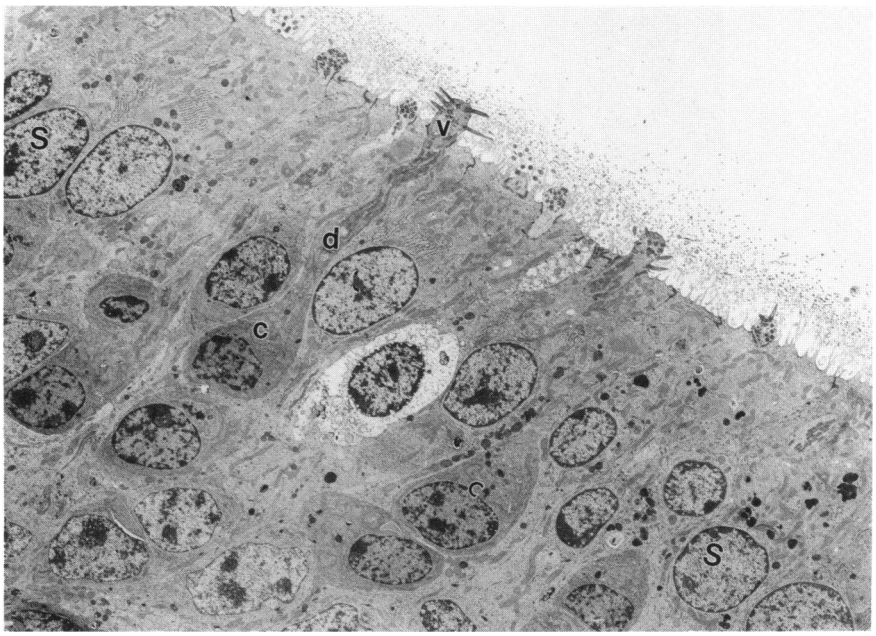

PLATE 14. Transmission electron micrograph of olfactory epithelium shows cell body (c), dendrite (d), and olfactory vesicle (v) of an olfactory neuron. Nuclei of supporting cells (S). ×2576.

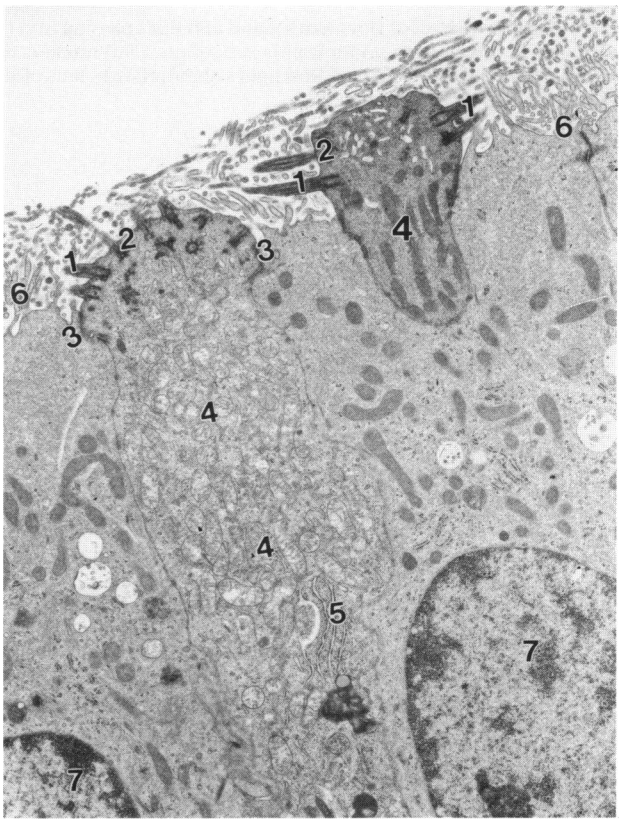

PLATE 15. Detail of olfactory vesicle. (1) Olfactory cilia, (2) basal bodies, (3) junctional complexes, (4) mitochondria in olfactory vesicle and dendrite, (5) rough endoplasmic reticulum, (6) microvilli of supporting cell, and (7) nuclei of supporting cell. TEM × 11960.

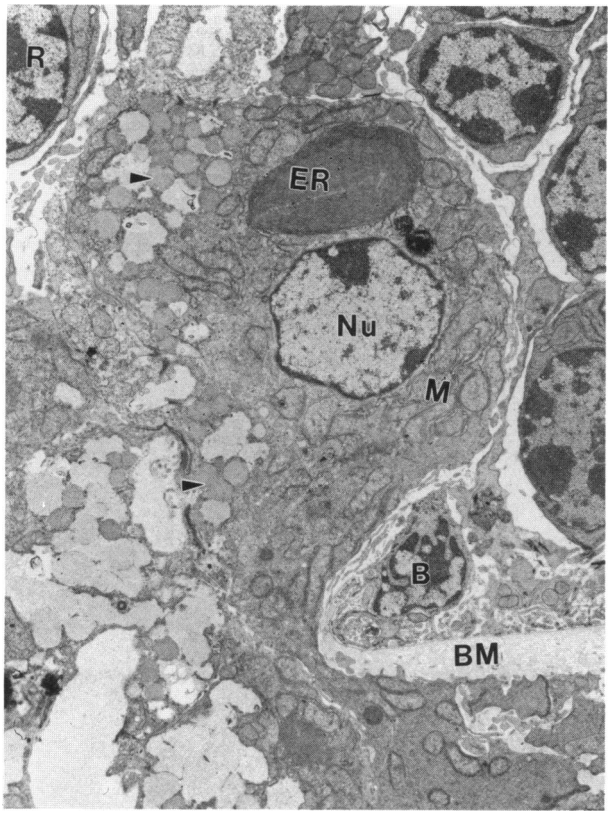

PLATE 16. Transmission electron micrograph shows detail of Bowman's gland and duct passing into the olfactory epithelium from the lamina propria. (ER) Concentrically arranged profiles of smooth endoplasmic reticulum, (Nu) nucleus of secretory cell of Bowman's gland, (M) mitochondria, (arrows) secretory granules, (D) excretory duct of Bowman's gland, (B) nucleus of basal cell, (R) nuclei of olfactory neurons (receptor cells), and (BM) basement membrane × 5520.