CASE REPORTS

◀ Mediastinitis with Aortic-Esophageal Fistula Following Swallowed Fishbone—Pathogenesis, Diagnosis, and Prophylaxis

◀ Term Pregnancy Following Removal of Right Ovary and Left Corpus Luteum Cyst

◀ Hepatitis and Nephrosis Due to Cough Syrup Containing Chloroform

Mediastinitis with Aortic-Esophageal Fistula Following Swallowed Fishbone—Pathogenesis, Diagnosis, and Prophylaxis

CHARLES S. STEIN, JR., M.D., MORRIS PASTERNACK, M.D., and RICHARD O. MEYERS, M.D., *Los Angeles*

ALTHOUGH perforation of the esophagus by a foreign body with subsequent complications is discussed in detail in the American literature, there are only a few reports of perforation of the aorta secondary to such a lesion. A review of the literature and several isolated case reports have appeared recently in the foreign literature. Features presented in them were similar to those in the following case report. In the authors' opinion these features characterize a recognizable clinical syndrome calling for heroic therapy.

CASE REPORT

A 58-year-old white American female entered the hospital April 13, 1948, three hours after swallowing a bone from a "buffalo fish." The patient complained of sharp and constant pain in the thyroid region and in the mid-sternum with radiation to the interscapular region. The past and family histories were non-contributory. No significant abnormalities were noted upon physical examination. Repeated fluoroscopic and x-ray studies of the chest and esophagus after barium and barium-soaked cotton swallows revealed no evidence of the presence of a foreign body or of perforation. The patient was discharged the next day with instruction to return if further difficulty developed. Seven days later she was readmitted with complaint that during the week she had had intermittent aching pain at the xiphoid process and substernally beneath the angle of Louis, radiating to the interscapular region and intensified by the swallowing of solid food or liquids. Six hours before readmission the patient had vomited one to two pints of bright red blood, then had fainted and upon regaining consciousness had perspired freely. The temperature was 101° F., the pulse rate 90 per minute, and respirations 16 per minute. The blood pressure was 160 mm. of mercury systolic and 80 mm. diastolic. In a physical examination no significant abnormalities were observed. Hemoglobin content of the blood was 13 gm. per 100 cc. Leukocytes numbered 6,300 with normal cell differential. The urine was normal. Bleeding time, clotting time, non-protein nitrogen level and liver function profile series were all within normal limits. Esophagoscopy was carried out. There was no foreign body or bleeding point in the entire esophagus, but blood clots were observed immediately beneath the cricopharyngeus and a biopsy specimen from a thickened area 3 cm. below the cricopharyngeus was reported to show leukoplakia. Therapy consisted of parenteral administration of vitamins K and C, a transfusion of 500 cc. of whole blood, and sedation. The following afternoon hematemesis (900 cc.) occurred, and the patient immediately went into profound shock. Transfusion of 1,800 cc. of whole blood was required to raise the blood pressure to 130 mm. of mercury systolic and 90 diastolic. At this time, roentgenologic study of the upper gastrointestinal tract, which was carried out to determine the point of bleeding as a guide to surgical treatment, showed no definite esophageal lesion, although there appeared "to be extrinsic pressure, perhaps from glands in the mid-esophageal area." No varices could be demonstrated fluoroscopically. The stomach was dilated and apparently contained clotted blood. A circular defect along the greater curvature of the fundus was noted. Pronounced pylorospasm prevented filling of the duodenum. In view of the equivocal nature of the findings, operation was postponed, but after another uneventful 24 hours, hematemesis of approximately 1,000 cc. occurred. Exploratory laparotomy with wide gastrotomy and duodenal exploration was carried out but the source of bleeding was not found. For three days postoperatively the patient improved, then bleeding began again and deep shock ensued despite multiple transfusions. The patient died 19 days after swallowing the fish bone and 12 days after the first hemorrhage.

AUTOPSY

Significant findings at autopsy were limited to the esophagus and aorta. At the level of the fourth thoracic vertebra there were two irregular defects in the posterior wall of the esophagus (Figure 1). Each measured 5 mm. in diameter and they were 5 mm. apart. The adjacent esophageal wall was not indurated. The stomach was considerably dilated and filled with fresh blood and blood clots.

The esophageal defects communicated with a mediastinal hematoma 5 cm. in diameter and the mediastinal tissue surrounding it was indurated. Communicating with the hematoma at the junction of the arch and descending thoracic aorta in the anteromedial aortic wall and just medial to the origin of the left subclavian artery was an 8 mm. opening with smooth, slightly raised, rolled borders (Figure 2). The right subclavian and common carotid arteries originated directly from the arch of the aorta.

Numerous slightly calcified, occasionally ulcerated atheromatous plaques were observed throughout the aortic intima. There was no evidence of an aortic aneurysm.

Examination of the microscopic sections from the borders of the esophageal perforation showed acute inflammatory changes characterized by edema and heavy cellular infiltration (Figure 3). This infiltration consisted predominantly of polymorphonuclear leukocytes, but lymphocytes and mononuclear cells were also present. These changes involved

From the Medical Division, Coroner's Department, Los Angeles County, and the Department of Pathology, Los Angeles County General Hospital.

all layers of the esophageal wall and were present to a lesser degree throughout the wall for some distance from the perforation. The esophageal perforation communicated with acutely inflamed and, in some areas, necrotic loose connective tissue of the mediastinum. This process led to acute aortic periarteritis and, in some areas, to acute panarteritis with necrosis of the entire aortic wall (Figure 4). Early atheromatous changes were also present in the aortic wall.

DISCUSSION

Barrie and Townrow[2] collected from the literature reports of 80 cases of perforation of the esophagus and aorta by a swallowed foreign body, and added a report of their own. In many of the cases the clinical features were such as those described by Chiari[3] in 1914—initial substernal pain, symptom-free interval of several days, "signal" hemorrhage, and fatal hemorrhage. The time interval between the esophageal perforation and death varied from five minutes to six weeks, with an average of approximately eight days. The "signal" hemorrhage preceded the fatal one by from two hours to three days, with an average of one day. Frequently pain recurred prior to the signal hemorrhage.

As to the mechanism of perforation of the aorta, Barrie and Townrow stressed the relationship between the character of the traumatizing object (blunt or sharp) and the time interval required for perforation. They expressed the opinion that sepsis does not play an important role. Pin prick perforation of the esophagus, resulting in infection with subsequent necrosis of the aortic wall and rupture due to internal pressure, was suggested by Watson-Williams.[8] Thrombosis of the vasa vasorum preceding necrosis with perforation of the aorta (as observed in carcinoma of the esophagus by Postoloff and Cannon[7]) may well play a role. No doubt, fatal

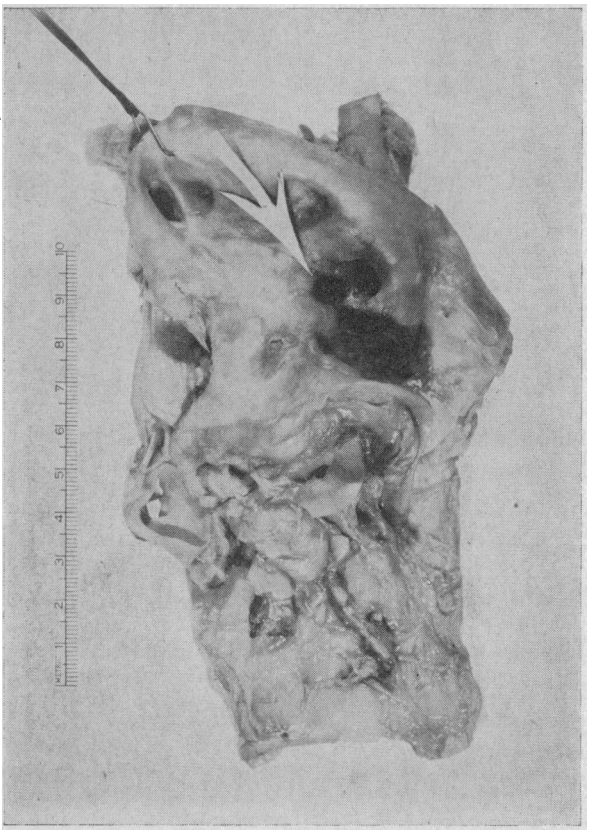

Figure 2.—Aorta. Microscopic section taken at point directly opposite arrow.

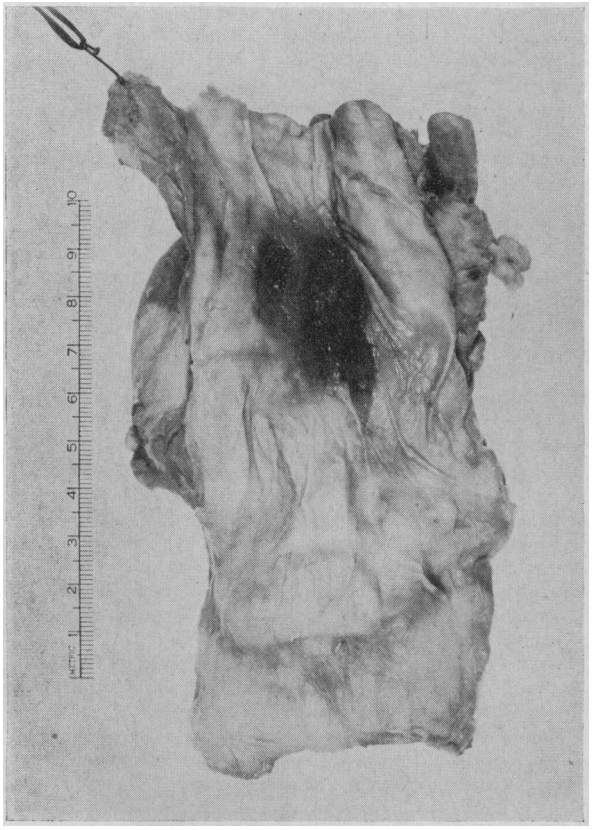

Figure 1.—Esophagus. The defect on the right has been extended. Note the hematoma.

Figure 3.—Esophageal wall.

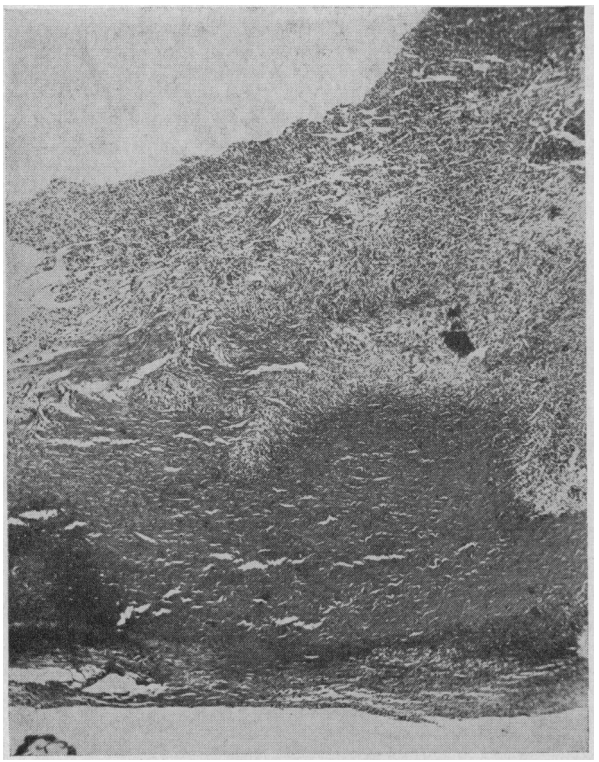

Figure 4.—Aorta. Note the heavy cellular infiltration extending throughout the aortic wall, adventitia (top) to intima (bottom).

hemorrhage may result from direct puncture of a vessel by an ingested object.[4] However, long-delayed hemorrhage as reported by Lascano and Senorans[6] is more compatible with their conclusion that the mechanism is erosion of the esophageal mucosa with subsequent abscess formation and finally aortic perforation following evacuation of the abscess.

Kraus (quoted by Barrie and Townrow) thought the formation of a perivascular clot arrested the initial hemorrhage but that progressive sepsis ruptured this clot, leading to further hemorrhage.

Probably any one or all of the mentioned mechanisms may apply in cases of this type. Since in cases of swallowed bone the offending foreign body is seldom found, it cannot be stated how much of the aortic lesion is due to continued trauma and how much is due to the secondary septic process with no initial direct trauma to the aorta. In the present case the process was probably one of acute localized esophagitis leading to acute mediastinitis and finally periarteritis and arteritis of the thoracic aorta with final weakening of the aortic wall to the point of rupture. No foreign body was recovered and probably the entire course of events was initiated by a superficial wound of the esophageal mucosa without the actual participation of the offending foreign body in the subsequent events. If the perforating object remained in the involved area, it might well be washed out by the gush of blood attendant upon aortic rupture.

Banks,[1] in discussing a similar case, stressed the importance of early esophagoscopy, a view with which the authors are in accord. However, since in several cases esophagoscopy revealed neither the foreign body nor the perforation, and since localized mediastinitis appears to be a major factor in producing aortic perforation with or without aortic-esophageal communication, vigorous chemotherapy is indicated, regardless of the endoscopic findings. Following the swallowing of a foreign body, sequential appearance of initial pain, symptom-free interval, and "signal" hemorrhage should call to mind this syndrome. Probably thoracotomy must be performed if the final fatal hemorrhage is to be prevented.

SUMMARY

A case of aortic-esophageal fistula with fatal hemorrhage secondary to swallowing a fishbone is presented, with clinical and pathological findings. A review of the pertinent literature suggests that localized mediastinitis following esophageal perforation is responsible for the establishment of the aortic-esophageal fistula. Vigorous chemotherapy is imperative even in the face of negative esophagoscopic findings. The sequential appearance of pain, symptom-free interval, and "signal" hemorrhage indicates aortic esophageal hemorrhage and heralds a fatal hemorrhage which may be prevented only by thoracotomy.

4418 Vineland Avenue.

The authors wish to acknowledge the assistance received from the respective heads of the above departments, Frederick D. Newbarr, M.D., and E. M. Butt, M.D.

The patient was on the medical service of Lewis Gunther, M.D., College of Medical Evangelists, Los Angeles.

REFERENCES

1. Banks, R. S.: Fatal aortic-esophageal fistula from swallowed fishbone, J.A.M.A., 122:1011, Aug. 7, 1943.
2. Barrie, H. J., and Townrow, V.: Perforation of the aorta by a foreign body in the esophagus, J. Laryng. & Otol., 61:38, Jan. 1946.
3. Chiari, H.: Ueber Fremdkorperverletzung des Oesophagus mit Aortemperforation, Berl. Klin. Wschr., 51:7, Jan. 5, 1914.
4. Hollinger, P. H.: Complications of esophageal perforations, Ann. Otol., Rhinol., & Laryng., 50:681, Sept. 1941.
5. Krause, quoted by Chiari[3] and Barrie and Townrow.[2]
6. Lascano, E. F., and Senorans, A. J.: Fistula esofagico-aortica infecciosa, consecutiva a una herida esofagica por cuerpo extrano, Arch. Argent. de Enferm., del Ap. Digest. y de la Nutricion, 21:209, May-June, 1946.
7. Postoloff, A. V., and Cannon, W. M.: Genesis of aortic perforation secondary to carcinoma of the esophagus, Arch. Path., 41:533, May 1946.
8. Watson-Williams, E.: Perforation of aorta by swallowed foreign body, J. Laryng., 52:264, April 1937.

Term Pregnancy Following Removal of Right Ovary and Left Corpus Luteum Cyst

VIRGINIA A. SINGLETON, M.D., *San Luis Obispo*

THE patient, a 29-year-old white gravida IV, para II, first observed January 10, 1949, reported irregular "spotting" since the last normal menses on September 5, 1948. She also had noted nausea, menstrual-like cramping, low backache, and a pain in the lower left quadrant of the abdomen.

In the three previous pregnancies there had been two normal deliveries at term (1942, 1944) and one spontaneous miscarriage at four months' gestation (1945). In 1945 an appendectomy and a right salpingo-oophorectomy had been done because of an "infection."

Physical findings were within normal limits. Blood pressure was 110 mm. of mercury systolic and 70 mm. diastolic. The uterus was gravid; gestation had progressed approximately two and a half months. There were no palpable adnexal masses. The cervix was bluish and intact. The