Cuffed Tracheal Tube

A Report of Two Complications

JOHN R. CLARK, M.D.
Long Beach

THE GROWING ACCEPTANCE of tracheostomy and the broadening indications for it have engendered reports of a growing list of technical and pathological morbidities associated with the procedure.[4-6,8,9] The cuffed tracheal tube, whether used with tracheostomy or with orotracheal intubation, has potential dangers which have been documented.[5,7] This presentation cites two cases in which a tracheal cuff was inadvertently hyperinflated, with fatal result in one.

CASE 1. A 71-year-old man with esophageal cancer underwent esophago-colo-gastrostomy with ileostomy and pyloroplasty. Postoperative pneumonia and psychotic reaction developed, and intermittent orotracheal intubation with positive-pressure ventilation was used during therapy. Shortly after one of the periodic ventilation treatments was begun the patient became dyspneic. An attempt to pass a suction catheter through the orotracheal tube to see if mucous plugs were blocking the airway was unsuccessful. To release the pressure of the tracheal cuff the clamp was removed from the inflating tube, and the pilot balloon promptly deflated. Still the suction catheter could not be passed. Despite the deflated pilot balloon, hyperinflation of the cuff was suspected and the inflating tube was cut near the patient's mouth. There was an immediate outpouring of air, but the patient soon died.

CASE 2. A 43-year-old man had a traumatic cerebral and pulmonary contusion with fractures of the clavicle and eight ribs. Tracheostomy helped alleviate subsequent atelectasis, pneumonia and depressed swallowing reflex. On one occasion as the tracheal tube was being inflated in preparation for a positive pressure breathing treatment, the inflating syringe seemed to be working against excessive resistance. Although the pilot balloon was deflated, the patient coughed as if having tracheal irritation. Examination showed that no air was going around or through the tube as would have been expected had the cuff been deflated. The tracheostomy tube was replaced. Nothing abnormal could be found with the cuffed tube, the pilot balloon or the inflating tube.

From the Veterans Administration Hospital, Long Beach.
Submitted March 10, 1965.

Comment

In the first case there were technical errors caused by (1) sticky rubber in the inflating tube of an orotracheal cuffed tube that had been previously used but was thought to be functioning adequately and (2) clamping the inflating tube between the pilot balloon and the air cuff (rather than between the balloon and the opening to the inflating tube). When the inflating tube lost its patency due to repeated clamping over a sticky region, a one-way valve effect was created. Several treatments by an otherwise safe amount of inflating proved additive to the cuff, with eventual obstruction of the airway.

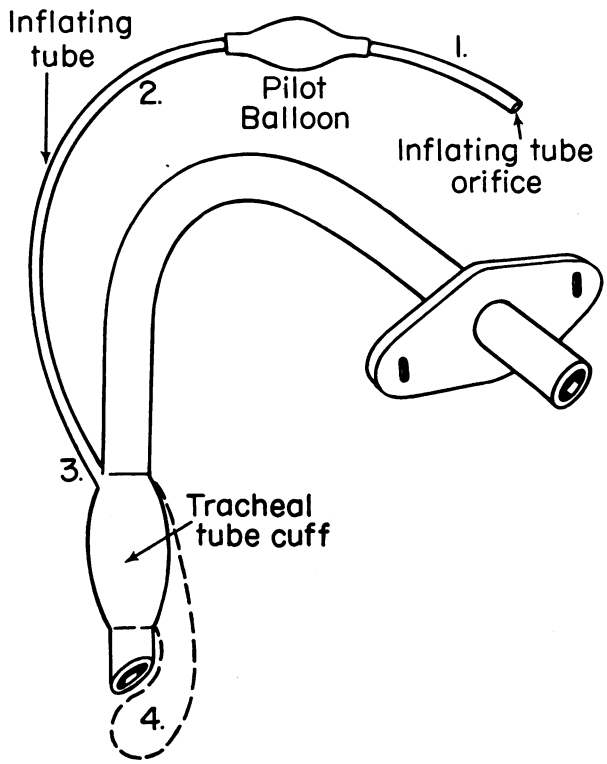

Figure 1.—Pressure-cuff on tracheostomy tube (or on endotracheal tube). 1. Preferred site for applying clamp to maintain air pressure inside cuff. 2. Danger-site for clamp application. 3. Danger-point (for kinking) at air-cuff inflating tube junction. 4. Schematic illustration of hyperinflated cuff.

The second case illustrates a complication of which other observers[9] have warned. In this case, a simple kink in the tube most likely was at fault. As in the preceding case, air could be inserted into the cuff under greater-than-usual pressure, and again the pilot balloon proved misleading.

Ultimately the fault in each case lay in defects of the inflating tube. Preventing these complications can be achieved by one or more of the following measures: (1) Placing the clamp which secures cuff-pressure over the inflating tube between the pilot balloon and the orifice of the inflating tube; (2) Using an air-tight check (usually via a "disposable" plastic syringe) on the exact amount of air inserted into, and then removed from, the cuff; or (3) Using no clamp and leaving an air-tight syringe attached to the inflating tube, the proper pressure being maintained by taping the plunger to the barrel at the appropriate level; or (4) Using the technique recommended by Martinez[7] in which the same intermittent air pressure which ventilates the patient intermittently inflates the tracheal tube. The latter technique is under development.

Summary

Two cases—one fatal—of complications in the use of tracheal cuffs are presented. In both cases the difficulty was due to hyperinflation of the cuff (one an orotracheal cuff, the other a standard tracheostomy cuff) due to malfunction of the inflating tube. Corrective and preventive measures are mentioned.

7018 El Paseo, Long Beach, California 90815.

REFERENCES

1. Atkins, J. P.: Current utilization of tracheotomy as a therapeutic measure, Laryngoscope, 70:1672-1690, Dec., 1960.
2. Davis, H. S., Kretchmer, H. E., and Bryce-Smith, R.: Advantages and complications of tracheotomy, J.A.M.A., 153:1156-1159, 1953.
3. Dugan, D. J., and Samson, P. C.: Tracheostomy: Present-day indications and technics, Am. J. Surg., 106: 290-306, 1963.
4. Binns, P. M.: Tracheal stenosis following tracheotomy, J. Laryng., 78:292-5, March, 1964.
5. Carrie, L. E. S.: A hidden fault in cuffed tubes, Brit. J. Anesth., 36:58-60, Jan., 1964.
6. Glas, W., King, O. J., and Lui, A.: Complications of tracheostomy, Arch. Surg. (Chicago), 85:56-63, July, 1962.
7. Martinez, H. E.: An improved cuffed tracheostomy tube for use with intermittent positive pressure breathing, J. Thor. & Cardiovasc. Surg., 47:404-5, March, 1964.
8. Teplitz, C., Epstein, B. S., Rose L. R., Switzer, W. E., and Moncrief, J. A.: Pathology of low tracheostomy in children, Am. J. Clin. Pathology, 42:48, July, 1964.
9. Yanagisawa E., and Kirchner, J. A.: The cuffed tracheotomy tube: its uses and its dangers, Arch. Otolaryng, 79:80-87, Jan., 1964.

Ethanol-Induced Hypoglycemia

JAMES C. TRUMAN, M.D., AND
JOSEPH PICCHI, M.D.
Oakland

CASES OF HYPOGLYCEMIA occurring after ethanol ingestion have been reported frequently in recent years. As experience has accumulated, it has been found that a period of fasting occurs before the hypoglycemic reaction. In many of the reports the patient was first seen in coma of unknown cause.

Most current reviews of coma neglect this entity; and the frequent association of alcoholism with epileptic seizures, hepatic failure, cerebrovascular accidents, head trauma, hypertensive encephalopathic states and delirium tremens tends to obscure the possibility of ethanol-induced hypoglycemic coma. The following case is being presented to stress again the association of hypoglycemia and previous heavy drinking.

Report of a Case

A 42-year-old Negro man had been arrested for intoxication and booked at the city jail several hours before his admission to hospital. While in jail he reportedly had a seizure, injured his head and was brought semi-comatose to the emergency room. He had a history of 20 years of alcoholism with recent excessive intake of tokay wine. He had had previous admissions, for head trauma and for pneumonia. There was no history of seizures.

On physical examination he responded only to painful stimuli by moving all extremities, all equally well. Rectal temperature was 99°F. Except for a slightly wasted appearance, a small abrasion at the left occiput, occasional symmetrically tonic movements of the limbs, bilateral Babinski reflexes and hyperactive deep tendon reflexes, the results of examination were within normal limits.

After an initial specimen of blood was drawn for determination of sugar content (which was later reported to be 17 mg per 100 ml), 50 ml of 50 per cent glucose solution was administered intravenously. Over the subsequent five minutes

Submitted February 15, 1965