Intestinal Obstruction Complicating Acute Perforative Appendicitis

W. RUSSELL SMITH, *M.D.*, Los Angeles

• Upon preoperative diagnosis of acute small bowel obstruction, without an obvious cause, acute perforative appendicitis must be considered. Reevaluation of the history and careful reexamination of the physical findings with that diagnosis in mind should be carried out. If appendiceal disease is likely, maximum antibiotic therapy must be begun immediately along with the administration of fluids, electrolytes and other corrective therapy. A mercury-weighted small bowel tube should be inserted and every effort made to advance it into the small bowel before operation. Operative treatment should be restricted to the least possible. A McBurney incision is best unless wider operation is indicated. If an abscess is present, drainage alone may be the procedure of choice. Severely distended and decompensated small bowel must be decompressed, for if not relieved it can be the cause of death in acute perforative appendicitis. Decompression may be accomplished either by small bowel intubation with continuous suction or by enterotomy and aspiration. If not relieved, small bowel distention will be the mechanism responsible for death in a large percentage of patients with acute perforative appendicitis.

ACUTE PERFORATIVE appendicitis may occur with or without significant distention of the small bowel. When present, the distention may be a manifestation of adynamic ileus (inhibition obstruction, paralytic ileus), with or without peritonitis, or it may be present as the result of acute mechanical obstruction caused by the appendiceal lesion. Minimal intestinal distention rarely creates a problem in management, whereas major problems may be presented by severe adynamic ileus or mechanical obstruction secondary to acute perforative appendicitis. Clinically it may be difficult to distinguish between these two conditions; and they may co-exist, or one may follow the other. Furthermore, severe adynamic ileus may become converted into mechanical obstruction if the intestinal distention is allowed to persist. Late in the course of acute perforative appendicitis, intestinal obstruction may dominate the clinical features and obscure completely the underlying appendiceal disease. A surgeon should not be lulled by a diagnosis of "ileus," for both this condition and mechanical obstruction require early, vigorous treatment.

In the five years 1952-56, emergency appendectomy was done in 3,418 cases at the Los Angeles County General Hospital. There were 31 deaths in this series, a mortality rate of less than 1 per cent. In eight of the fatal cases, a preoperative diagnosis of small bowel intestinal obstruction had been made. At operation the small bowel obstruction in all of the eight patients proved to be secondary to complications of acute perforative appendicitis. In five patients, the mechanism of intestinal distention was mechanical obstruction, and in three it was inhibition obstruction (adynamic ileus). Analysis of these eight cases was made in an effort to determine why the primary diagnosis was not made before operation, what effect this had in the death of the patient, and how the management of these cases could have been improved.

CASE REPORTS

CASE 1. A 69-year-old man was admitted to the hospital on a medical service. He was in a state of mental confusion. The history obtained was of loose stools for a week, vomiting for four days and questionable hematemesis.

The body temperature was 96°F. The abdomen was soft and moderately distended, with bilateral lower abdominal tenderness and rebound tenderness. There were no masses palpable and peristalsis was hypoactive. Leukocytes numbered 8,400 per cu. mm. of blood, with 75 per cent polymorphonuclear neutrophils. An x-ray film of the abdomen showed severe small bowel distention with stepladder distribution with some gas in the right colon (Figure 1). A diagnosis of intestinal obstruction was made.

Fluids were given intravenously, without antibiotics, and nasogastric suction was provided. Operation was done seven hours after admission. The small bowel was dilated and dusky throughout. No pulsation was felt in the base of the thickened mesentery. Fibrinous exudate was present throughout the lower abdomen with partial localization in the right lower quadrant. The cecum was adherent to the ileum one foot proximal to the ileocecal valve, and a fecalith was present in the peritoneal cavity. The patient was hypotensive during the operation and because of the critical state the collection of exudate in the right lower quadrant was drained

From the University of Southern California School of Medicine and the Surgical Service, Los Angeles County General Hospital, Los Angeles.

Presented before the Section on General Surgery at the 86th Annual Session of the California Medical Association, Los Angeles, April 28 to May 1, 1957.

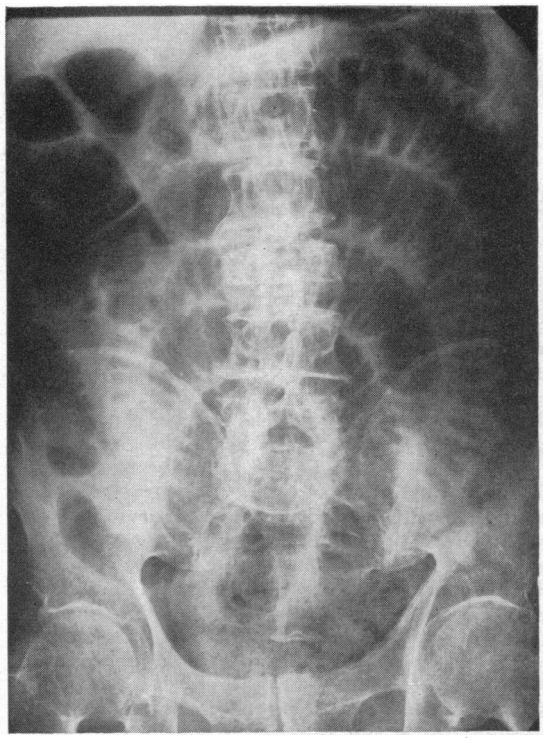

Figure 1 (Case 1).—Severe distention of small bowel with stepladder pattern; some gas in the right colon.

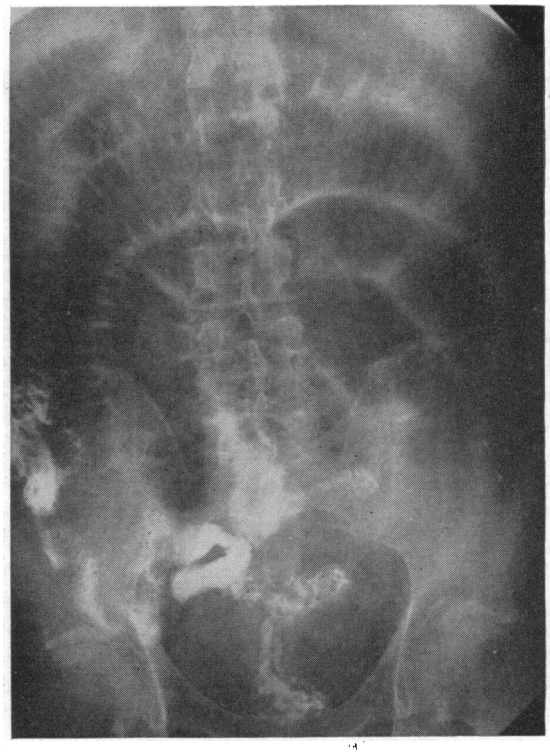

Figure 2 (Case 3).—Postevacuation roentgenograph with barium enema, showing a trace of barium throughout the colon with reflux into the terminal ileum; severely distended remaining small bowel.

and nothing further was attempted. The patient remained in shock despite intensive therapy and died a few hours later. At autopsy, extensive and diffuse peritonitis was noted.

CASE 2. A 69-year-old man entered the hospital with a history of abdominal pain, vomiting and watery diarrhea for three days. He was obese and confused. The skin was cold and the body temperature was 100°F. The blood pressure was 110/90 mm. of mercury and the pulse rate was 140. There was moderate tenderness in the right lower quadrant and peristalsis was diminished. It was felt that the symptoms were owing to either acute hemorrhagic pancreatitis or strangulated small bowel obstruction. The serum amylase content was within normal limits and a plain film of the abdomen showed severely distended small bowel. The patient was given intravenous fluids and nasogastric suction was applied. Four hours after entry, he was operated upon. Generalized peritonitis secondary to an acute perforative appendicitis was observed. The small bowel was greatly dilated with fluid and gas, and the ileum was bound into the right lower quadrant inflammatory process. The appendix was removed and enterotomy with aspiration of the small bowel was done. The patient did poorly despite all supportive measures. He died 18 hours later with a terminal temperature of 106°F. Autopsy showed generalized peritonitis with areas of atelectasis.

CASE 3. The patient, a 59-year-old man with left hemiplegia, hypertensive cardiovascular disease and a long history of alcoholism, became anorexic five days before admittance. Three days before entry, nausea, vomiting, cramping mid-abdominal pain had developed. The temperature was 99°F. There was moderate abdominal distention and tenderness over the lower abdomen. Leukocytes numbered 8,000 per cu. mm.—56 per cent polymorphonuclear neutrophils. A lesion of the colon was suspected. No abnormality was seen sigmoidoscopically. X-ray studies with barium enema showed severe distention of the small bowel with a haze in the right lower quadrant (Figure 2). A diagnosis of small bowel intestinal obstruction was made. A right paramedian incision was made six hours after entry and an appendiceal abscess and small bowel obstruction, were observed. The obstruction was released and an appendectomy done. The postoperative course was poor. Hypotension, abdominal distention and hypoactive peristalsis were complicating factors. On the second postoperative day, the patient went into shock. Treated with whole blood and supportive care, he improved somewhat, but then again went into shock and died on the fourth postoperative day. There was no clinical evidence of acute pulmonary or cardiovascular lesions, and the final diagnosis was appendicitis, perforated appendix with peritonitis, and small bowel obstruction with severe ileus.

CASE 4. A 22-year-old man entered the hospital with complaint of abdominal pain, anorexia and vomiting of two days' duration. The temperature

was 99.6°F. The abdomen was moderately distended and there was moderate central tenderness and increased peristalsis. Leukocytes numbered 15,250 per cu. mm.—85 per cent polymorphonuclear neutrophils. X-ray studies, including barium enema, showed severe small bowel distention with some gas in the colon and a diffuse mass in the right lower quadrant of the abdomen. At operation an appendiceal abscess with small bowel obstruction was noted. Shock occurred after the operation and continued for the first three postoperative days. The patient had abdominal distention and oliguria. On the fourth day, the distention increased, cramping pain developed and a mass was palpated in the left upper quadrant of the abdomen. Roentgenographically the mass appeared to be small bowel, and at operation a volvulus of the entire small bowel with a short mesenteric attachment and gangrene of two areas were noted. A ten-inch segment and a six-inch segment of gangrenous bowel were resected from the extremes of the small bowel. The oliguria continued and icterus was noted the day after the second operation. Nonprotein nitrogen content gradually rose to over 300 mg. per 100 cc. of blood. The condition of the patient deteriorated and on the twenty-third postoperative day he died. At autopsy perforation of one of the anastomotic seams and abscess formation at the site were observed. Multiple staphylococcal lung abscesses and acute nephrosis also were present.

CASE 5. A 76-year-old man entered the hospital with lower abdominal pain and vomiting of four days' duration and diarrhea for two days.

The temperature was 99.4°F. The abdomen was distended and tender with occasional high-pitched peristaltic sounds. A plain film of the abdomen showed severely distended small bowel and some gas in the large bowel (Figure 3). Leukocytes numbered 5,900 per cu. mm.—68 per cent polymorphonuclear neutrophils. A diagnosis of intestinal obstruction was made. At operation the appendix was observed to be perforated and at the site was a localized abscess trapping and obstructing the small intestines with plastic adhesions. The appendix and the abscess were removed and the obstruction released. Because of the severe distention of the small bowel and intralumenal fluid, enterotomy was done and the contents aspirated. Moderate distention continued. The patient pulled the tube from the small bowel several times. By the fourth postoperative day, the abdomen was severely distended despite continuous suction. The patient improved slowly and on the seventh postoperative day peristaltic sounds were heard. Distention had abated somewhat. A soft diet was permitted. Moderate distention continued. Oral alimentation was poor and the patient was sometimes nauseated. Although he was given supportive care he died suddenly on the eleventh postoperative day, the cause of death was not apparent. Autopsy was not done.

CASE 6. A man 72 years of age was admitted with a history of abdominal pain and obstipation for six

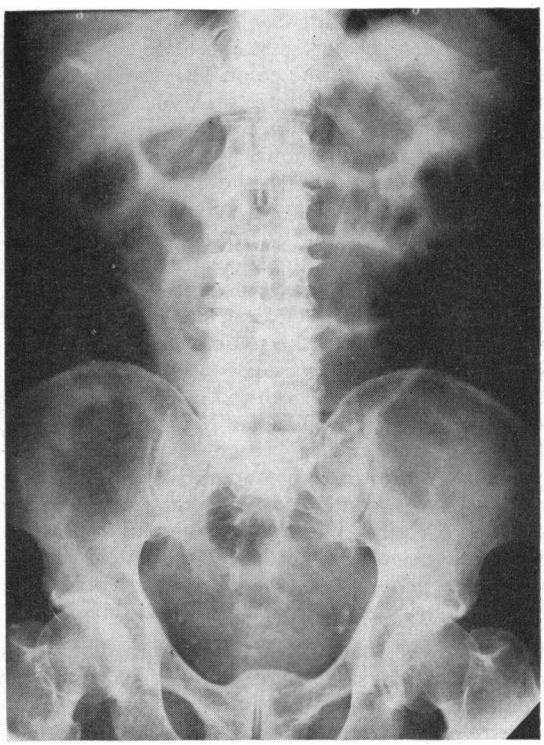

Figure 3 (Case 5).—Severe distention of small bowel with some large bowel gas pattern.

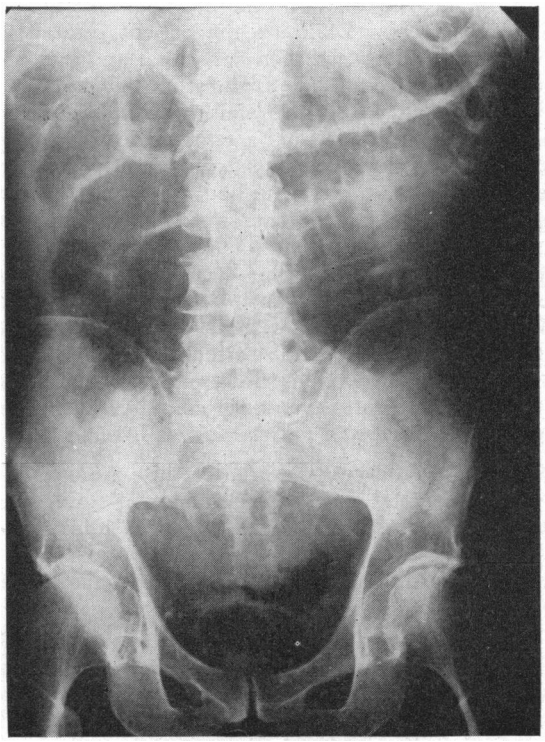

Figure 4 (Case 6).—Severe distention of small bowel with stepladder pattern; a little gas in the rectal ampulla.

days and fecal vomiting for one day. A plain film of the abdomen showed severely dilated small bowel with very little gas in the colon (Figure 4). A diagnosis of small bowel intestinal obstruction was made. Nasogastric suction was applied and fluids were given by vein. Six hours after entry, the patient was operated upon and acute perforative appendicitis, causing a right lower quadrant abscess and generalized peritonitis, was observed. The small bowel was trapped in the abscess, causing complete intestinal obstruction. Appendectomy was done and the obstruction was released. The postoperative progress was slow but the patient continued to improve and the suction was discontinued on the fifth postoperative day. The nonprotein nitrogen content had been 120 mg. per 100 cc. of blood and the serum potassium 5.6 mEq. per 100 cc. at the time of admittance; by the sixth postoperative day the nonprotein nitrogen content was 45 mg. and the serum potassium 4.7 mEq. per 100 cc. The patient died on the seventh postoperative day. The clinical impression was bronchopneumonia, generalized peritonitis with secondary ileus. Autopsy was not done.

CASE 7. The patient was a 73-year-old white woman who entered the hospital with a history of abdominal pain and vomiting for 24 hours. She was extremely obese. Generalized abdominal tenderness and distention were noted. The temperature was 100°F. Leukocytes numbered 12,300 per cu. mm.—88 per cent polymorphonuclear neutrophils. An x-ray film of the abdomen showed a generalized haze with several loops of distended small bowel (Figure 5). A diagnosis of small bowel intestinal obstruction was made but for 24 hours the patient refused to have an operation. She then consented and was operated upon through an exploratory incision. An adynamic ileus was noted and the small intestine was severely distended. The appendix, which was ruptured, was removed. The postoperative course was poor. For two days the body temperature was high. The chemical contents were within or near normal range. The patient was extremely lethargic, without obvious cause. She became stuporous on the eighth postoperative day. Because of excessive collection of bronchial secretions, tracheostomy was done. The condition of the patient steadily deteriorated and she died on the thirteenth postoperative day with sepsis and pulmonary complications. The abdomen was soft and peristalsis was hypoactive.

CASE 8. An 83-year-old senile white woman entered the hospital in a confused mental state with generalized abdominal pain of one week's duration, "black stools" and vomiting. She was under treatment for "heart trouble," and had had gallbladder trouble for years.

The temperature was moderately elevated, there was distention and generalized tenderness of the abdomen. Occasional high-pitched peristaltic sounds were heard. An x-ray film showed severely distended small bowel (Figure 6). A diagnosis of small bowel intestinal obstruction was made. The patient was operated upon through a lower midline incision be-

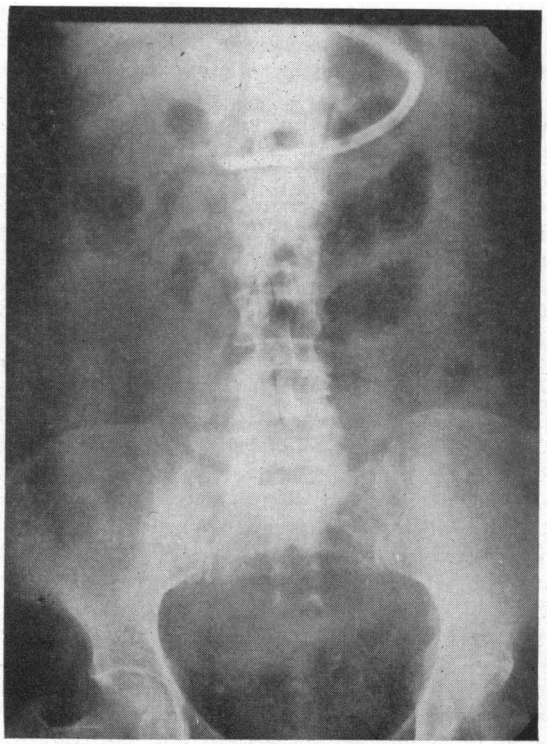

Figure 5 (Case 7).—Generalized haze over abdomen with several loops of distended small bowel; small amount of gas in colon.

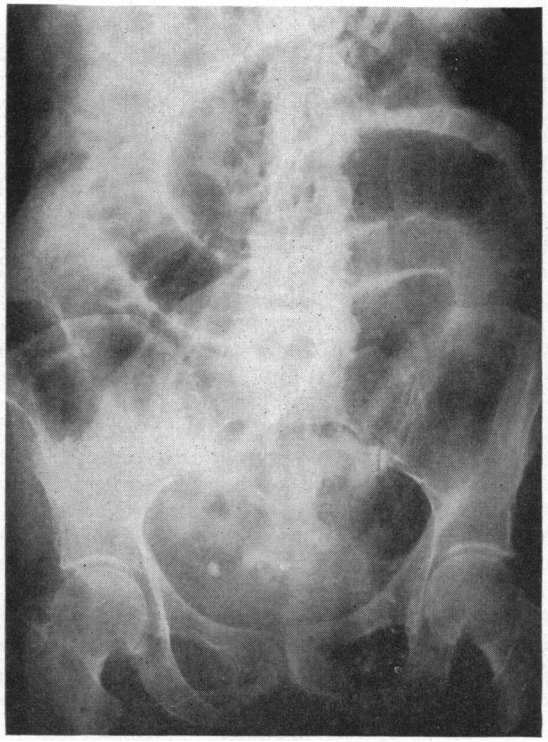

Figure 6 (Case 8).—Severe distention of small bowel without definite colon gas.

cause a femoral hernia was thought to be present. The femoral area was intact, however. A pericecal abscess which had not been palpated in the preoperative examination, extended down into the pelvis to the right of the rectum. The abscess was drained through the right flank. By the fourth postoperative day the patient was eating, was ambulatory and was passing gas rectally. The abdomen was soft and moderately distended. Persistent high-pitched peristaltic sounds were heard. A low grade fever then developed. The patient required digitalization because of heart failure. Bilateral surgical parotitis developed. By the eighteenth postoperative day, there was persistent diarrhea with a soft cul de sac mass. Abdominal distention was slight. Deterioration continued. A right inguinal abscess was drained, with little effect on the condition of the patient, and she died on the thirty-eighth postoperative day of an acute febrile illness complicated by senility, cardiac failure and parotitis.

DISCUSSION

These cases emphasize that when a diagnosis of intestinal obstruction is made in the case of an elderly patient, acute perforative appendicitis should be considered as a possible cause of the obstruction, particularly if previous surgical operation, hernia or other more common causes are lacking. The history should be carefully reevaluated with that diagnosis in mind. Furthermore, if there is likelihood that appendicitis is present, maximum antibiotic therapy should be given preoperatively.

Noble[6] stated that death in acute peritonitis results from the obstructing tangle of bowel and not from the infection. In the pre-antibiotic era, overwhelming acute peritonitis was the most common cause of death.[1,3,7,8] It will be noticed that in two of the eight cases (Cases 1 and 2) reported herein, death resulted from overwhelming peritonitis. Both patients died on the first postoperative day and were little helped by antibiotic therapy and surgical drainage. In the remaining six patients, peritoneal infections were less prominent. Although the exact cause of death was not established in each case, the major role played by the dysfunctioning obstructing tangle of intestine referred to by Noble[6] was clearly demonstrated. The pathological development involved in these cases was small bowel distention, leading to severe loss of fluid and electrolyte loss.

Often the significance of dilatation of small bowel will not be adequately recognized. In advanced peritonitis the bowel becomes decompensated. A superimposed mechanical obstruction is not ushered in with the usual cramps, tinkles and peristaltic rushes. The onset is silent and insidious and, consequently, a diagnosis of adynamic ileus rather than mechanical obstruction may be made. Dilated and decompensated, the small bowel invites fluids and electrolytes to pour quietly into its lumen. A sharp drop in urinary output occurs concomitant with the loss into the third compartment. Compartmental fluid shift was conspicuous in this series and it was the chief contributing factor in the deaths of at least four patients (Cases 3, 4, 5 and 6). In Case 4, shock following the first operation, presumably, brought about the lower nephron nephrosis that caused the patient to die of uremia on the twenty-third day. In Case 3, hypotension and shock developed on the second postoperative day, and again on the fourth postoperative day. Although the postoperative state was complicated by cardiovascular disease, the main factor leading to death was hypovolemia secondary to the peritonitis and intestinal obstruction. In Case 6 a severe illness was present and a mechanical obstruction was relieved at operation. This was followed by severe adynamic ileus that persisted throughout the postoperative period until death on the seventh day. The patient in Case 5 died on the eleventh postoperative day. Throughout the entire period after operation he had moderate to severe abdominal distention. In this patient, as in the others mentioned, the third compartment fluid loss into the dysfunctioning small bowel was considered the main cause of death.

Not only is it necessary to replace the lost fluid and electrolytes, but the underlying cause of the loss must be dealt with. When the small bowel distention persists, a vicious cycle is established. Efforts toward decompression of the small bowel should be instituted early.[2,4,5] To do this, a mercury-weighted gastrointestinal tube is inserted. Positioning of the tube at the pylorus is facilitated by fluoroscopic visualization. If peristalsis is active, advancement of this tube into the distended small bowel may occur while preoperative fluid correction is being carried out. If peristalsis is sluggish or absent, no advancement of the tube can be expected. During the operative procedure, however, it is frequently possible to advance it manually into the distal small bowel. But if that is not possible, enterotomy with aspiration of the contents of the small bowel will be required if the degree of intestinal distention is extreme. In less severe cases, release of the stricture may be all that is required. Relief of the distention of the small bowel is essential whether it be accomplished by nasogastrointestinal intubation with aspiration, by enterotomy with aspiration, or by freeing the obstructing stricture so that the small bowel contents can pass into the colon. Gastrointestinal suction both before and after operation may help greatly toward relieving the intestinal distention and resultant intestinal dysfunction. In Case 4 the second surgical procedure might have been averted had the small bowel been intubated and the distention relieved. In Case 3, decompression of the small bowel

would have lessened the fluid and electrolyte imbalance and the necessary replacement could have been more accurate. In Case 6, in which distention continued throughout the entire postoperative course, effective suction might have been life-saving. In Case 5, also, there was unrelenting distention, death occurring on the eleventh postoperative day.

Since even under optimal conditions effective nasogastrointestinal suction is difficult to obtain, it would seem mandatory to place the tube before operation if a diagnosis of intestinal obstruction is made. With generalized peritonitis, peristalsis lacking and the abdomen distended, it is almost impossible to intubate the small bowel effectively.

The operative procedure must be dictated by conditions. A McBurney incision is generally best for an appendectomy or for an appendiceal abscess in which drainage only is indicated and the drainage is expected to relieve the intestinal obstruction. Medial extension of this incision may afford adequate exposure of the area and access to the small bowel, should it be necessary.

1930 Wilshire Boulevard, Los Angeles 57.

REFERENCES

1. Aud, G.: Deaths from appendicitis in Louisville, Southern Med. Jour., 34:914, 1941.
2. Cantor, M. O., Kennedy, C. S., and Reynolds, R. D.: Use and abuse of intestinal decompression tube, Amer. J. Surg., 73:437-449, 1947.
3. Harris, F. I., and Gordon, M.: Intestinal intubation in small bowel distention and obstruction, S. G. and O., 86: 647-658, 1948.
4. Harris, F. I.: A new rapid method of intubation with the Miller-Abbott tube, J.A.M.A., 125:784, 1944.
5. McClure, R. D., and Altemeier, W. A.: Acute perforated appendicitis with peritonitis, Ann. Surg., 105:400, 1937.
6. Noble, T. B.: Paralytic ileus from peritonitis after appendicitis, Amer. Jour. Surg., 84:419-428, 1952.
7. Ochsner, A., and Gage, I. M.: The intra-abdominal postoperative complications of appendicitis, Ann. Surg., 91: 544, 1930.
8. Totten, H. P.: Mortality factors in appendicitis with perforation, Surgery, 106:1035, 1937.

For Your Patients—

A Personal Message to YOU:

As your personal physician I consider it both a privilege and a matter of duty to be available in case of an emergency. But, being only human you can understand that there are times when I may not be on call. I might be at a medical meeting outside the city, on a bit of a vacation—or even ill.

Consequently, I thought it would be a good precaution if—on this gummed paper which you can paste in your telephone book or in your medicine cabinet—I listed numbers where I can be reached at all times. Also, the number of a capable associate as an added service. Here they are:

_____	_____	_____
OFFICE	HOME	MY DOCTOR
_____	_____	_____
OFFICE	HOME	ASSOCIATE

Sincerely,

_____, M.D.

MESSAGE NO. 1. Attractive, postcard-size leaflets printed on gummed paper, you to fill in telephone numbers and your signature. Available in any quantity, at no charge, as another service to CMA members. Please order by Message Number from CMA, PR Department, 450 Sutter, San Francisco.