Surgical Treatment for Poliomyelitis Paralysis

Principles of Reconstruction of the Upper Extremities

EDWIN R. SCHOTTSTAEDT, *M.D.*, LOREN J. LARSEN, *M.D.*, and FREDERIC C. BOST, *M.D.*, San Francisco

• Successful surgical reconstruction of the upper extremities paralyzed by poliomyelitis depends largely on the careful analysis of the individual problem and replacement of critical motions of the upper extremity. These replacements or substitutions may be gained by muscle transposition, tendon transplantation, tenodesis, bone block, or arthrodesis.

PARALYTIC POLIOMYELITIS can bring about a great variety of limitations of use of the upper extremities. The motor power still available in patients with upper extremity paralysis will determine the amount of reconstructive operation necessary for functional rehabilitation. Such rehabilitation is dependent upon the physical status of the patient in each case. In some cases only enough functional rehabilitation to permit a patient to carry out self-care can be effected, while in others an operative procedure can change the status of the patient from the standpoint of employability.

Depending upon the requirements of the patient and estimates of what can be done surgically, the aim is to regain certain categories of function for each patient. In the upper extremity, stability, range of motion and strength are needed. Many different operative techniques have to be used, the procedure depending upon the individual need, and the degree of improvement in status will vary. Limb mobility is the major consideration, although stability is important as related to holding objects or to limb placement. Stability is most important proximally, while motion becomes increasingly important distally, in this order: Scapulothoracic, scapulohumeral, elbow, wrist, finger joints. The available work area for any given patient will depend in some degree on the placement and use of his upper extremities to increase his utilization of this work area.

As a general rule the middle ranges of joint motion are of greatest functional value and should be sought for first. For purposes of discussion at this time, emphasis will be put upon certain procedures which have been found to be of proved worth in cases of paralytic poliomyelitis involving the upper extremity. The movements most essential to function are: Grasp (or some portion thereof), wrist flexion and extension, pronation and supination, elbow flexion and extension, humeral internal and external rotation, humeral flexion and extension and humeral abduction. Scapular stability and trunk balance are important in the full utilization of those motions. It must be kept in mind that every motion must have an opposing motion, although in some instances the opposing motion may be attained passively or by gravity.

Finger and thumb flexion and extension may be attained by the use of any active musculotendinous unit of the wrist, either flexor or extensor. This is probably related to the fact that wrist stability in various hand activities is supplied simultaneously both by wrist flexors and extensors. Furthermore, highly specialized muscles such as these which are under excellent cortical control will learn new patterns of motor activity with ease. Thumb and finger flexion frequently can be regained by transferring the extensor carpi radialis longus and brevis to the thumb and index finger and the extensor carpi ulnaris to the outer three fingers. If necessary the brachioradialis can be used to provide flexion to the third, fourth and fifth fingers. Its strength is excellent, but its range of motion is shorter than that of the wrist extensors.

It should be borne in mind that muscle fiber length is directly proportionate to the range of excursion in that muscle in its original anatomical site.[3] This is in direct relation to the range of motion it originally supplied to a joint. For that reason, wrist muscles should be transferred to the fingers so that they may work through a functionally useful range of midposition. Thus, when the brachioradialis is used the fingers should be pre-positioned into a more flexed position than when wrist motors are used. When transferring all wrist extensors, arthrodesis of the wrist is done, for finger extensors alone have not sufficient strength to provide stabilization

From the Shriners' Hospital for Crippled Children, San Francisco, and the Department of Orthopedic Surgery, University of California School of Medicine.

Presented before the Section on Orthopedics at the 85th Annual Session of the California Medical Association, Los Angeles, April 29 to May 2, 1956.

for the wrist except for light activities. Even in such activities they gradually produce hyperextension of the metacarpophalangeal joints. Wrist flexors can be used to provide or reinforce finger flexion, although they are often absent when finger flexors are absent. Wrist flexors can also provide thumb and finger extension. The surgical program is often planned so that the flexor carpi radialis is placed in the thumb, and the flexor carpi ulnaris into the finger extensors. A variation of this may be to utilize the palmaris to provide extension of the index finger, and the flexor carpi ulnaris is then placed to the outer three extensors. The brachioradialis may be used as a finger extensor, although it is not as good as wrist motors in this location. Wrist fusion is unnecessary when moving the flexors except in very rare circumstances.

THUMB AND FINGERS

Patients who require a respirator generally have associated upper extremity weakness. The hands in particular are susceptible to contracture which may develop as the arms lie constantly in a fixed position. A large portion of the patient's time is spent with the fingers in a position of comfort. Proper splinting and exercise are difficult and painful and require the services of carefully trained and indoctrinated personnel. Even when the hands are exercised daily a full range of motion cannot always be secured. Motor power which may be regained is not always effective in mobilizing the metacarpophalangeal joints due to established contracture; and when this condition prevails, capsulectomy of the collateral ligaments of the metacarpophalangeal joints may be indicated.

Frequently poliomyelitis results in "clawing" of the fingers, caused by pronounced weakness or loss of the lumbricales and interossei. In such instances hand function can be improved materially by the use of Bunnell's technique of transplantation of flexor digitorum sublimus tendons into the dorsal interossei expansions.[1] This is an excellent procedure that has given very satisfying results in properly chosen cases. The surgeon must first assure himself that the flexor digitorum profundus has sufficient function to provide for finger closure without the aid of the flexor digitorum sublimus.

Thumb opposition is of great importance in hand function, and restoring it provides an appreciable functional gain. This gain will be acquired differently under varying circumstances. When there has been a loss of opponens only, opposition is best secured through transfer of the tendon of the flexor digitorum sublimus to the fourth finger around the flexor carpi ulnaris tendon, or through a tendon pulley just above the pisiform with attachment of the tendon to the distal dorsal ulnar aspect of the first metacarpal or proximal phalanx or to both. The line of force must be directed toward the pisiform. While many other procedures are useful, this particular one is most gratifying to the patient and to the physician. The fewer the muscles remaining about the thumb, the less effective will be the end result. In some instances other motor power must be supplied to the thumb by means of tendon transplants to effect useful return of opposition. If thumb involvement is severe, and available muscles for transfer are limited, arthrodesis of the first metacarpal to the greater multangular or by bony bridge to the second metacarpal is desirable. Occasionally, fusion of the first metacarpal to the multangular plus tendon transplantation to provide active opponens replacement will give results superior to those obtainable by fusion alone. This provides for opponens pre-position by joint stabilization and requires less motor power for active opposition. Thus, severe loss of other thumb muscles may be compensated for partially while allowing some active opponens motion. In general, procedures to replace opposition are successful functionally even though the function obtained may not equal normal opposition.

WRIST MOTION

Because of its functional significance, wrist motion should be retained if possible. It is surprising how much a patient can accomplish using varying degrees of wrist dorsiflexion alone without active finger flexion. In selected cases tenodesis of the flexor digitorum profundus to the radius may provide excellent grasp, activated solely by strong wrist extensors. Here, wrist extension is of vital importance. However, if motor power in the wrist is absent, or if the muscles are thought to be functionally more useful at a new site, wrist arthrodesis should be done. If the wrist joint cannot be stabilized, motion which should be expressed in the fingers may reach them in a very dilute form, if at all.

Pronation and supination of the wrist are important. Because the wrist flexors rise from the medial humeral condyle, if any strength remains in these muscles, the patient will have weak pronation. Adequate supination may be provided by an active biceps. If this muscle is paralyzed, supination sometimes can be gained for the patient by biceps replacement—for example, transposition of either the pectoralis major or the latissimus dorsi to gain an attachment to the radial tubercle.[2,9] If no supination is present in the face of good pronation, the flexor carpi ulnaris or palmaris longus insertion may be transferred dorsally to the distal radius, thus pro-

viding this motion. An assisting hand does not necessarily require wrist motion or pronation and supination. However, if these movements are present the functional competency of the extremity is greatly enhanced.

ELBOW FUNCTION

Elbow function depends upon three major uses —flexion, extension and stability. At times all three may be restorable. The most important function is flexion which gives ability to lift objects and to move them from place to place without the assistance of either the other arm or a functional aid. The strength of this motion will determine the patient's ability to accomplish many daily habit activities as well as his work. Flexion is best obtained by Steindler's flexorplasty where the wrist flexor origins are shifted proximally on the humerus from the medial humeral condyle.[10] Flexor digitorum sublimus and flexor digitorum profundus origins may be shifted proximally, but use of them without strong wrist flexors is doomed to disappointment. Properly executed, Steindler's flexorplasty provides a very satisfying replacement. Full elbow extension following this procedure is uncommon and is not desirable, since for mechanical reasons the net result is a decrease in overall strength and function. Much greater force is required to initiate flexion from full extension. The elbow flexors seem most competent at about 90 degrees of flexion. Therefore, bone block of the elbow is often done at the time of flexorplasty. This is indicated particularly when only weak flexion is expected to result from the procedure. Bone block of the elbow may be used to produce a flexion contracture of between ninety and one-hundred and thirty degrees. Less strength, therefore, is necessary to produce elbow flexion at such an angle than would be required if extension were complete. The bone block, while limiting the flexion arc, preserves the range of greatest functional usefulness. After bone block the patient also may enjoy some of the advantages of elbow arthrodesis, since the elbow which has been blocked allows for the transportation of objects in the flexed range and without use of muscle power.

Clark's procedure (pectoralis major transplant) or a modification of it done by the authors is useful and can permit the lifting of about eight pounds as measured at the hand. This procedure can be used to aid flexion and will also provide supination by transfer to either biceps or radial tuberosity. The forward transposition of the latissimus dorsi will give results equal to the pectoralis major transposition when done on carefully selected patients. Triceps transfer forward to the biceps tendon or radial tuberosity results in strong flexion, although through a range which approximates about one-third that of the biceps. Elbow extension is useful; one can push with the extended elbow, but this action is so seldom needed for light activities that it is hardly valuable enough to consider replacement in order to obtain it. Gravity will provide this motion for most activities, and this, working against varying positions of elbow flexion with an efficient elbow flexor, will provide power for most necessary function in varying ranges of elbow flexion and extension. In selected cases stability can be gained usefully by arthrodesis or by bone block. When there is no available muscle for replacement, arthrodesis will provide stability in flexion. The arm may then be used for carrying objects.

HUMERAL ROTATION

The importance of humeral rotation is not generally appreciated. A large number of activities of the upper extremities depend upon this movement. Writing and eating are two simple examples. The subscapularis, pectoralis major, teres major and the latissimus dorsi all act to provide internal rotation. The supraspinatus, infraspinatus and the teres minor are the chief external rotators, but the long head of the triceps assists in this motion. If only internal rotation remains in the paralyzed extremity, external rotation can be secured by transfer of the latissimus dorsi and teres major laterally, after the method of L'Episcopo. Humeral abduction is not as important as humeral forward flexion. Humeral forward flexion can be provided by several active muscles, or combinations of muscles. The coracobrachialis, pectoralis major, biceps and the anterior portion of the deltoid all participate in humeral forward flexion. Humeral extension is gained through the posterior third of the deltoid, scapular head of the triceps, teres major and the latissimus dorsi.

Operations to gain humeral abduction usually depend upon the transplants acting as partial but not total replacement. No muscle transplantation procedure now known will of itself functionally rehabilitate the flail scapulohumeral joint. Given a rotator cuff, however, the deltoid action can be replaced at least partially by the use of Ober's procedure[8] in which the scapular head of the triceps and the short head of the biceps are advanced toward the tip of the acromion, or by Hildebrandt's pectoralis major turnback.[4] Even without help from other muscles, Ober's procedure will improve abduction of the flail scapulohumeral joint. In general, Hildebrandt's procedure should be done only when there is at least partial activity of the musculotendinous cuff. Under that condition, especially with some remaining power in the posterior deltoid, Hildebrandt's procedure will be found very helpful. This

potential activity can be appreciated when one observes forced forward flexion in the normal shoulder. On this test the clavicular portion of the pectoralis major is clearly visible. Sometimes a combination of procedures designed to promote strength in the proper plane will be useful. For the most part however, transplants about the shoulder have been disappointing unless used in critically selected cases. Proper synchronization of the scapulohumeral and scapulothoracic force couples is necessary to accomplish abduction, and to provide satisfactory results.

SHOULDER FUNCTION

In a subluxating shoulder, occasionally shoulder tenodesis is of value. This can be accomplished by passing the tendon of the long head of the biceps through the humerus and back to the acromion. Although the tendon may sag after some time has elapsed, this procedure is very useful as a temporary measure.

When scapulothoracic musculature is satisfactory, shoulder arthrodesis may be of great help. However, in a severely paralyzed patient it is not generally a satisfactory functional procedure. If the patient's activities are in the self-care and daily habits range from a wheelchair, shoulder arthrodesis is usually contraindicated. If function of the elbow and hand is good, and the scapulothoracic musculature is satisfactory with a flail scapulohumeral musculature, unilateral shoulder arthrodesis may be performed. This procedure often proves quite satisfactory in the restoration of partial function and can add greatly to the range of arm activity. It gives strength and stability to other upper extremity motions. Shoulder arthrodesis may be helpful in securing proper hand placement and to allow the most effective use of the hands. It can provide the stable link in an otherwise ineffectual upper extremity, allowing heavy objects to be pushed or pulled. With a stable shoulder it may be possible for the patient to pull himself up from a sitting position. If such arthrodesis appears to be the necessary link to stability in an otherwise competent upper extremity, it should seriously be considered. Nevertheless, since there is some sacrifice in shoulder rotation as well as in abduction, arthrodesis should be evaluated in the light of the functional requirements of the individual patient. When loss of mobility will not seriously hamper some essential activity for the patient, fusion of the shoulder is not contraindicated.

When the scapulothoracic force couple is absent, abduction and general shoulder function is sharply impaired even though the distal musculature is good. To provide scapular fixation or motion, the muscular force couple depends upon three major lines of force. These are represented by the forward pull of the serratus anterior upon the inferior angle of the scapula, the upward rotation of the upper trapezius on the outer end of the scapula, and the lower trapezius which provides some rotation of the scapula downward and establishes stability with the assistance of the rhomboids. To accomplish this replacement, various techniques have been used. In brief, however, the serratus component may be best replaced by transfer of the pectoralis major insertion to the lower third of the vertebral border of the scapula. Other transplants that have been reported to have given satisfactory replacement of the serratus magnus component are those of the latissimus dorsi, teres major and pectoralis minor. In some instances useful scapular pre-position has been gained by the use of a fascial transplant from the scapula to the rib cage, choosing a rib two spaces cephalad, to the point of the scapular fixation.

While the experience of the authors in replacement of the lower trapezius force couple has been somewhat limited, it has been found that motion produced by this force couple can be improved by shifting the rhomboids and lower trapezius laterally (the scapula medially) by suspension with fascial strips to the erector spinae; or, by interscapular fascial fixation after the manner of Lowman. The scapula should not be fixed at its distal vertebral margin, for that would prevent rotation. When active motor replacement is not possible, it is best that static positioning be provided. Interscapular fixation provides stability in much the same manner as do the rhomboids, and may also provide some active replacement of this portion of the force couple.

The upper force couple component can be improved by lateral shift of the insertion of the levator angulae scapulae as well as by transfer of the clavicular and sternal origins of the sternocleidomastoid to the acromion. Scapular fixation to the chest wall has also been reported. This should be done only in very carefully selected cases where no decrease in upper extremity function will follow, and where the scapulohumeral component is adequate to justify sacrifice of scapulothoracic motion.

TRUNK STABILITY

Trunk stability must be provided before efficient use of an upper extremity can be made. In severely paralyzed patients trunk stability may often be achieved satisfactorily by using the back and arms of the wheelchair for support or by good corseting. Lowman's[6,7] procedure of fascial abdominal transplantation always should be considered carefully, for both crisscross and lateral transplants may afford stability of the trunk which can be of inestimable value to the patient, since it provides a base from which he may use his upper extremities. Without

such trunk support the patient is unable to lift his arm without throwing himself out of balance. Such fascial transplantation completes the line of stability necessary for suitable arm placement; without trunk stability, the arm cannot be used effectively.

One principle which should be remembered in replacement and substitution operations is that any muscle of sufficient strength can be put to a new task in another site provided it can be brought into place without sacrificing its nerve and blood supply, or if mechanically its line of pull can be instituted in a straight line. Very few transplants are successful when pulleys and angulation are necessary to form the pattern of transposition. Muscle transpositions carry no secondary risks if they are carefully executed and if the muscles chosen for transplantation are not doing an essential motor job where they are normally located.

384 Post Street, San Francisco 8 (Schottstaedt).

REFERENCES

1. Bunnell, S.: Ischemic contracture, local, in the hand, J. Bone & Joint Surg., 35:88-101, Jan. 1953.

2. Clark, J. M. P.: Reconstruction of the biceps brachii by pectoral muscle transplantation, Brit. J. Surg., 34:180-181, 1946.

3. Haines, R. W.: Laws of muscle and tendon growth, J. Anat., 66:578-585, 1932.

4. Hildebrandt, J.: Ueber eine neue Methode de Muskeltransplantation, Archiv. für Klinische Chirugie, 78:75-84, 1906.

5. L'Episcopo, J. B.: Tendon transplantation in obstetrical paralysis, Am. J. Surg., 25:122-125, July 1934.

6. Lowman, C. L.: Fascial Transplants, Edwards Brothers, Ann Arbor, Mich., 1954.

7. Lowman, C. L.: The relation of the abdominal muscles to paralytic scoliosis, J. Bone & Joint Surg., 14:763-771, 1932.

8. Ober, F. R.: An operation to relieve paralysis of the deltoid muscle, J.A.M.A., 99:2182 Dec. 24, 1932.

9. Schottstaedt, E. R., Larsen, L. J., and Bost, F. C.: Complete muscle transposition, J. Bone and Joint Surg., 37:897-918, Oct. 1955.
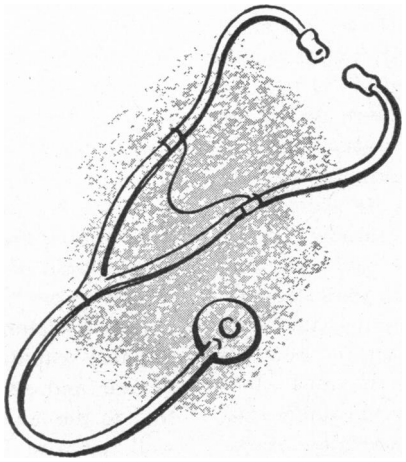
10. Steindler, A.: Tendon transplantation in the upper extremity, Am. J. Surg., 44:260-271, April 1939.