FROM A MEDICAL STUDENT

The Wilson-Mikity Syndrome

Case Report and Review of Literature

DAVID H. LEHMAN, B.A., *San Francisco*

■ *The Wilson-Mikity Syndrome is a newly described respiratory ailment of very premature infants. It is typified by its characteristic clinical course, with onset after a period of well-being, and radiologic findings of coarse infiltrates alternating with cystic changes. At least four cases have occurred in the last two years at the University of California Medical Center, San Francisco. An exemplary case is given. The pathophysiology of the syndrome appears to relate primarily to abnormal ventilation perfusion relationships resulting from uneven lung compliance. It is suggested that the syndrome results from a distortion of the normal development of the fetal lung.*

ATTENTION HAS BEEN DRAWN recently to a newly recognized disease of premature infants that was first described in 1960 by Wilson and Mikity[1] at the Los Angeles County Hospital. Since then approximately 100 cases have been reported.[2-23] The disease has been variously labeled,[2,4,5,8] but is generally referred to as the Wilson-Mikity syndrome. The syndrome occurs characteristically in very premature infants, usually weighing 1,500 grams or less at birth and with a gestational age of 30 weeks or less, although two cases have been reported in full-term infants weighing 3,100 grams and 3,700 grams at birth.[8,11] Mikity, et al[12] report an incidence of approximately 1:450 premature (2,500 grams or less) deliveries. The incidence appears to be much higher in infants weighing less than 1,500 grams at birth and probable or definite evidence of the syndrome was seen in more than half of 52 premature infants weighing less than 1,300 grams at birth.[11] There is no association with age or parity of the mother, complication of the pregnancy, or race or sex of the infant.

Clinical Course

The infants often have transient respiratory distress at birth due to asphyxia or occasionally to hyaline membrane disease. Such distress clears (or is not present at all) and strikingly, the infants almost always do well for several days up to over a month; (in one of our cases onset of symptoms did not occur until the forty-first day). The syndrome can develop within hours of birth, however. There is gradual onset of intermittent or continuous cyanosis requiring continuous oxygen therapy,

This paper received the Annual Trudeau Award of the California Thoracic Society and was presented at its 1969 annual meeting.

At the time he submitted this article, the author was a third year medical student at the University of California Medical Center, San Francisco.

From the Department of Pediatrics, University of California, San Francisco Medical Center, San Francisco.

Submitted 10 February 1969.

Reprint requests to: 1538 Tenth Ave., San Francisco 94122.

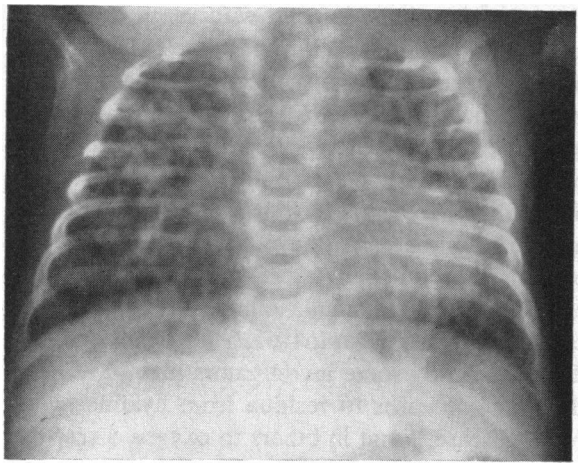

Figure 1.—At six days. The chest film shows foci of small cysts interlaced with coarse, streak-like infiltrates, typical of Stage I.

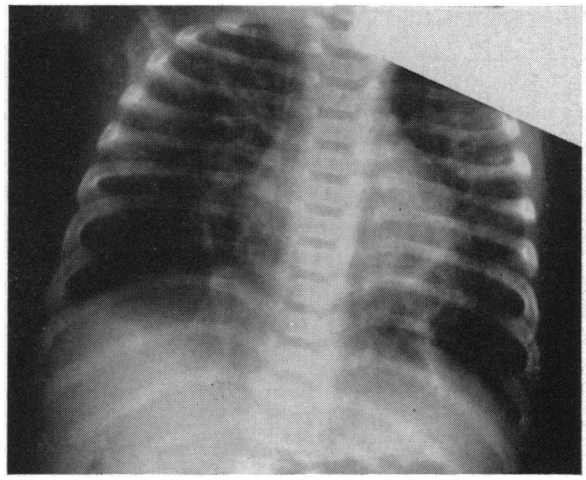

Figure 2.—At ten weeks. There is persistence of the cystic changes and reticular infiltrate in the upper lung fields. Cysts have coalesced to form blebs in the bases, which are hyperlucent and hyperexpanded. The picture is typical of Stage II.

tachypnea, and moderate retractions. The respiratory difficulties commonly increase in severity for two to six weeks. The electrocardiograms of many of the affected infants show developing right ventricle hypertrophy. Right heart failure may occur. The infants usually feed well and gain weight normally. Therapy is purely supportive and consists primarily of increased atmospheric oxygen tension; steroid treatment has not been shown to be beneficial. Approximately 75 percent of the affected infants survive. If an infant lives past six months, it will almost surely recover. Survivors improve gradually and are usually well by one year of age. There do not appear to be any long-term residua.

Radiologic Findings

The radiologic findings are characteristic; diagnosis can be made without biopsy.[12] The findings change as the disease progresses, and several stages have been described.[8,12] The first stage appears with onset of the clinical syndrome and consists of foci of cysts 1 to 4 mm in diameter throughout the lung fields, interlaced with coarse, streak-like infiltrates, 0.5 to 1 mm thick, giving the lung a "bubbly" appearance. There are no cardiovascular abnormalities.

The second stage can present two different sets of abnormalities. Mikity, et al[12] reported a second stage beginning at approximately six weeks and consisting of enlargement of the cysts at the bases to form blebs. The lower lobes become hyperexpanded and hyperlucent, and the diaphragms are flattened. Cystic changes and the reticular infiltrate persist in the upper lung fields. Alternatively, Grossman[8] told of a pattern of coarse streaks radiating from the hilus and extending particularly into the upper lung fields. Cystic foci were no longer present, though the lungs appeared decidedly hyperaerated. Second stage changes in our cases were similar to those described by Mikity, et al.[12]

In the third stage, there is complete clearing of the abnormalities, occurring from three months to two years after the onset.

Report of a Case

At least four cases of the Wilson-Mikity syndrome have occurred during the last two years at the University of California Medical Center, San Francisco. Diagnosis was made by characteristic clinical course and radiological changes. The x-ray films in the series of Mikity, et al[12] were reviewed and the radiologic findings in these four infants were believed to be consistent with that series. All infants were born prematurely, the largest having been 1,200 grams at birth, and all have survived. A representative case is briefly outlined here.

The patient was a white female weighing 850 grams at birth after 26 weeks' gestation that had been complicated only by slight first trimester bleeding. Delivery was normal. Hyaline membrane disease, with typical x-ray changes, resolved by day 4, at which time the baby was doing well and was intermittently in room air. On day 6, Stage I radiologic findings developed (Figure 1) with accompanying lethargy, retractions, tachypnea, cyanosis, and oxygen dependence. Steroid treatment

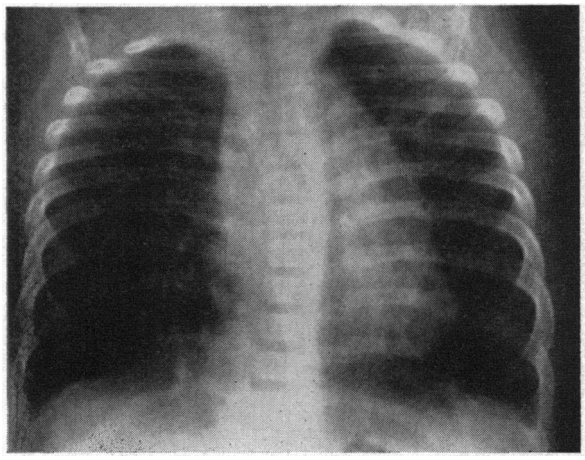

Figure 3.—At 1½ years. The x-ray is much improved, but it continues to show stringy infiltrates and hyperinflation.

was begun on day 28 without apparent improvement. There were numerous apneic spells. At ten weeks Stage II radiographic changes, as described by Mikity, et al,[12] were seen (Figure 2). An electrocardiogram at this time revealed signs of right ventricular hypertrophy. The patient began to improve by four months, oxygen tension was gradually lowered to that of room air, and the infant was discharged at five months. Roentgenographic abnormalities were resolving at that time. Multiple cultures, throughout the hospital course, were negative. At seven months of age there was an increased pulmonic closure sound and prolonged expiratory phase of respiration. At one year of age there were no respiratory signs, although pulmonic closure was still loud at 1½ years. The last roentgenogram, at 1½, was much improved but continued to show stringy infiltrate and hyperinflation (Figure 3). Weight gain was normal and the patient was doing well.

Pathology

Numerous biopsy and autopsy reports permit pathological description.[1-13,24] The lungs are of normal weight. Grossly, they show an alternating pattern of pale, aerated and darker, depressed areas, early in the course of the disease. Later they have a typical, emphysema-like, hobnail appearance. They are grossly hyperaerated and remain inflated at autopsy.

I have had opportunity to review the histologic sections of Hodgman et al.[24] Most striking is the relatively normal appearance of much of the sections. Many areas appear altogether normal. Others appear hyperinflated with rupture of septa and are adjoined by regions of collapse with juxtaposition of septa. In many places, the mesenchyme is thickened with a mononuclear infiltrate composed of several cell types, including some fibroblasts and even some smooth muscle cells. Such mesenchyme resembles that found in very immature, non-aerated lungs. Some reports emphasized fibrotic changes,[1,2,7,10] but fibrosis is now considered to be a small, unimportant part of the pathologic manifestation.[8,12,14,24] The greater fibrosis seen by some investigators may have been due in some cases to residua from hyaline membrane disease,[25] and in others to oxygen therapy.[26]

Functional Changes

The functional disturbance in the Wilson-Mikity syndrome appears to be primarily uneven ventilation with consequent abnormal ventilation-perfusion relationships.[13] This hypothesis is suggested by the discrepancy between measurements of "dynamic" and "static" lung compliance. Pulmonary compliance can be measured in several ways. Under ideal conditions it is measured when there is no air flow ("static" compliance). This can be achieved by having the patient hold his breath at different degrees of inspiration while intraesophageal (that is, transpulmonary) pressure is measured. But in infants this procedure is almost impossible to perform, for it depends on waiting until the infant spontaneously holds his breath. Moreover, there is no guarantee that cessation of air flow at the infant's mouth is not due to closure of the glottis rather than breath-holding.

Hence, compliance of infants' lungs is determined by continuous recordings of pressure-volume curves during normal tidal volume swings, without breath-holding ("dynamic" compliance). Values of pressure and volume at points of no air flow, that is, at end-inspiration and end-expiration, are used so that values will not be distorted by pressure needed to conteract resistance to air flow.

Until the 1950s and the work of Otis, et al,[27] it was generally believed that static and dynamic compliance were pretty much one and the same; and indeed in healthy persons this is true. But in adults with pulmonary disease, such as emphysema and asthma, values of dynamic lung compliance obtained are much lower than those of static lung compliance. Measurements of dynamic compliance in infants with the Wilson-Mikity syndrome are low,[6,7,13] as the sub-costal and inter-costal retrac-

tions would suggest. Although compliance varies directly with lung volume (hence the use of "specific" compliance, that is, compliance/functional residual capacity, for comparing compliance in different individuals), it has been shown that a reduction in lung volume does not account for the decrease in compliance.[6,13]

On the other hand, static compliance was normal when measured in an anesthetized, curarized infant with the syndrome,[13] and as shown at autopsy.[5] Here, then, is the same discrepancy between measurements of dynamic and static lung compliance as seen in adults with some types of lung disease. As Aherne and coworkers[13] pointed out, the work of Otis, et al[27] affords a solution to this apparent incongruity. These investigators consider lung units and their airways as analogous to electrical RC (resistance-capacitance) circuits. Each unit has a resistance (to air flow) and a compliance (capacitance). These form a product which is a constant (for that particular lung unit) and which has the dimension of time (compliance x resistance = ml/cm H_2O x sec/ml x cm H_2O = sec). An increase in the compliance or resistance of a lung unit will increase the value of the time-constant — that is, that particular unit will take longer to empty and to fill. If some time-constants are longer than others, measurements of dynamic compliance will be low, since those units with long time-constants will not have had time to respond completely to change in pressure, and air will continue to flow into and out of them (from and to units with shorter time-constants) at end-inspiration and end-expiration, respectively (so-called "pendelluft"). In this case, the dynamic lung compliance is not a valid estimate of the true lung compliance (though it does reflect respiratory work), but is indicative of variation in length of time constants in various parts of the lung. Alveolar ventilation is then uneven, since different parts of the lung require different amounts of time to empty and fill. Units with very long-time-constants will never completely empty and fill. Aherne et al[13] expressed belief that the consequent unequal ventilation-perfusion relationships and hypoventilation are responsible for the respiratory symptoms in these infants.

Additional findings support this belief. First, several observers have reported a reduced "crying" vital capacity[9,13] (although Baghdassarian, et al[5] reported it to be normal), but static inflation volume, determined under general anesthesia[13] and at autopsy,[5] was normal. The conclusion can be drawn that the rapid respirations during crying do not allow the lung units with long time constants time enough to fill. Second, these infants have CO_2 retention and resulting respiratory acidosis. Increase in P_{CO_2} can be caused only by hypoventilation of at least part of the lung, presumably that part with long time-constants. Third, the finding that the arterial desaturation is at least partially correctable with 100 percent O_2,[7,13] suggests that at least part of the lung is being hypoventilated. There do not appear to be any anatomical shunts,[7] and the fact that the P_{O_2} is only partially correctable by 100 percent O_2 implies a ventilation-perfusion defect of major proportion, though it is probably due in part to shunting through atelectatic areas. Fourth, lengthened time-constants would result in air trapping, which was found on post-mortem examination.[7] These findings all provide very convincing support for the hypothesis of Aherne et al.[13]

Burnard and coworkers[28] examined serially 33 premature infants weighing less than 1,800 grams at birth. At least ten of the infants showed abnormalities of respiratory function similar to those seen in the Wilson-Mikity syndrome, including very high resistance to airflow, early air trapping (as suggested by a drop in thoracic gas volume at one to two weeks, confirmed in premature[29] and full-term[30] newborns), a fall in dynamic lung compliance by two weeks of age only in part accountable by the drop in thoracic gas volume, and a moderate increase in P_{CO_2} by two weeks of age. In addition, seven of the infants showed roentgenographic changes similar to those described in the syndrome, although in no case did these changes progress to the "bubbly" appearance characteristic of the syndrome. In a recent study, Thibeault, et al[11] reported radiologic findings either definitely or probably typifying the syndrome in 35 of 52 infants and abnormalities similar to those seen by Burnard, et al in 13 others weighing 1,300 grams or less at birth. These findings suggest that the Wilson-Mikity syndrome results from an exaggeration of abnormal respiratory function present in all prematures.[28]

Etiology

Infection appears to have been ruled out as the etiological factor. Multiple cultures from all sites have been negative, as reported by many investigators, with only two exceptions: Type 19

ECHO virus was isolated in one case,[5] and Type 7 ECHO virus in another.[14]

Some investigators, reporting significant amounts of fibrosis, now no longer thought to be a part of the histologic manifestation (as was previously noted) sought to differentiate the syndrome from the Hamman-Rich syndrome. The Hamman-Rich syndrome has indeed occurred in young infants.[7,10] However, emphysema-like cyst formation never occurs in the Hamman-Rich syndrome, fibrotic change and septal thickening is far more prominent in the Hamman-Rich, and survival is usual in the Wilson-Mikity but unusual in the Hamman-Rich syndrome.[7] Moreover, Hamman himself reviewed the histologic sections in Wilson-Mikity syndrome and considered them to be different from those in the Hamman-Rich syndrome.[2]

Thibeault, et al[11] suggested that oxygen toxicity may play an etiologic part in the Wilson-Mikity syndrome. They cited evidence that biopsy sections in two cases of Wilson-Mikity syndrome show changes like those produced by oxygen toxicity. Indeed, radiologic findings associated with oxygen toxicity are similar to those seen in this syndrome.[31] However, there is strong contradictory evidence. Northway, et al[26] examined pathologic sections from the lungs of infants treated with respirators and high oxygen tensions for long periods (more than 156 hours). Their pathologic findings, consisting primarily of mucosal dysplasia and sloughing, increased mucus secretion, subsegmental overdistention, lymphatic dilatation and bronchiolar smooth muscle hypertrophy are not characteristic of the Wilson-Mikity syndrome. In addition, in the series of Hodgman et al,[24] which now numbers more than 30, some of the infants were never exposed to high oxygen tensions before the syndrome developed.

Burnard, et al[28] noted that the tracheobronchial tree is very compliant in premature infants, as shown by post-mortem examination of excised specimens. They suggested that focal collapse of small bronchi on expiration might occur even at very low transmural pressures. This phenomenon would not only explain many of the functional changes in premature infants, but it could also result in cyst formation (behind collapsed airways). This suggestion, however, is based only on extrapolation of data from larger to smaller airways. In addition, one would expect the smaller bronchioles to be supported by the lung parenchyma itself (in unexcised specimens), preventing collapse. Nonetheless, the hypothesis remains to be confirmed or disproved by further experimentation.

Mithal and Emery[32] found that formation of alveoli in prematures living over a week after birth was decreased by as much as 25 percent in comparison with more mature stillborns of comparable age. They suggested that this reduction in the quantity of alveoli might be the cause of the respiratory distress in the Wilson-Mikity syndrome. Building on this postulate, Baghdassarian, et al,[5] introducing the term "pulmonary dysmaturity," suggested that parts of the lung parenchyma might mature more rapidly than others. Alveolar proliferation might occur in some areas and fail in others. Where it failed, thick, relatively nondistensible septa would result. Where it occurred, septa would be normally distensible. Or in still other areas some compensatory mechanism might result in increased distensibility. Hence, there would be variable degrees of compliance throughout the lungs, which would explain the functional findings. The concept of "dysmaturity" is appropriate in that it allows for eventual maturation and recovery; but as Aherne et al[13] pointed out, it is difficult on this basis to explain the onset of the syndrome within a few hours of birth in some infants.

Craig[33] mechanically expanded lungs taken postmortem from very premature infants, including some under 1,000 grams who died at or shortly after birth. In those babies septa were thickened with mescenchyme: expansion was uniform, but compliance was reduced below that of older infants with thinner septa. These findings suggest compliance is directly related to septal thickness. In the Wilson-Mikity syndrome, then, compliance (and therefore time-constants) might vary from one part of the lung to another because of different septal thicknesses.

To understand further how "pulmonary dysmaturity" might develop, a brief review of the normal development of the prenatal lung is given here. Prenatal growth of the lung can be divided into three periods: (a) glandular — up to four months, (b) canalicular—4 to 7 months, and (c) alveolar—starting at six months.[34,36] Lung formation begins very early in fetal life as an outpouching of the foregut ventralward. This outpouching branches into a right and a left mainstem bronchus, which in turn divide through many generations.

This branching growth occurs amid a matrix of very cellular mesenchyme. At first, the pulmonary branches are widely separated by connective tissue. As growth continues, there is a relative reduction in the mesenchyme separating the bronchi, which now grow closer together.[37]

Branching of the non-respiratory bronchial system is complete by ten to sixteen weeks. The lung appears glandular because its air spaces are "blind" —they are completely lined by uninterrupted, columnar epithelium and enveloped by solid mesenchyme.[34,35,38]

The canalicular stage commences at approximately four months as the diameter of the lumen of the "glands" begins to increase. Plank,[39] working with non-retracted lungs, that is, lungs fixed *in situ* in the thorax before post-mortem retraction can occur, described this transitional stage. As lumina enlarge, the tissue between them becomes stretched and its epithelial lining is lost. As enlargement continues, the septa separating canaliculae become attenuated and eventually rupture, so that large canals are formed. Broken elastic fibers from these septa continue to protrude into the lumen, their ends thickened and contracted. (Loosli and Potter,[40] in a widely cited article, suggested that these projections represented new, developing elastic fibers.) The canaliculae do not then arise from glands that are already formed. Instead, a new system of canals is hollowed out within the existing solid tissue by tissue breakdown.

It is tempting, then, to hypothesize that "pulmonary dysmaturity" develops as a distortion and exaggeration of the normal process of canalization. This process is not always finished by the time a fetus weighs 1,500 grams,[39] and most of the infants with Wilson-Mikity syndrome are this weight or less at birth. Respiration has been shown to result in narrowing of septal walls; Craig[33] reported on premature twins who died at different times: the first died shortly after birth and had thick septa; the second died several days later, by which time the alveolar walls were as thin as those in a full-term infant. Presumably, this might be due to a quickening of the process of canalization caused by the constant stretching and relaxing of the respiring lung. Septa, already attenuated at this stage, would break down both more quickly and in greater quantity. As excessive breakdown occurred, cyst formation would occur in some places. If ventilation were even slightly uneven at birth (as is reasonable to expect, in view of intensified atelectasis in the premature,[41] and diaphragmatic breathing[28]), canalization would occur at different rates in different regions of the lung. In under-ventilated areas, thick septa would persist; in others septa would be of normal thickness; in still others, they would break down to form cysts. The resulting changes in compliance would perpetuate the process. As canalization continued, the syndrome would eventually develop, in hours, days or weeks. Canalization is seldom finished by term,[39] making understandable the occurrence of the Wilson-Mikity syndrome in full-term infants.

Support for this hypothesis is provided by the pathologic findings in two cases, reported by Weber, et al,[10] in which there were broken septa with splintered elastic fibers, barren of epithelial cells, their thickened ends protruding into alveolar lumina — which fits the conditions described by Plank.[39]

For further etiologic understanding of the Wilson-Mikity syndrome additional investigations are needed concerning the effect of respiration on the thinning of the connective tissue septa and their rupture as part of the transition from the glandular to the canalicular stage of growth.

ACKNOWLEDGEMENT

The author is grateful for aid given by W. H. Tooley, M.D., and Clayton G. Loosli, M.D.

REFERENCES

1. Wilson, M. G., and Mikity, V. G.: A new form of respiratory disease in premature infants, Am. J. Dis. Child., 99:489, 1960.
2. Kaufmann, H. J.: Über eine neue Form von Lungenfibrose bei Frühgeburten, Fortsch. Röntgenstr., 97:434, 1962.
3. Hottinger, A., Kaufmann, H. J., Weisser, D., and Wertheman, A.: Über eine seltene Lungenerkrankung Frühgeborener, Ann. paediat. (Basel), 201:13, 1963.
4. Butterfield, J., Moscovici, C., Berry, C., and Kempe, C. H.: Cystic emphysema in premature infants, New Eng. J. Med., 268:18, 1963.
5. Baghdassarian, O. M., Avery, M. E., and Neuhauser, E. D. B.: A form of pulmonary insufficiency in premature infants, Pulmonary dysmaturity?, Am. J. Roentgenol., 89:1020, 1963.
6. Burnard, E. D.: The pulmonary syndrome of Wilson and Mikity, and respiratory function in very small premature infants, Ped. Cl. No. Amer., 13(4):999, 1966.
7. Swyer, P. R., Delivoria-Papadopoulos, M., Levison, H., Reilly, B. J., and Balis, J. U.: The pulmonary syndrome of Wilson and Mikity, Pediatrics, 36:374, 1965.
8. Grossman, H., Berdon, W. E., Mizrahi, A., and Baker, D. H.: Neonatal focal hyperaeration of the lungs, (Wilson-Mikity syndrome), Radiology, 85:409, 1965.
9. Bucci, G., Iannaccone, G., Scalamandre, A., Savignoni, P. G., and Mendicini, M.: Observations on the Wilson-Mikity syndrome, Ann. Paediat. (Basel), 206:135, 1966.
10. Weber, J., Tolksdorf, M., Althoff, H.: Das Wilson-Mikity Syndrom, Klinik, Pathologie und Nosologie, Z. Kinderheilk., 98: 330, 1967.
11. Thibeault, D. W., Grossman, H., Hagstrom, J. W. C., and Auld, P. A.: Radiologic findings in the lungs of premature infants, J. Pediat., 74:1, 1969.
12. Mikity, V., Hodgman, J. E., and Tatter, D.: The radiological findings in delayed pulmonary maturation in premature infants, Progr. Pediat. Radiol., 1:149, 1967.
13. Aherne, W. A., Cross, K. W., Hey, E. N., and Lewis, S. R.: Lung function and pathology in Wilson-Mikity syndrome, Pediatrics, 40:962, 1967.

14. Sinnette, C. H., Bradley-Moore, A. M., Cockshott, W. P., and Eddington, G. M.: Wilson-Mikity respiratory distress syndrome, Arch. Dis. Child., 42:85, 1967.

15. Ibrahim, J. M., and Russell, A.: Late prolonged respiratory distress syndrome, Proc. Roy. Soc. Med., 59:487, 1966.

16. Meadows, J. A., Jr.: Two cases of rare causes of respiratory distress in the newborn, J. Med. Assoc. Alabama, 37:1039, 1968.

17. Ringel, J., Tomosova, J., and Hub, M.: Wilson-Mikity Syndrom eine spezielle Form der interstitiellen Pneumonie der Frühgborenon, Sborn. Ved. Prac. Lek. Fak. Karlov Univ., 10:55, 1967.

18. Hruskovic, I., and Somsky, M.: Pl'uchy syndrom Wilson-Mikity, Cesk. Pediat., 21:1110, 1966.

19. Faure, C., Grodemange, M., and Alison, F.: L'emphysème bilatéral du prémature, Ann. Radiol. (Paris), 9:731, 1966.

20. Javett, S. N.: The Wilson-Mikity syndrome—Case report, Helv. Pediat. Acta, 20:325, 1965.

21. Gwinn, J. L., and Parnes, G. R.: Radiological case of the month, Amer. J. Dis. Child., 110:87, 1965.

22. Freycon, F., and Freycon, M. T.: La maladie de Wilson et Mikity, Pediatrie, 19:773, 1964.

23. Reich, J., Heber, J., and Süss, K. J.: Über eine seltene Erkrangung des fibroelastischen Lungengerüstes Frühgeborener mit Emphysem, Kinderarztl. Prax., 33:217, 1965.

24. Hodgman, J. E., Mikity, V. G., Tatter, D., and Cleland, R. S.: Chronic respiratory distress in the premature infant: Wilson-Mikity syndrome, Pediatrics, 44:179, 1969.

25. Shepard, F. M., Johnston, R. B., Jr., Klatte, E. C., Burko, H., and Stahlman, M.: Residual pulmonary findings in clinical hyaline-membrane disease, New Eng. J. Med., 229:1063, 1968.

26. Northway, W. H., Jr., Rosan, R. C., and Porter, D. Y.: Pulmonary disease following respirator therapy of hyaline-membrane disease, New Eng. J. Med., 276:357, 1957.

27. Otis, A. B., McKerrow, C. B., Bartlett, R. A., Mead, J., McIlroy, M. B., Selberstone, N. J., and Radford, E. P.: Mechanical factors in distribution of pulmonary ventilation, J. Appl. Physiol., 8: 427, 1956.

28. Burnard, E. D., Grattan-Smith, P., Picton-Warlow, C. G., and Grauaug, A.: Pulmonary insufficiency in prematurity, Aust. Paediat. J., 1:12, 1965.

29. Thibeault, D. W., Wong, M. M., and Auld, P. A. M.: Thoracic gas volume changes in premature infants, Pediatrics, 40:403, 1967.

30. Nelson, N. M., Prod'hom, L. S., Cherry, R. B., Lipsitz, P. J., and Smith, C. A.: Pulmonary function in the normal infant's lung, J. Clin. Invest., 42:1850, 1963.

31. Northway, W. H., Jr., and Rosan, R. C.: Oxygen therapy hazards in the neonate, Hosp. Practice, 4:59, 1969.

32. Mithal, A., and Emery, J. L.: The postnatal development of alveoli in premature infants, Arch. Dis. Child., 36:449, 1962.

33. Craig, J. M.: Distensibility curves and expansion patterns of newborn lungs, Amer. J. Dis. Child., 106:174, 1963.

34. Reid, L.: The embryology of the lung, *in* Ciba Foundation Symposium: Development of the Lung, de Reuck, A. V. S., and Porter, R., ed., Little, Brown and Co., Boston, 1967, p. 109.

35. Dubreuil, G., Lacoste, A., and Raymond, R.: Observations sur le dévelopment du poumon humain, Bull. d'histol. appliq. à la physiol., 13:235, 1936.

36. Loosli, C. G., and Potter, E. L.: The prenatal development of the human lung, Anat. Rec., 109:320, 1951.

37. Potter, E. L.: Pathology of the Fetus and the Infant, Year Book Medical Pub., Chicago, 1961.

38. Engel, S.: The Prenatal Lung, Pergamon Press, Oxford, 1966.

39. Plank, J.: A morphological contribution to the development of the human lung: Observations in the non-retracted lung, *in* Ciba Foundation Symposium: Development of the Lung, de Reuck, A. V. S., and Porter, R., ed., Little, Brown and Co., Boston, 1967, p. 156.

40. Loosli, C. G., and Potter, E. L.: Pre- and postnatal development of the respiratory portion of the human lung, with special reference to the elastic fibers, Am. Rev. Resp. Dis., 80:Suppl. 5 July 1969.

41. Avery, M. E.: The Lung and Its Disorders in the Newborn Infant. W. B. Saunders Co., Philadelphia, 1968.

42. Agostoni, E.: Volume-pressure relationships of the thorax and lung in the newborn, J. Appl. Physiol., 14:909, 1959.

43. Bucher, U., and Reid. L.: Development of the intrasegmental bronchial tree: The pattern of branching and development of cartilage at various stages of intra-uterine life, Thorax, 16:207, 1961.

44. Boyden, E. A., and Tompsett, D. H.: The changing patterns in the developing lungs of infants, Acta Anat., 61:164, 1965.

45. Dunhill, M. S.: Postnatal growth of the lung, Thorax, 17:329, 1962.

EMERGENCY MANAGEMENT OF MASSIVE UPPER GASTROINTESTINAL HEMORRHAGE

"Of particular value in the emergency management of patients with massive upper gastrointestinal hemorrhage is rapid passage of a nasogastric tube, particularly if the person hasn't had hematemesis. It's vital to know whether there is blood in the stomach on admission to the hospital. Also the tube can be used therapeutically with periodic irrigation of an iced Maalox and saline mixture; and the tube can be kept on suction which gives information regarding rate of bleeding and whether the bleeding has stopped. Finally the nasogastric tube can be used to remove acid and pepsin from the gastric contents. . . .

"I've mentioned some therapeutic uses of the nasogastric tube, but it has diagnostic uses, too. The tube can be put down and aspirated at selected levels—namely, the lower esophagus and the stomach; and if no blood is found in the stomach, it means either that the bleeding is stopped or that the site of bleeding is below the pylorus—coming, of course, from the duodenum or the upper small bowel."

—DOUGLAS A. FARMER, M.D., New Haven

Extracted from *Audio-Digest Surgery,* Vol. 16, No. 1, in the Audio-Digest Foundation's subscription series of tape-recorded programs.