Refer to: Williams RR, Schweitzer RJ: Clear-cell adenocarcinoma of the vagina in a girl whose mother had taken diethylstilbestrol. Calif Med 118:53-55, June 1973

Clear-Cell Adenocarcinoma of the Vagina in a Girl Whose Mother Had Taken Diethylstilbestrol

ROBERT R. WILLIAMS, MD
ROBERT J. SCHWEITZER, MD
Oakland

THE REPORT BY HERBST AND SCULLY[1] in 1970 of a cluster of seven cases of adenocarcinoma of the vagina in adolescents is of singular importance. Six of the cancers were of clear-cell type while the seventh was endometrioid. These lesions were diagnosed and treated in the interval of 1966 through 1969. In a later retrospective investigation, using matched controls for eight patients, Herbst et al[2] identified a statistically significant relationship between the maternal use of diethylstilbestrol or related congeners and the occurrence later of postmenarchial vaginal cancer in their daughters.

Greenwald et al[3] further reported five cases of primary vaginal adenocarcinoma occurring in postmenarchial adolescents under the age of 20 years. These cases were collected from the New York State Cancer Registry and occurred in the period 1950 through 1970. In all cases the mothers of these patients had received synthetic estrogens during early pregnancy.

These observations document lucid examples of transplacental carcinogenesis induced by maternal administration of synthetic nonsteroidal estrogen compounds.

The following case is illustrative of the delayed association of administration of synthetic nonsteroidal estrogen to mothers in early pregnancy with the postmenarchial onset of vaginal adenocarcinoma in their offspring.

From the Departments of Pathology and Surgery, Peralta Hospital, Oakland.

Submitted March 13, 1973.

Reprint requests to: R. R. Williams, MD, Peralta Hospital, 450 - 30th Street, Oakland, Ca. 94609.

Report of a Case

The patient, aged 18, was first examined in October 1970 because of irregular vaginal bleeding. On self-examination she had discovered a thickening at about mid-vagina. Biopsy of the posterior vaginal wall was interpreted microscopically as adenocarcinoma, probably mesonephric in origin.

When the patient was admitted to hospital November 22 1970, the vaginal bleeding had ceased. The past history was unremarkable. Menarche had occurred at age 13 with regular periods usually of six days' duration. There had been no previous abnormal vaginal bleeding. Neither hormones nor oral contraceptives had been administered.

The patient's father as well as three brothers and one sister were living and well. Her mother had died of unknown cause. It was verified that the patient's mother gave a history of early miscarriage. During the first four months of the pregnancy which resulted in delivery of the patient at term, the mother had been given diethylstilbestrol orally, 25 mg four times daily.

Pelvic examination revealed circumferential thickening and induration of the posterior vaginal wall. The abnormal area was situated about 3 cm above the introitus and extended to the lateral aspects. On visualization, the area was nodular to granular and discolored by irregular hemorrhages. The lesion extended circumferentially over the posterior mid-vaginal surface from about 3 o'clock to 10 o'clock. There were small granulating areas on the portio anteriorly near the os and within the anterolateral fornices. Pelvic and rectal findings were otherwise normal. Extensive studies, including serum chemical determinations, peripheral blood cell counts, urinalysis, a chest roentgenogram, a skeletal survey, an intravenous pyelogram and cystoscopic as well as proctoscopic examination, were all essentially normal.

On November 24, following confirmation of the original biopsy diagnosis, a Wertheim hysterectomy with right salpingo-oophorectomy, vaginectomy, resection of the anterior rectal segment and including pelvic lymphadenectomy, was performed. The left oviduct and ovary were preserved. Sigmoid colostomy, appendectomy and vaginal reconstruction were also carried out.

The main pathological specimens consisted of the uterus, right oviduct and ovary, the vagina and a segment of posterior introital skin as well as

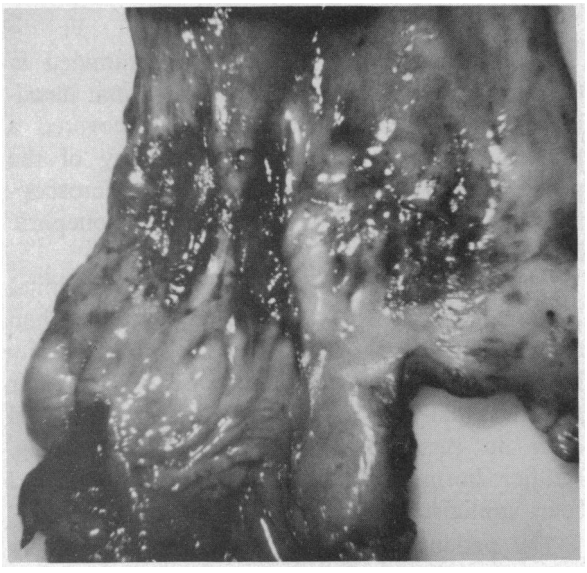

Figure 1.—Excised vagina, showing circumferential thickening, nodularity and hemorrhages due to the tumor.

separately received pelvic lymph node dissections. Significant findings were limited to the vaginal surface (Figure 1). The posterior vaginal wall approximately 4 cm above the introitus was thickened, indurated and nodular. There were patchy superficial vaginal mucosal hemorrhages. Moderate circumferential erosion of the cervical portio was present near the external os. The uterus, right oviduct and ovary as well as the pelvic lymph nodes and appendix were grossly normal.

Microscopical examination of the vaginal tumor revealed clear-cell adenocarcinoma confined to the vaginal wall (Stage I). The lesion appeared superficial in origin, deeply infiltrative and irregularly ulcerated at the surface. The epithelial configurations were solid, tubular, ductular, often cystic and frequently papillary (Figure 2). The individual tumor cells were quite large, with pleomorphic often gigantic and frequently multiple nuclei. Nucleoli were conspicuous and occasional mitoses were observed. The cytoplasm was variably clear to dense. Periodic acid Schiff stains confirmed abundant cytoplasmic and lumenal glycogenic material. Adenosis was present and manifest by multiple benign glands scattered widely beneath the mucosal lining at the margins of the adenocarcinoma. These resembled normal glands of both cervical and endometrial type (Figure 3). The adenosis as well as the clear-cell adenocarcinoma were considered to be of mullerian origin. There were no infiltrations of lymphatic spaces by the tumor, and sections of all of the pelvic lymph nodes were free of metastasis. The sections from the cervix showed pronounced epithelial erosion with chronic granulation tissue formation extending into the portio, and were otherwise benign.

The patient progressed normally and was discharged December 1, the sixteenth postoperative day. After subsequent convalescence she was readmitted January 28 1971 for sigmoid colostomy closure with end-to-end anastomosis. She has remained well.

Discussion

In the original report including six cases of clear-cell adenocarcinoma of the vagina, Herbst and Scully[1] indicated that in one patient, 16 years of age, the lesion was inoperable and she died five months after biopsy. One additional patient was apparently cured by local excision. The remaining four patients were treated by Wertheim resections with vaginectomy and pelvic lymphadenectomy and were considered cured.

In Greenwald's[3] series of five cases, three

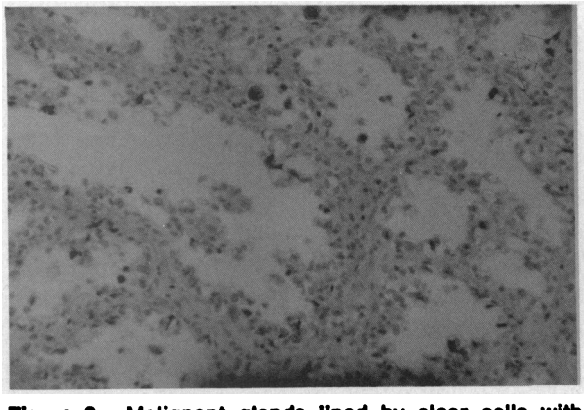

Figure 2.—Malignant glands lined by clear cells with occasional hobnail cells (× 100).

Figure 3.—Adenosis with ectopic benign endocervical type gland within vagina (× 100).

patients died in advanced stages of the disease. Diagnosis had been made within two months of the onset of symptoms in all three. The fourth patient had symptoms for 18 months before treatment by anterior exenteration, vaginectomy and pelvic lymphadenectomy. The fifth patient had had symptoms for five months before radical hysterectomy and vaginectomy were carried out. The ovaries were left intact and she was considered cured.

In a recent report of 91 registry cases of clear-cell adenocarcinoma of the female genital tract, Herbst et al[4] included 53 cases primarily of vaginal origin. Survival data according to staging were available in 43 cases. All of 28 patients in Stage I survived. Three of 12 with Stage II were dead, and all three with Stage III disease died. The overall series of vaginal adenocarcinomas showed 13.7 percent mortality. By comparison, six of twenty-two patients with primary clear-cell adenocarcinoma of the cervix have died (27.3 percent mortality). Follow-up periods were less than two years in a number of cases in both series.

The foregoing data all reflect the high morbidity and mortality in patients with clear-cell adenocarcinoma as well as the necessity for early detection and radical surgical treatment. There are reasonable indications that the ovaries can be safely spared and that vaginal reconstruction will restore sexual function.

Herbst[4,5] quite conservatively has withheld the conclusion that administration of diethylstilbestrol and congeners during early pregnancy of the mothers of these patients is the sole etiologic factor. The duration and concentration of dosage in relationship to embryologic development of the vagina in the first trimester appear as the prime circumstances predisposing to later onset of clear-cell cancer. Other hormonal and environmental influences may be causally related. It must be noted in eight of the 69 cases in Herbst's[5] series in which maternal histories could be elicited there were no records of stilbestrol therapy. Earlier, Plaut and Dreyfuss[6] as well as Hertig and Gore[7] documented the relationship of adenosis as a precursor stage to the development of adenocarcinoma within the vagina. Hertig and Gore in particular related adenosis and vaginal adenocarcinoma to embryonic vestiges of mullerian structures. Neither Plaut and Dreyfuss nor Hertig and Gore attributed these findings to administration of nonsteroidal estrogen compounds.

Because of widespread administration of diethylstilbestrol and congeners in treating high risk pregnant patients in the 1940's and 1950's, hundreds of thousands of young female patients are now theoretically at risk. Very likely, vaginal and cervical adenocarcinoma will be seen to occur with increasing frequency as this select group remains under the continuous stimulus of ovarian produced estrogens. It will be of critical interest to further evaluate the effects of increasing age, administration of estrogens, other hormones, hormonal contraceptives and pregnancies upon the incidence of malignant disease in this group even though risk factors may seem to be low for individuals.

Meanwhile, we are obliged to view abnormal vaginal bleeding and related symptoms in postmenarchial patients with greater concern and to perform careful cervical and vaginal examinations in these cases. We should attempt further to identify patients who are at risk by appropriate review of the obstetrical histories of the mothers concerned.

It appears that the use of stilbestrol as a postcoital contraceptive may no longer be prudent in view of its possible role in carcinogenesis.

Summary

In the present case, vaginal adenocarcinoma occurred in a young woman years after her mother had taken diethylstilbestrol during pregnancy. As there are many hundreds of thousands of young women currently at risk, we are obliged to watch for and promptly investigate irregular bleeding and other vaginal symptoms in this group. Attempts should be made to trace the offspring of mothers who received diethylstilbestrol during pregnancy in order that regular vaginal examinations may be made.

REFERENCES

1. Herbst AL, Scully RE: Adenocarcinoma of the vagina in adolescence—A report of 7 cases including 6 clear-cell carcinomas (so-called mesonephromas). Cancer 25:745-757, 1970

2. Herbst AL, Ulfelder H, Poskanzer DC: Adenocarcinoma of the vagina. N Engl J Med 284:878-881, 1971

3. Greenwald P, Barlow JJ, Nasca PA, Burnett WS: Vaginal cancer after maternal treatment with synthetic estrogens. N Engl J Med 285:390-392, 1971

4. Herbst AL: Stilbestrol and vaginal cancer in young women. Cancer 22:292-295, 1972

5. Herbst AL, Kurman RJ, Scully RE, Poskanzer DC: Clear-cell adenocarcinoma of the genital tract—Registry report. N Engl J Med 287:1259-1264, 1972

6. Plaut A, Dreyfuss ML: Adenosis of vagina and its relation to primary adenocarcinoma of the vagina. Surg Gynec Obstet 71: 756-765, 1940

7. Hertig AT, Gore H: Tumors of the female sex organs Part 2—Tumors of the vulva, vagina and uterus, *In* Atlas of Tumor Pathology. Armed Forces Institute of Pathology, 1960, p62