Leptospirosis complicated by fatal intracerebral haemorrhage

Leptospirosis is a potentially fatal bacterial disease that has traditionally been associated with occupations such as mining and farming, in which the risk of contact with contaminated rodent urine is fairly high.[1] We describe a patient who contracted leptospirosis while on a walking holiday in the inner Hebrides. Despite early diagnosis and apparently successful initial treatment he died after a spontaneous intracerebral haemorrhage.

Case report

A 39 year old man was transferred to Glasgow from Islay, an island in the inner Hebrides. He had collapsed while walking in the hills two days previously and had been admitted to the local hospital confused, dehydrated, and shocked. He was rehydrated and, on arrival in Glasgow, seemed well.

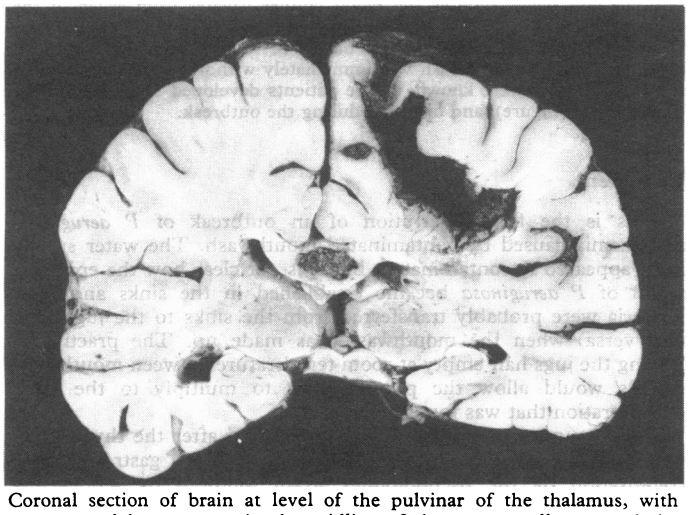

Coronal section of brain at level of the pulvinar of the thalamus, with unconnected haematomas in the midline of the corpus callosum and the white matter of the right parietal lobe.

He began to vomit overnight and became jaundiced. Deepening jaundice was accompanied by diarrhoea, profuse vomiting, hiccups, calf muscle pains, iridocyclitis, and subconjunctival haemorrhages.

Haemoglobin concentration, differential white cell count, erythrocyte sedimentation rate, coagulation screen, and fibrin degradation products were all normal. The platelet count was reduced to 69×10^9/l but rose to 200×10^9/l one week after admission. Routine biochemical tests on the day after admission gave the following: urea 36 mmol/l (216 mg/100 ml), creatinine 643 μmol/l (7·3 mg/100 ml), bilirubin 196 μmol/l (11·5 mg/100 ml), alkaline phosphatase 108 U/l, serum aspartate aminotransferase 1884 U/l, serum alanine aminotransferase 2796 U/l, and creatine kinase 9257 U/l. Results of serological tests for hepatitis A and B and routine viral and brucella titres proved negative. Early the next day fresh specimens of blood and urine were examined under dark ground microscopy. No organisms were seen in the urine, but leptospires were identified in the blood sample by their characteristic morphology and "paddle wheel" motility. Two guinea pigs were inoculated intraperitoneally with this infected blood.

After diagnosis treatment with intravenous benzylpenicillin (2 megaunits four times daily) was started. His clinical state steadily improved, and by the 12th day serum creatinine concentration had fallen to 169 μmol/l (1·9 mg/100 ml), bilirubin concentration to 61 μmol/l (3·6 mg/100 ml), and serum aspartate aminotransferase activity to 108 U/l. That evening he developed slurring of speech and left sided weakness; within 30 minutes he was in coma, with a fixed dilated right pupil. Computed tomography showed a right frontal haematoma, with massive shift of midline structures to the left. The platelet count was 69×10^9/l, and a coagulation screen was normal. Despite prompt evacuation of the haematoma he died 19 days postoperatively. At necropsy the brain weighed 1320 g and showed evidence of raised intracranial pressure. In addition to the evacuated haematoma several satellite haematomas measuring a few millimetres in diameter were present, one of which was in the splenium of the corpus callosum (figure). Histological examination of the cerebral vessels did not show any evidence of vasculitis.

The two guinea pigs died three weeks after inoculation with infected blood. At necropsy both animals showed pathological changes of leptospirosis and the presence of leptospires was confirmed by Dieterle's method in spleen, liver, and kidneys. No serotype was obtained because of autolysis. Leptospira titres in serial samples of the patient's serum later proved to be negative.

Comment

The clinical picture in this case was that of *Leptospira icterohaemorrhagiae*,[2] although confirmation of the serotype was not obtained. Serological tests may give negative results even in proved infection, as here.[3] Intracerebral haemorrhage complicating leptospirosis has been reported in two cases.[4] Our patient had multiple areas of intracerebral haemorrhage despite normal coagulation and a platelet count that never fell below 69×10^9/l. He was not hypertensive and did not have evidence of a vascular anomaly or mycotic aneurysm. Cerebral vasculitis or direct spirochaete invasion of the vessel walls may have been responsible for these lesions.

Rapid diagnosis of leptospirosis on clinical and laboratory criteria is essential for early inception of specific antibacterial treatment. Nevertheless, intracerebral haemorrhage is a rare but important complication that may occur in the recovery phase despite normal coagulation state and platelet count.

We thank Professor D I Graham of the department of neuropathology, Institute of Neurological Sciences, Glasgow, for his advice and help.

1 Leptospirosis Reference Laboratory and Communicable Disease Surveillance Centre (Public Health Laboratory Service). Leptospirosis in man, British Isles, 1982. *Br Med J* 1983;**287**:1365-6.
2 Sitprija V. Infections: leptospirosis. In: Weatherall DJ, Ledingham JGG, Warrell DA, eds. *Oxford textbook of medicine*. Oxford: Oxford University Press, 1983:297-300.
3 Adler B, Faine S. The antibodies involved in the human immune response to leptospiral infection. *J Med Microbiol* 1978;**2**:387-400.
4 Lessa I, Cortes E. Cerebrovascular accident as a complication of leptospirosis. *Lancet* 1981;ii:1113.

(*Accepted 26 September 1984*)

Western Infirmary, Glasgow G11 6NT
MARGARET A FORWELL, MRCP, medical registrar
PENELOPE J REDDING, MRCPATH, senior registrar in bacteriology
MARTIN J BRODIE, MD, MRCP, consultant clinical pharmacologist

Institute of Neurological Sciences, Southern General Hospital, Glasgow
DOUGLAS DE R GENTLEMAN, BSC, FRCS, registrar in neurosurgery

Correspondence to: Dr M J Brodie.

Non-accidental injury in children: two cases of concealment of self injury

People who work with children have to be aware of many explanations for children's injuries. Roberton *et al* showed that up to 60% of children aged 3 may show signs of recent injury.[1] Meadow described children who are continually subjected to medical investigation because of artefacts caused by their parents.[2] Non-accidental injury inflicted by others is well documented,[3] but we present two cases of concealed self injury, in which the blame for injury was attributed to others.

Case reports

Case 1—A 6 year old girl lived with foster parents, having been taken into care when aged 3 because of her mother's chronic mental illness. One of us (RB) saw her, her foster parents, and a social worker because on several occasions she had been found at school to have bruises on her legs. The head teacher had reported the bruising to the school medical officer and the foster parents, who were outraged at the suggestion that they had injured her. She was not forthcoming, but would talk about life at school and home. At a subsequent interview she showed how she bruised herself by hitting the inner aspects of both thighs and calves with her fist. Discussion with the foster parents showed that they had difficulties in verbalising their anger. They had suspected that the girl might be injuring herself but could not be sure and had not known what to do. As they could not build a trusting relationship sufficiently quickly they thought that she should be removed from their care because of the accusations made by school staff and other authorities. She had to return to institutional life.