THE FUNCTION OF THE VERTEBRAL VEINS AND THEIR RÔLE IN THE SPREAD OF METASTASES*

OSCAR V. BATSON, M.A., M.D.

PHILADELPHIA, PA.

FROM THE GRADUATE SCHOOL OF MEDICINE, UNIVERSITY OF PENNSYLVANIA, PHILADELPHIA, PA.

METASTATIC ABSCESSES and metastatic tumors can appear in locations that do not seem to be in line of direct spread from their primary focus. There is even a regularity of distribution of these paradoxic metastases. Empirically, the roentgenologist makes a diagnosis of primary carcinoma of the prostate when he finds a certain peculiar distribution of bone lesions in the pelvis. Adequate explanation has not been forthcoming for the typical and peculiar distribution of these metastatic lesions. The pattern, to me, is not at all that of the nerve sheaths of the area as suggested by Warren, *et al.*[1] It is not the pattern of lymph vessel distribution. The only anatomic system into which this pattern fits is the system of veins which, in its plexiform ramifications, infiltrates and invests the sacrum, the lumbar spine, and the adjacent wings of the ilia. Several years ago, I suggested that the architecture of this plexus of veins could be explored by taking advantage of the pelvic anastomoses of the deep dorsal vein of the penis. The connections and the collateral circulations of this vein are identical with those of the prostatic plexus of veins with which it connects. Valves in the veins of this region are exceedingly variable. All valves present permit flow toward the sacral venous plexus. Injections were first made in 1937. A preliminary report was read before the Conference of Eastern Radiologists, in Philadelphia, January 29, 1938, under the title of "The Veins of the Sacrum in Relation to Metastatic Carcinoma from the Prostate." This work has been continued and extended. Injections and corrosion preparations of the vessels of the head and neck, already completed, formed an invaluable background for this study. The dissemination of infections and tumors from organs in other regions by the veins about the spine has also been considered. This has led to a better appreciation of the rôle of the vertebral veins in normal physiology.

CADAVER INJECTION EXPERIMENTS

Experiment 1.—In our first injection experiment we lifted the dorsal vein of the penis, in an adult cadaver, near the symphysis pubis and injected a thick radiopaque material toward the pelvis. Specifically, we used Weber's,

* Part of the material of this paper was given in an address before the Philadelphia Laryngologic Society, March 5, 1940, under the title, "The Circulation of the Head, Especially Venous, with Reference to Osteomyelitis, Brain Abscess and Malignant Metastasis." Part was also presented before the Philadelphia Neurologic Society, March 22, 1940, under the title, "The Cerebrospinal Veins."

Submitted for publication June 5, 1940.

King's yellow, artist's tube water color. This was selected because its brilliant color allows it to be readily followed in tissues; further, it is radiopaque. The course and progress of the injection was followed under the fluoroscope. The mass entered the prostatic plexus of veins, passed along vessels of the lateral pelvic wall into the common iliac vein of either side and then to the vena cava inferior. As can be seen from the accompanying roentgenogram (Fig. 1) the right iliac artery compressed the vein at the point at which it crossed it. The lateral sacral veins are well injected. In the stereoscopic films of this pelvis, the material can be followed into the bone and into the sacral canal. Some material spread into the wings of the ilium. These

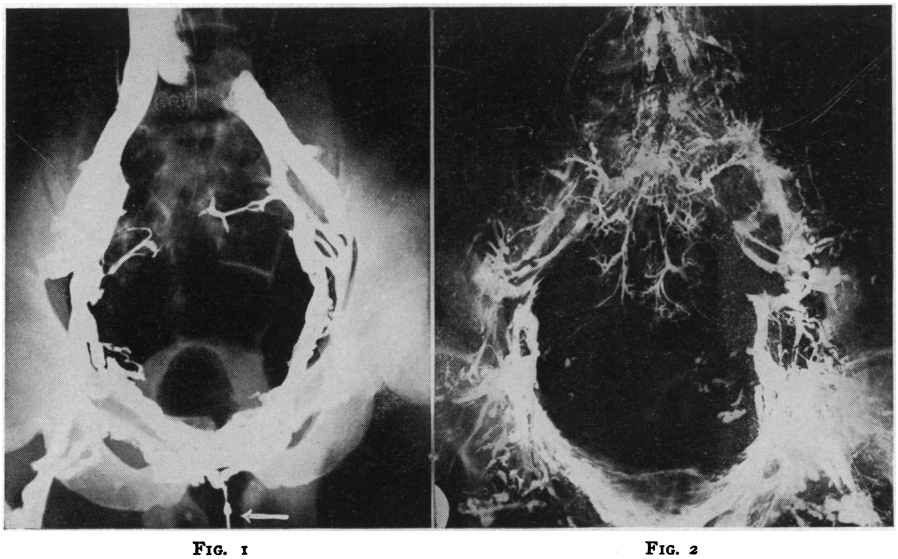

FIG. 1 FIG. 2

FIG. 1.—Anteroposterior roentgenogram of pelvis of male cadaver following the injection of thick radiopaque material into the deep dorsal vein of the penis. Note the extension of the injected mass into the sacrum.

FIG. 2.—Anteroposterior roentgenogram of pelvis of a male cadaver injected with a thin radiopaque material through the deep dorsal vein of the penis. The injected material has rather completely infiltrated the venous circulation of the pelvis itself.

roentgenograms give us a pattern which seems an exact replica of the pattern made by the early spread of carcinoma of the prostate. It was surmised that the parallelism would be even more striking with a more complete injection.

Experiment 2.—In the next cadaver, in order to secure a good injection of vessels of small caliber, a "fine" or thin injection mass was used. We employed Weber's artist's water color vermilion because in our experience it casts an excellent roentgenographic shadow in extreme dilutions. This preparation of the native sulphide of mercury was diluted with water until it was of the consistency of a light machine oil. The injection was again made into the dorsal vein of the penis under fluoroscopic control. As before, the cadaver was in the dorsal recumbent position. We used an ordinary 20 cc. glass syringe and light pressure with the thumb or index finger. No resistance to injection was encountered; at times the plunger would close part way of

itself. This time, to our surprise, none of the material reached the inferior vena cava but instead spread out in the veins in and about the sacrum itself. The veins of the ilium and those of the lower lumbar spine were also injected.

This injection still better duplicated the pattern of metastatic spread from the prostate but it raised the question as to why the mass did not enter the vena cava inferior. The mass was thin and met with no resistance in the veins about the dura and those in and about the vertebrae. The cadaver was in the dorsal recumbent position and hence the vena cava inferior was at a level several centimeters higher than those veins that were so readily filled. The heavier, more viscid mass in the first injection spread more rapidly in the channels of large caliber. To study further this vertebral spread, it was decided to use a larger quantity of the thin mass for the next injection.

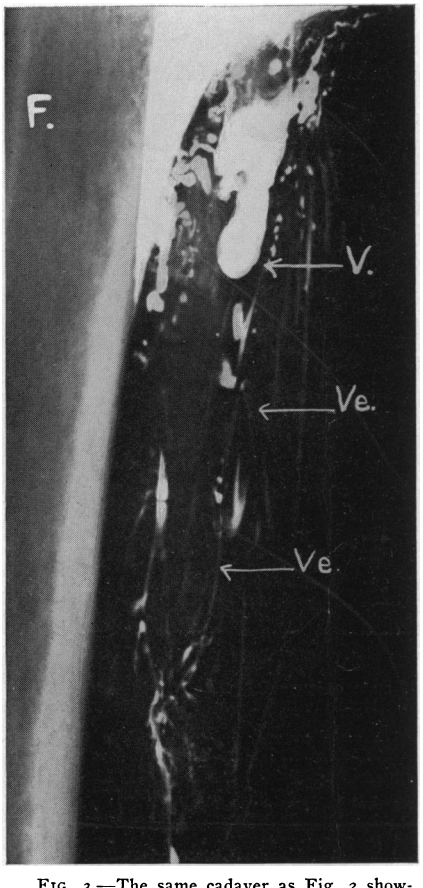

FIG. 3.—The same cadaver as Fig. 2 showing the injection of the venae vasorum of the femoral vessels. F, femur; V, valve; Ve, venae vasorum.

Experiment 3.—A cadaver was prepared as before. Fluoroscopic control was used, and after the injection of measured amounts of mass, roentgenograms were made. At no time did the fluid enter the caval system of veins (Fig. 2). The material progressed up the spine through successive anatomic regions. Many intercostal veins were filled as well as the veins of the bony pelvis.

When the amount of injection mass was increased to a total of 200 cc., the material attained the base of the skull and entered the cranial cavity. The mass also extended along fine straight vessels into the right thigh (Fig. 3.). These were found to be vasa vasorum, or, more specifically, venae vasorum of the femoral vessels. Valves prevented the filling of other, larger veins of the thigh.

Although the vertebral plexus of veins of the upper thoracic and cervical regions was familiar ground from our earlier preparations, we were not prepared for this extensive filling of the vertebral veins and the by-passing of the caval veins. This specimen furnished a composite picture of the metastatic pattern of advanced cases of carcinomatosis with primary origin in the prostate.

Repeated experience has shown that the extent and course of this injection was not an accident. It has been made repeatedly and the course examined roentgenographically and by dissection. This method of venous injection has for two years been routine in the preparation of male cadavera for dissection in this laboratory. We use a latex rubber mass[2] and expect to find fairly well filled such veins and sinuses of the cranial cavity as the superior longitudinal sinus, the cavernous sinus, Trolard's anastomotic vein and others.

ANIMAL INJECTION EXPERIMENTS

Our next interest was to see if this pattern of venous flow could be duplicated in a living animal or if it was but an artifact of cadaveric experiment. This entire system of epidural and vertebral veins has a free and rich anastomosis at each spinal segment with the veins of the thoracico-abdominal cavity. It is a system of veins without valves except in minor connecting channels. The pressure in the system is very low. With every compression of the trunk, such as is done many times daily in straining, in lifting, in coughing, in holding one's breath, it seemed to me that the intra-truncal pressure would be raised to a sufficient height so that blood would flow, not into the inferior vena cava, but into this vertebral system of veins. In order to test this hypothesis the following experiment was carried out on the monkey:

Animal Experiment 1.—With an aseptic technic and sodium amytal as an anesthetic, the deep dorsal vein of the penis of a Macaccus Rhesus monkey was isolated and a small cannula inserted. The cannula tip was directed toward the pelvis. Colloidal thorium dioxide, prepared for roentgenologic diagnosis, was injected with a hypodermic syringe into this cannula. The roentgenogram (Fig. 4A) shows that the material passed into the pelvis, followed around the pelvic wall and ascended the trunk by means of the inferior vena cava. We feel that these roentgenograms represent the ordinary course of flow during trunk muscle inactivity. In order to, in part, simulate conditions of increased intra-abdominal pressure such as produced in coughing or straining, a towel was tied about the monkey's abdomen and an injection was again made (Fig. 4B). Under this condition, while some of the material entered the inferior vena cava it ascended only part way; some of the thorium medium passed into the vertebral system of veins and can be followed in the roentgenogram past the zone of compression into the vessels of the thoracic spine and out into the lower intercostal veins. Here then, in the living animal, under simulated physiologic conditions, we have a flow which parallels the injection made in the human cadaver, and one which duplicates the pattern of prostatic carcinoma spread.

Animal Experiment 2.—This experiment was repeated on a second monkey with identical results. These results were so clear-cut that it did not seem necessary to enlarge the series.

These experiments indicate that during the Valsalva maneuver, namely, compression of the chest and abdomen with the larynx and other sphincters closed, not only is the blood prevented from entering the chest by way of veins, but blood is actually squeezed out of the intra-abdominal veins into the vertebral vein system. The increase in intraspinal or intracranial pressure during the Valsalva maneuver or during its physiologic counterpart—coughing, sneezing, *etc.*—is, therefore, active and not passive. It is possible that the intrathoracic and the intra-abdominal pressures may not always parallel each other. Hamilton *et al.*[3] studied coughing, *etc.*, but were concerned with the arterial blood pressure and the spinal fluid pressure and not with venous pressure. It should be pointed out that any condition accompanied by coughing or straining would tend to increase the flow into this venous system, and

this may account for the high incidence of cranial metastases in lung abscess and bronchiogenic carcinoma.

SUMMARY.—The injections in the live animal were not essentially different from those obtained in cadavera, and show that the cadaver injections were not artifacts.

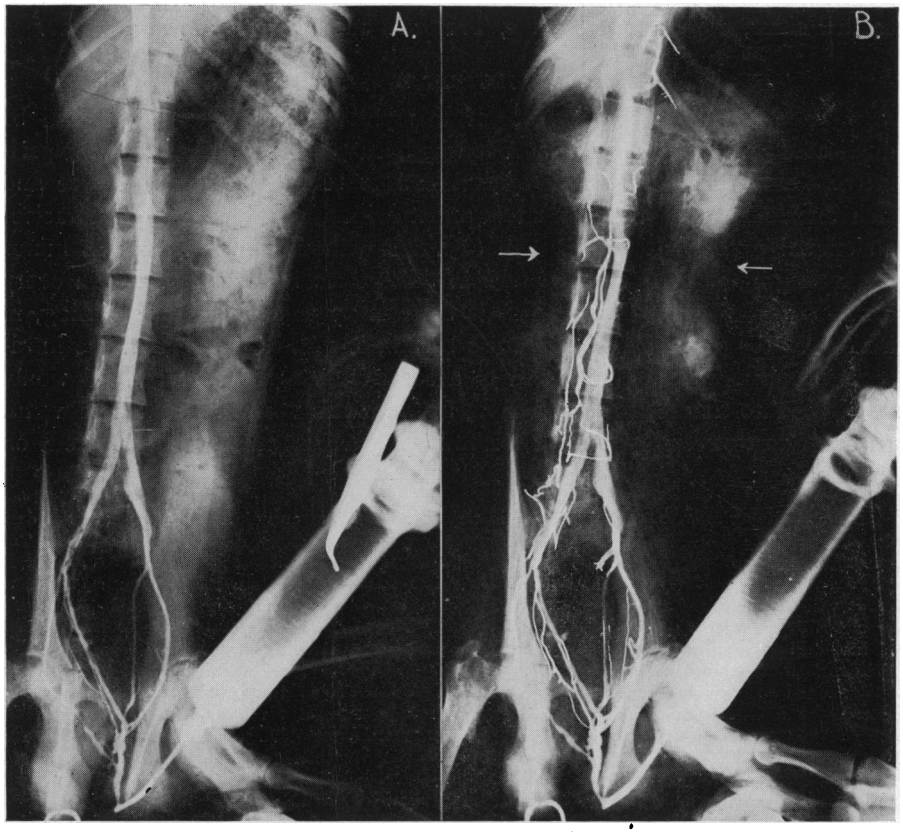

FIG. 4. A.—The roentgenogram of living monkey during injection of colloidal thorium dioxide into the deep dorsal vein of the penis. The injected material passed upward through the inferior vena cava. B.—The same animal as A during injection following abdominal compression with a towel. The material no longer follows the inferior vena cava but passes upward through the vertebral veins and is visualized in lower intercostal veins.

CADAVER INJECTION EXPERIMENTS IN OTHER REGIONS

Breast tumors also give rise to many "paradoxic" metastases. To see whether a venous pattern would reflect the grouping of aberrant metastases from breast carcinoma, an injection was made into a small vein in the left breast of an adult female cadaver. The cadaver was in the dorsal recumbent position and although two venules were cannulized, the injection was made in only one. A watery, thin mass composed of artist's water color vermilion (mercury sulphide) was injected. With the injection of 30 cc., the material was found in the clavicles, in the intercostal veins, in the head of the humerus, in the cervical vertebrae, in the transverse cranial venous sinus, and even in

the superior longitudinal sinus (Figs. 5A and 5). Some of the material was also to be found in the azygous vein and in the superior caval system. These injections parallel the spread of many of the so-called aberrant metastases from the breast, for example those to the paranasal sinuses, to the skull bones, to the cervical vertebrae and to the shoulder girdle, *etc.* This injection has been repeatedly duplicated.

In a recent breast injection in a senile female, a small cannula was introduced into a vein just lateral to the areola mammae. The first 15 cc. of the injected material spread entirely into the adjacent subcutaneous tissue. The skin surrounding the site of injection flushed and this flush gradually extended past the midline. Only after the injection of more than 15 cc. did the mass progress into the intercostal veins and to the vertebral system of veins, and into the shoulder girdle. In the roentgenographic stereoscope, the radiopaque mass is seen in the coracoid process of the left scapula and in the head of the right humerus. The spread of injected material in the subpapillary plexus of the skin indicates that Handley's lymphatic permeation theory, even as it concerns the skin, might be restudied with profit. Further injection studies of the venules of the breast always resulted in an erythematoid cutaneous blush; often this spreads past the midline into the other breast. The veins

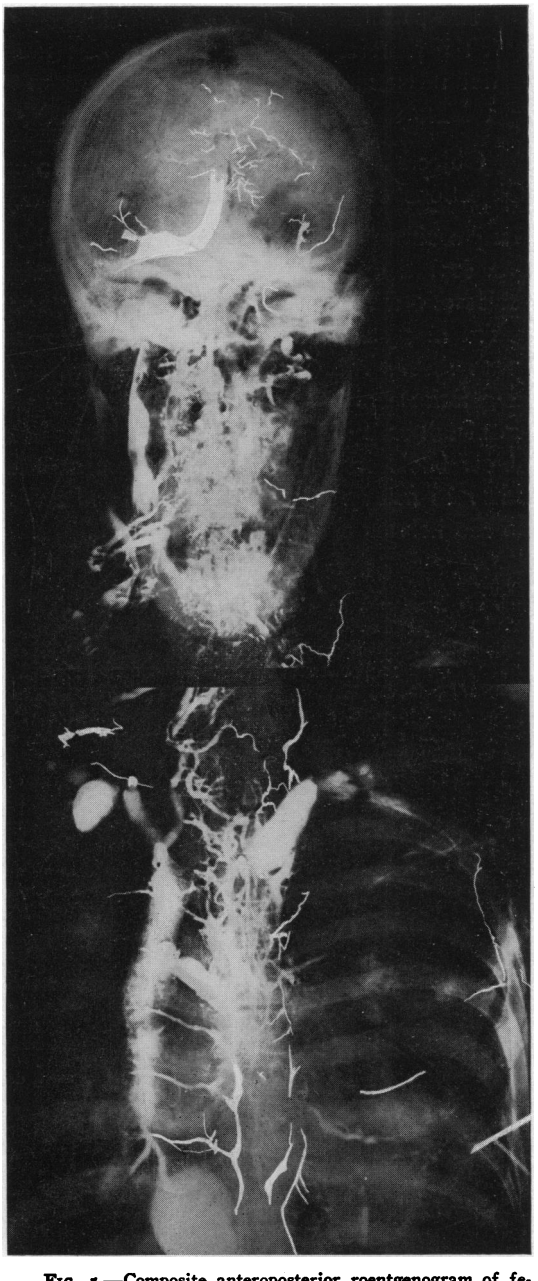

Fig. 5.—Composite anteroposterior roentgenogram of female cadaver after injection of radiopaque material into a venule of the left breast. Note the extensive filling of the vertebral veins, the superior longitudinal sinus, transverse sinus as well as in other dural and cerebral veins.

present a network rich enough to explain permeation should the microscopy of tumor cases indicate their invasion. Possibly both lymphatics and venules are concerned in tumor spread in the skin.

The parallelism between the architecture of the injected venous network and the pattern of distribution of metastases brings up the entire problem of the mechanism of tumor spread.

THEORIES OF TUMOR SPREAD

Objections are constantly occurring to current theories of tumor spread. Objections of Handley's[4] permeation theory are very completely stated by

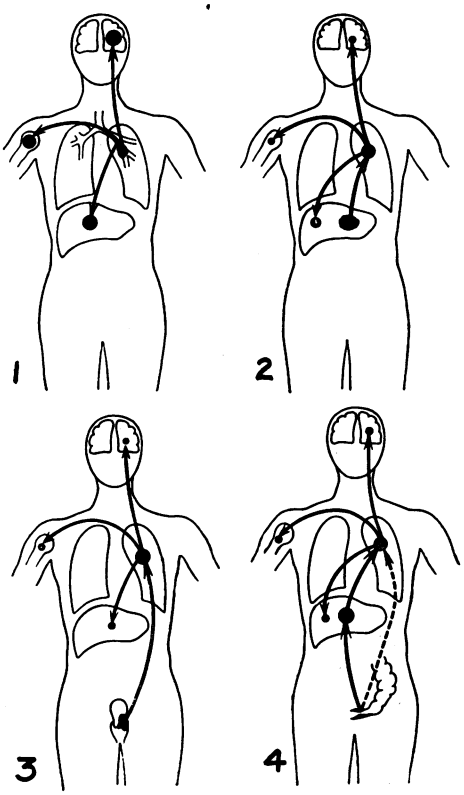

FIG. 6.—Walther's concept of tumor spread from various regions: 1) primary lung tumors, 2) primary liver tumors, 3) tumors from the area drained by the caval system, 4) tumors from the area drained by the portal system.

Willis.[5] A clear summary of the whole problem, together with his own concept of tumor spread, is made by Walther,[6] who holds that metastases are carried by lymphatic channels only so far as regional lymph nodes; from that point on he feels that tumors are spread by the blood-vascular system. His views are shown in four clear-cut figures (Fig. 6) to illustrate his four types. He cannot concede the possibility of a retrograde lymphatic spread (Handley), and while he admits in theory the possibility of a temporary reversal of the flow in a vein, he does not think that this has any practical significance. Walther did not envision the rôle of straining and coughing

in tumor spread stated above. It is to be noted in each of Walther's four types, namely, the lung, the liver, the portal and the caval, that he takes the metastatic material by way of the caval system through the heart, through the lungs, back through the heart and then to the peripheral parts of the body. This makes necessary his assumption of differential filters to explain the absence of lung lesions. It seems doubtful that an assumed predilection of carcinoma cells for tissues invaded routinely, explains the distribution pattern in such conditions as metastatic carcinoma of the prostate.

The transporting of tumor cell masses in veins is established by numerous reports (see Willis,[5] p. 18). The rôle of veins in the spreading of pyogenic processes needs no comment.

According to the concept here developed we have a vast intercommunicating system of veins which on the ground of anatomic injections, animal experiments, and simple logic, is constantly and physiologically the site of frequent reversals of flow. During these reversals a pathway up and down the spine exists which does not involve the heart or the lungs. The pathway has many connections. It provides a ready vehicle for the explanation of "aberrant" metastatic patterns and removes the stumbling block of the absence of lung involvement. The course through an open foramen ovale, while still a possible path, is no longer necessary to explain this lung "paradox."

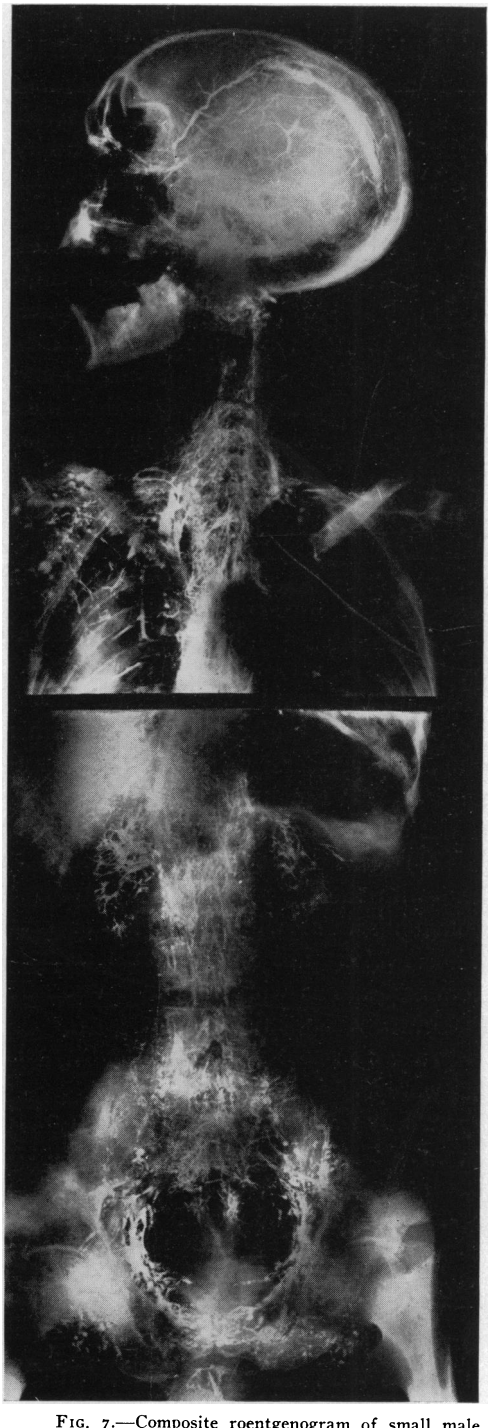

FIG. 7.—Composite roentgenogram of small male cadaver. Injection of radiopaque material into deep dorsal vein of penis. Note extensive cranial vein injection.

THE VERTEBRAL VEINS AND CONNECTIONS

I have referred to these veins about the vertebral column with their connections as the vertebral veins. Sometimes they are designated as the meningorachidian veins. The strictly vertebral portion of the network is composed of thin-walled vessels; when empty of blood they are difficult to identify yet they have considerable volume. Gilbert Breschet[7] was the first to fully appreciate the complexity and interrelationship of these veins of the skull and vertebral column. In the head and neck in man the veins ordinarily have no valves except at the point of emptying of the internal jugular veins. Throughout the cranium the veins of the brain, the veins of the meninges (the venous sinuses), and the veins of the skull bones themselves (the diploic veins), and the veins of the various extracranial plexuses anastomose richly. The usual methods of study fail to indicate their extent and size. Study of these vessels in the cadaver, in the experimental animal, and at the operating table show that they are storage lakes* as well as pathways of drainage. Stagnation is frequent. Their thin walls indicate that their contents are under low pressure.

The longitudinal vertebral veins duplicate their size and pattern from segment to segment; they have connections with the veins of the body cavities at each intervertebral space. The head, except for the two internal jugular veins, has a very similar arrangement. Even with the jugular veins, the posterior condyloid veins and the mastoid emissary veins and others act as by-passes, and are part of a plexiform network.

These vertebral veins have many and rich communications with the veins in the spinal canal, the veins around the spinal column, and those within the bones of the column. This system communicates with the segmental (intercostal) veins of the thoracico-abdominal wall (including those of the breast) and with the azygous system of veins. Through the latter there are free communications with the posterior bronchial vein and the parietal pleural veins. There are an occasional communication with a renal vein and rich communications with the pelvic viscera. Many of these communications are seen in a recent injection.

In a five-foot four-inch senile, male cadaver, weighing but 65 pounds, we were able to readily introduce 200 cc. of medium into the meningorachidian system by means of the dorsal vein of the penis. A study of the roentgenograms of this cadaver shows that there has been some spill-over into the caval system. Apparently, this occurred through one of the lumbar veins, and the material ran from there in a retrograde fashion into the renal and to a lesser degree into an hepatic vein. Even discounting for this spill into caval connections the amount of material injected, in the absence of back

* Barcroft, according to Franklin,[8] feels that an organ can be regarded as a blood depot only if it is clear "that the blood is not in the organ because it is being used there." Willis, however, fails to include this vertebral plexus in his list of blood depots. This seems to be an oversight, for the vertebral veins contain blood obviously not in use in the region.

pressure to cause distention, represents a considerable amount of fluid when rated against the total amount of blood in a small individual.

The testes and ovaries do not ordinarily have direct connections. These veins of the spine connect with the venae vasorum of the large vessels of the extremities and with the veins of the two bony girdles and the veins of upper ends of the femora and humeri. For the most part, all of the vessels mentioned are without effective valves. The valves of the pelvic veins are variable. The veins accompanying the spinal nerves are commonly described as having valves but, as seen by the injection (Fig. 7), these valves are no barrier to the suffusion of the entire system. Developmentally, while this system came from many components it has retained its essential primitive character—rich anastomoses, absence of valves, plexiform channels and many reduplications.

THE VERTEBRAL VEINS AS A VEIN SYSTEM

It is proposed that in addition to the recognized systems of veins, the pulmonary, the caval and the portal, because of its anatomic structure, its physiologic and its pathologic importance, we add, as a fourth, the vertebral system of veins (Fig. 8). According to this concept, in every act of straining, coughing, or lifting with the upper extremity, the blood is not only prevented from entering the thoracico-abdominal cavity, it is actually squeezed out of the cavity. Tumors and abscesses of the thoracico-abdominal wall, including the breast, tumors of the lung, pelvic tumors and abscesses, lesions of the shoulder and pelvic girdles, and occasionally tumors and abscesses of other organs have connections with this vein system and may therefore, have metastases distributed anywhere along the system without involving the portal, the pulmonary or the caval system.

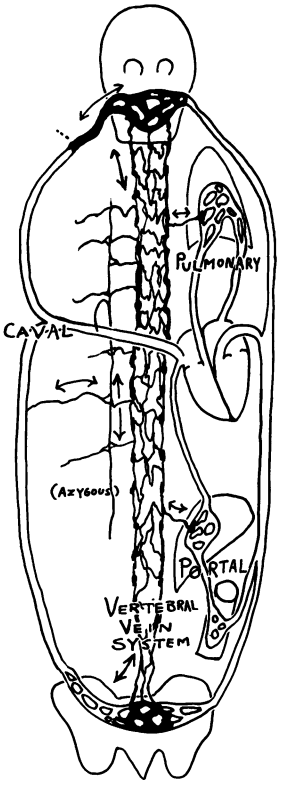

FIG. 8.—Diagram indicating the possibility of spread of tumors and abscesses from and to various regions of the body through the vertebral vein system which by-passes the caval, the portal and the pulmonary vein systems.

IMPLICATION AND EXTENSION OF CONCEPT

Almost every medical journal, medical meeting and hospital corridor provides case reports which are understandable by the mechanism here reported but which otherwise are obscure. Recent reports (Weyrauch,[9] and Walsh and Goldberg[10]) of disaster following diagnostic injections of perirenal air, and of blindness after pneumothorax are, unquestionably, to be explained by the intro-

duction of air emboli into the vertebral venous system. This venous air embolism problem is now being studied in experimental animals and will be reported shortly (Batson, Webster, MacDonald and Lewy).

Other applications to some of the problems raised by spinal cord tumors and by ascending spinal infections will immediately occur to many.

Turner and Jaffe[11] have recently summarized a large series of cases in regard to metastases. They note the tendencies of the various histologic types, but even after this classification, much is unexplained if the vertebral veins are not utilized. Ormond[12] reports a case of cancer of the penis in which the spread probably occurred through the vertebral veins. These veins seem to explain why the neurosurgeon so frequently makes the diagnosis of bronchiogenic carcinoma with cranial metastases. The primary lesion provides the tumor cells and the stimulus for the cough which causes a flow from the bronchial veins, especially the posterior one, into the spinal veins rather than into the veins of the right heart. One would expect metastases to travel both upward and downward. Folsome[13] reports two cases of vaginal tumors, secondary to bronchiogenic carcinoma. The uterovaginal veins are commonly without valves and as noted earlier have rich communication with the vertebral veins.

Lung abscesses proverbially have secondary abscesses in the brain. The posterior bronchial vein and vertebral veins with the ever-present cough appear to present the plausible route of extension.

CONCLUSIONS

Many metastatic tumors and abscesses do not fit readily into accepted explanations for tumor spread. The absence of lung involvement has been a constant stumbling block to current theories. Even an open foramen ovale has been used to explain metastatic paradoxes.

The vertebral veins with their rich, valveless ramifications and connections offer a possible solution to the difficulty. Injections into this system by way of the deep dorsal vein of the penis gives a pattern duplicating typical prostatic carcinoma spread. Injection of breast venules seems to duplicate the pattern of aberrant breast cancer spread, *i.e.*, spread into the spine, the ribs, the shoulder girdle and the skull.

Injection experiments in living monkeys, with simulated abdominal straining, show that the venous flow from pelvic veins is into the vertebral vein system.

The vertebral vein complex with its cranial and body-wall connections acts as a separate vein system. It may be either a venous pool, or it may be a venous by-pass for the other vein systems.

It is possible to explain most cases of aberrant malignant metastases, aberrant pyogenic metastases and aberrant embolism following air injections by the demonstrated rôle of the vertebral vein system.

It is proposed that the veins of the brain, skull, neck, viscera, vertebral column (together with their valveless connections in the girdles) and the body-wall veins be considered a separate, although overlapping, system of

veins. We suggest, for brevity, that the term vertebral veins be used to indicate this system. According to this concept the venous systems consist of the caval, pulmonary, portal and vertebral divisions.

BIBLIOGRAPHY

[1] Warren, S., Harris, P. N., and Graves, R. C.: Osseous Metastasis of Carcinoma of the Prostate with Special Reference to Perineural Lymphatics. Arch. Path., **22**, 139–160, 1936.

[2] Batson, O. V.: Latex Emulsions in Human Vascular Preparations. Science, **90**, 518–520, December 1, 1939.

[3] Hamilton, W. F., Woodbury, R. A., and Hayser, H. T.: Physiologic Relationship between Intrathoracic, Intraspinal, and Arterial Pressures. J.A.M.A., **107**, 853–856, September 12, 1936.

[4] Handley, W. S.: Cancer of the Breast and Its Treatment. London, 1922.

[5] Willis, Rupert A.: The Spread of Tumors in the Human Body. London, J. & A. Churchill, p. 321, 1934.

[6] Walther, Hans E.: Untersuchungen über Krebsmetastasen. Ztschr. f. Krebrsforsch., **46**, 313–333, 1937.

[7] Breschet, Gilbert: Recherches anatomiques, physiologiques et pathologiques sur le système vieneux. Paris, 1832.

[8] Franklin, Kenneth J.: A Monograph on Veins. Springfield, Charles C. Thomas, p. 77, 1937.

[9] Weyrauch, H. M., Jr.: Death from Air Embolism Following Perirenal Insufflation. J.A.M.A., **114**, 652–653, February 24, 1940.

[10] Walsh, F. B., and Goldberg, H. Krieger: Blindness Due to Air Embolism: A complication of Extrapleural Pneumolysis. J.A.M.A., **114**, 654, February 24, 1940.

[11] Turner, John W., and Jaffe, Henry L.: Metastatic Neoplasms. Amer. Jour. Roentgenol., **43**, 479–492, April, 1940.

[12] Ormond, John K.: Fulminating Cancer of the Penis. J.A.M.A., **114**, 1546, April 20, 1940.

[13] Folsome, Clair E.: Benign and Malignant Tumors of the Vulva. J.A.M.A., **114**, 1499–1503, April 20, 1940.