Am. J. Hum. Genet. 65:752–756, 1999

A Second Gene for Autosomal Dominant Möbius Syndrome Is Localized to Chromosome 10q, in a Dutch Family

H. T. F. M. Verzijl,[1] B. van den Helm,[1] B. Veldman,[1] B. C. J. Hamel,[2] L. P. Kuyt,[3] G. W. Padberg,[1] and H. Kremer[1,2]

Departments of [1]Neurology and [2]Human Genetics, University Hospital Nijmegen, Nijmegen; and [3]Department of Human Genetics, Free University, Amsterdam

Summary

Möbius syndrome (MIM 157900) consists of a congenital paresis or paralysis of the VIIth (facial) cranial nerve, frequently accompanied by dysfunction of other cranial nerves. The abducens nerve is typically affected, and often, also, the hypoglossal nerve. In addition, orofacial and limb malformations, defects of the musculoskeletal system, and mental retardation are seen in patients with Möbius syndrome. Most cases are sporadic, but familial recurrence can occur. Different modes of inheritance are suggested by different pedigrees. Genetic heterogeneity of Möbius syndrome has been suggested by cytogenetic studies and linkage analysis. Previously, we identified a locus on chromosome 3q21-22, in a large Dutch family with Möbius syndrome consisting essentially of autosomal dominant asymmetric bilateral facial paresis. Here we report linkage analysis in a second large Dutch family with autosomal dominant inherited facial paresis. After exclusion of >90% of the genome, we identified the locus on the long arm of chromosome 10 in this family, demonstrating genetic heterogeneity of this condition. The reduced penetrance suggests that at least some of the sporadic cases might be familial.

Introduction

Möbius syndrome (MBS; MIM 157900) is a rare congenital disorder involving complete or partial facial nerve palsy, either unilateral or bilateral, with or without paralysis of other cranial nerves. In particular, the abducens nerve is typically affected and often, also, the hypoglossal nerve. Malformations of the limbs occur frequently and include syndactyly, ectrodactyly, brachydactyly, and talipes equinovarus. Facial dysmorphisms, such as micrognathia, prominent epicanthic folds, and a broad flat nose, may also occur. Furthermore, structural abnormalities of the ear, defective branchial musculature (especially absence of the pectoral muscle), and mild mental retardation can accompany the cranial nerve palsy (Sudarshan and Goldie 1985; Kumar 1990). Only a minority of cases of congenital facial paralysis are uncomplicated by other cranial nerve palsies; in this group, deformities of the limbs are rare (Henderson 1939).

The etiology and the pathogenesis of the syndrome are uncertain. It is probable that the site, nature, and extent of the lesion are somewhat different in various cases (Hicks 1943; Towfighi et al. 1979). The two major explanations suggested for this type of cranial nerve dysfunction are (1) a primary metameric defect in the brain stem nuclei in the region of the tegmentum and (2) an ischemic process resulting from an interruption of the vascular supply of the brain stem during early fetal development. These rather divergent proposed mechanisms are based on limited pathological observations in patients with MBS. Agenesis or hypoplasia of the central brain stem nuclei and brain stem atrophy as a cause of peripheral nerve involvement or myopathy are observed. Hypoplasia of cranial nerve nuclei with active neuronal degeneration or with focal necrosis, gliosis, and calcification has been described as well (Kumar 1990).

The majority of the published reports on MBS refer to sporadic cases without any evidence of a known environmental causative factor, but familial occurrence has been described as well. The patterns of inheritance in families with the syndrome suggest different modes of inheritance: autosomal dominant, autosomal recessive, and X-linked recessive. Variable expression and decreased penetrance could explain the lack of clear Mendelian inheritance patterns in individuals in these families (Legum et al. 1981; Wishnick et al. 1981). Several genetic loci have been implicated in MBS. On the basis of the 46,XX,del(13)(q12.2) karyotype in a sporadic pa-

Received January 25, 1999; accepted for publication June 28, 1999; electronically published July 23, 1999.

Address for correspondence and reprints: Dr. H. Kremer, Department of Human Genetics, University Hospital Nijmegen, P. O. Box 9101, 6500 HB Nijmegen, The Netherlands. E-mail: H.Kremer@antrg.azn.nl

© 1999 by The American Society of Human Genetics. All rights reserved.
0002-9297/1999/6503-0021$02.00

tient (Slee et al. 1991) and of the cosegregation of the translocation t(1;13)(p34;q13) with the syndrome in a three-generation family (Ziter et al. 1977), 13q12.2-q13 is thought to harbor a locus for MBS. In two sporadic patients, the karyotypes 46,XY,t(1;11)(p22;p13) (Donahue et al. 1993) and 46,XY,t(1;2)(p22;q21.1) (Nishikawa et al. 1997) raise the possibility that another gene for MBS is located in or near band p22 on chromosome 1. Previously, we localized a gene for autosomal dominant congenital facial paralysis in a Dutch family to chromosome 3q21-22 (Kremer et al. 1996).

In the present study, we performed linkage analysis in a second Dutch family partly described elsewhere (Fortanier and Speijer 1935; Nicolai et al. 1986). The phenotype in this family is characterized by unilateral or asymmetric bilateral congenital facial paralysis; in some cases, deafness occurs. After exclusion of >90% of the genome, including the candidate regions, we localized the gene involved in MBS in this family to the long arm of chromosome 10.

Patients and Methods

Patients

We examined MBS patients in the family, one branch of which was described by Fortanier and Speijer (Fortanier and Speijer 1935) and two members of which were described by Nicolai et al. (1986). Affected members of this family have unilateral or bilateral facial weakness. Weakness of the muscles of the three branches of the facial nerve varies among individuals. Besides facial weakness, hearing loss is present in a number of patients, ranging from congenital deafness to progressive hearing loss with age. In one patient with hearing loss, there is a deformity of the os petrosum. Unaffected members of this family lack congenital hearing loss as well as facial paralysis, examined with specific functional facial tests on neurologic examination.

Typing of DNA Markers

Genomic DNA used for the typing of the DNA polymorphisms was isolated as described by Miller et al. (1988). Amplification of the polymorphic regions and analysis of the amplified fragments were performed according to Kremer et al. (1994).

Statistical Evaluation

We calculated two-point LOD scores, using the subroutine MLINK of the LINKAGE program (version 5.1) (Lathrop and Lalouel 1984; Lathrop et al. 1984, 1986). Multipoint analysis was performed by means of five-point linkage analysis (FASTLINK version 2.30) (Cottingham et al. 1993; Schaffer et al. 1994) combined with the sliding window technique. A mutated MBS allele frequency of .00001 and a penetrance of 80% were assumed. The penetrance was deduced from the number of clinically affected persons (21) and the number of obligate gene carriers (6). The order of the markers is according to the Généthon map and the chromosome 10 contig by Genome Therapeutics Corporation.

Results

Linkage to Chromosome 10q21.3-22.1

We performed linkage analysis in this second Dutch family with autosomal dominant MBS (Fortanier and Speijer 1935; Nicolai et al. 1986). Fifty-six persons were included in the DNA analysis, 19 of whom were affected and 5 of whom were obligate carriers.

We excluded the MBS locus on 3q and the regions involved in chromosomal abnormalities of MBS patients on chromosome 1, 2, 11, and 13. Subsequently, a random genome scan was initiated with polymorphic markers spaced 10–15 cM apart. After exclusion of>90% of the genome, an indication for linkage was obtained with marker D10S606 on the long arm of chromosome 10. The maximum LOD score was 2.02 at recombination fraction (θ) 0.06. Exclusion of the region distal to D10S606 pointed to a more proximal location of the disease gene.

Fine Mapping

For fine mapping of the gene, 15 polymorphic markers derived from the region proximal to D10S606 were tested (Genome Database, Généthon, Genome Therapeutics Corporation, GeneMap'99). Two-point LOD scores between the relevant markers and the disease lo-

Table 1

Two-Point LOD Scores between the Polymorphic Markers Derived from Chromosome 10 and MBS in the Present Family

	LOD Score at θ =							
Locus	.00	.05	.10	.20	.30	.40	θ_{max}	LOD_{max}
D10S196	−∞	−1.01	.01	.68	.70	.41	.25	.74
D10S539	−∞	.48	1.28	1.68	1.42	.78	.20	1.68
D10S589	−4.65	1.74	2.14	2.08	1.54	.78	.14	2.20
D10S581	.51	4.47	4.33	3.52	2.36	1.04	.05	4.47
D10S557	2.38	2.26	2.09	1.64	1.10	.53	.00	2.38
D10S1241	2.86	2.77	2.60	2.02	1.23	.40	.00	2.86
D10S599	1.76	1.61	1.45	1.10	.74	.37	.00	1.76
D10S502	−5.42	.71	1.19	1.32	.98	.44	.17	1.35
D10S1670	−.21	2.74	2.87	2.59	1.92	1.01	.10	2.87
D10S522	−1.72	1.37	1.50	1.36	.98	.48	.11	1.51
D10S1646	−8.57	−1.50	−.79	−.11	.18	.21	.36	.22
D10S210	−.21	2.59	2.61	2.19	1.52	.76	.08	2.63
D10S1647	−1.08	1.62	1.81	1.67	1.23	.65	.12	1.82
D10S1678	−3.42	−.76	−.49	−.19	.00	.08	.40	.08
D10S1672	−.34	2.62	2.79	2.54	1.90	1.01	.11	2.79

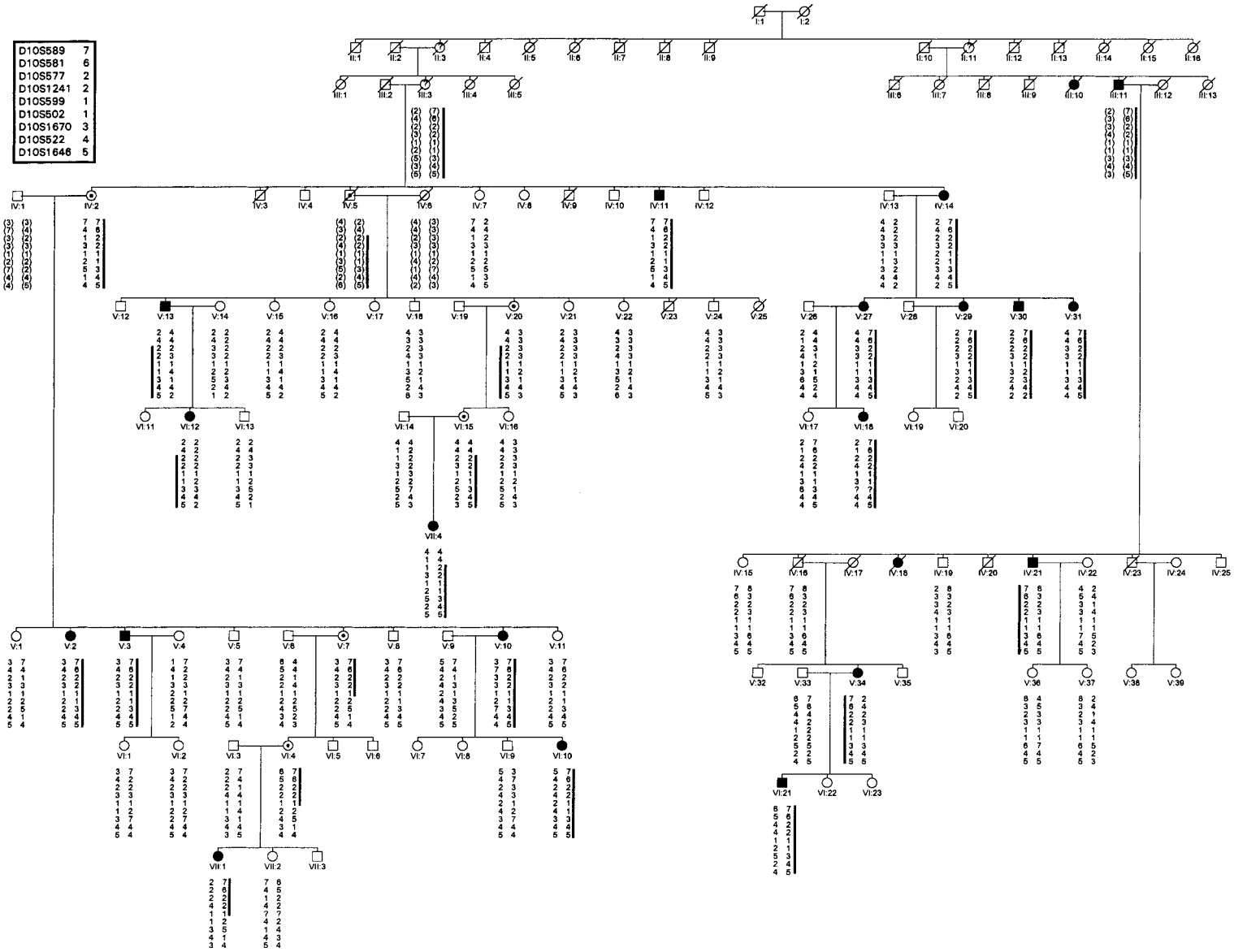

Figure 1 Pedigree of the family and haplotypes of individuals available for this study. The ancestral mutation-bearing chromosome is boxed. Lines beside the haplotypes mark the part of the ancestral chromosome present in the patients. Deduced haplotypes are given between brackets.

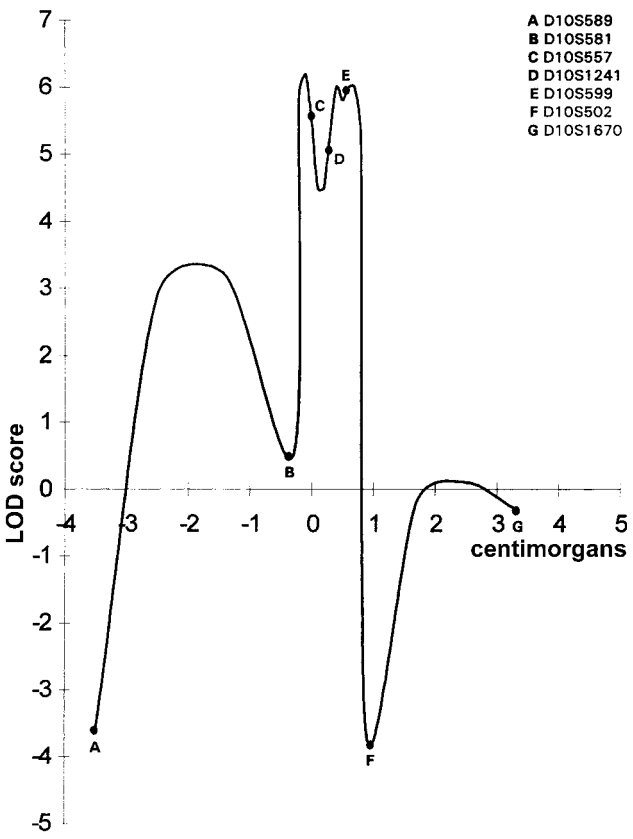

Figure 2 Five-point linkage analysis combined with the sliding window technique, resulting in a maximum LOD score of 6.2 in the interval between D10S581 and D10S557.

cus are given in table 1. A maximum LOD score of 4.47 at $\theta = 0.05$ was obtained with the marker D10S581.

Haplotypes were constructed to define the borders of the cosegregating region (fig. 1). The proximal border of the critical region is determined by a recombination, present in individuals V:13 and V:20, between the markers D10S581 and D10S557. The distal border of the region is determined by a recombination, present in individual V:7, between the markers D10S599 and D10S502. Besides the five obligate carriers, nine clinically unaffected individuals (IV:15, V:8, V:11, V:15, V:16, V:21, V:24, VI:13, and VI:17) underline the incomplete penetrance in this family because, for the relevant interval, they carry the chromosomal fragment that cosegregates with the syndrome. Therefore, after linkage had been established in this family, the penetrance was recalculated, leading to a value of 60%.

Five-point linkage analysis was performed to determine the location of the gene involved with the highest likelihood (fig. 2). The analysis resulted in the maximum LOD score of 6.2 in the interval flanked by the markers D10S581 and D10S557.

Discussion

In the present study, linkage analysis enabled us to localize a gene responsible for autosomal dominant inherited MBS to the long arm of chromosome 10. Herewith, we have demonstrated genetic heterogeneity for autosomal dominant MBS, since we previously described a locus for MBS on chromosome 3q21-22 (Kremer et al. 1996). The critical region that is delimited by the markers D10S581 and D10S502 spans ~3.7 cM at 10q21.3-22.1 (Généthon). The early growth response 2 gene (*EGR2*) maps to this interval (GeneMap'99) and is an interesting candidate gene, since disruption of the mouse orthologue, also known as *Krox-20*, results in elimination of rhombomeres 3 and 5 and thus affects the motor nuclei of cranial nerves V, VI, VII, and IX (Schneider-Mannoury et al. 1993).

The penetrance in the present family is 60%, given the five obligate carriers and nine clinically unaffected individuals in which haplotypes of the critical region show the "affected" genotype. In contrast, the penetrance in the first Dutch family with autosomal dominantly segregating MBS is 95% (Kremer et al. 1996). The reduced penetrance seen in the present family suggests that at least some of the seemingly sporadic cases might be members of a (small) family with a low penetrance of MBS. Furthermore, the reduced penetrance for MBS indicates that other factors, genetic or nongenetic, influence the development of the condition.

Pathogenetically, we assume that there are at least two different groups of patients with MBS. One group consists of patients with autosomal dominant congenital facial palsy, in which agenesis or hypoplasia of the cranial nerve nuclei is pathologically present. The palsy in this group is caused by genetic factors, and any occurring nonpenetrance might be explained by genetic as well as nongenetic factors. A second group of patients with congenital facial palsy is characterized by hypoplasia of cranial nerve nuclei, accompanied by necrosis, gliosis, and calcifications secondary to ischemia. The postulated ischemia of the brainstem in these cases might be explained as a primary (genetic) or a secondary (environmental) mechanism (Pastuszak et al. 1998). At present, it is unclear which part of MBS is caused by genetic and which part by nongenetic factors. Identification of the gene involved in the present family and subsequent mutation analysis in sporadic patients might shed some light on this question and on cranial nerve and brainstem development.

Acknowledgments

We are grateful to the family members who participated in this study. We would like to thank M. R. Nelen, Ing., and Dr.

M. M. M. van Reen for their support and helpful discussions, and Ir. K. Cuelenaere (CAOS/CAMM Center) for technical assistance. B.v.d.H. was supported by a grant from the Prinses Beatrix Fonds.

Electronic-Database Information

Accession numbers and URLs for data in this article are as follows:

GeneMap'99, http://www.ncbi.nlm.nih.gov/genemap99/
Généthon, http://ftp.genethon.fr/genethon_en.html
Genome Database, http://www.gdb.org/
Genome Therapeutics Corporation, http://web.genomecorp.com/genesequences/
Online Mendelian Inheritance in Man (OMIM), http://www.ncbi.nlm.nih.gov/Omim (for MBS, MIM 157900)

References

Cottingham R Jr, Idury R, Schaffer A (1993) Faster sequential genetic linkage computations. Am J Hum Genet 53:252–263

Donahue S, Wenger S, Steele M, Gorin M (1993) Broad-spectrum Möbius syndrome associated with a 1;11 chromosome translocation. Ophthalmic Paediatr Genet 14:17–21

Fortanier A, Speijer N (1935) Eine Erblichkeitsforschung bei einer Familie mit angeborenen Bewechlichkeitsstorung der Hinnerven (Infantiler Kernschwund von Moebius). Genetica 17:471–486

Henderson J (1939) The congenital facial diplegia syndrome: clinical features, pathology and aetiology. Brain 62:381–403

Hicks A (1943) Congenital paralysis of lateral rotators of eyes with paralysis of muscles of face. Arch Ophthalmol 30: 38–42

Kremer H, Kuyt LP, van den Helm B, van Reen M, Leunissen JAM, Hamel BC, Jansen C, et al (1996) Localization of a gene for Möbius syndrome to chromosome 3q by linkage analysis in a Dutch family. Hum Mol Genet 5:1367–1371

Kremer H, Pinckers A, van den Helm B, Deutman A, Ropers H, Mariman E (1994) Localization of the gene for dominant cystoid macular dystrophy on chromosome 7p. Hum Mol Genet 3:299–302

Kumar D (1990) Moebius syndrome. J Med Genet 27:122–126

Lathrop G, Lalouel J (1984) Easy calculations of lod scores and genetic risks on small computers. Am J Hum Genet 36: 460–465

Lathrop G, Lalouel J, Julier C, Ott J (1984) Strategies for multilocus linkage analysis in humans. Proc Natl Acad Sci USA 81:3443–3446

Lathrop G, Lalouel J, White R (1986) Construction of human linkage maps: likelihood calculations for multilocus linkage analysis. Genet Epidemiol 3:39–52

Legum C, Godel V, Nemet P (1981) Heterogeneity and pleiotropism in the Moebius syndrome. Clin Genet 20:254–259

Miller S, Dykes D, Polesky H (1988) A simple salting out procedure for extracting DNA from human nucleated cells. Nucleic Acids Res 16:1215

Nicolai J, Bos M, ter Haar B (1986) Hereditary congenital facial paralysis. Scand J Plast Reconstr Surg 20:37–39

Nishikawa M, Ichiyama T, Hayashi T, Furukawa S (1997) Mobius-like syndrome associated with a 1;2 chromosome translocation. Clin Genet 51:122–123

Pastuszak A, Schüler L, Speck-Martins C, Coelho K, Cordello S, Vargas F, Brunoni D, et al (1998) Use of Misoprostol during pregnancy and Möbius syndrome in infants. N Engl J Med 338:1881–1885

Schaffer A, Gupta S, Shriram K, Cottingham R Jr (1994) Avoiding recomputation in linkage analysis. Hum Hered 44: 225–237

Schneider-Manoury S, Topilko P, Seitanidou T, Levi G, Cohen-Tannoudji M, Pournin S, Babinet C, et al. (1993) Disruption of *Krox-20* results in alteration of rhombomeres 3 and 5 in the developing hindbrain. Cell 75:1199–1214

Slee J, Smart R, Viljoen D (1991) Deletion of chromosome 13 in Moebius syndrome. J Med Genet 28:413–414

Sudarshan A, Goldie W (1985) The spectrum of congenital facial diplegia (Moebius syndrome). Pediatr Neurol 1:180–184

Towfighi J, Marks K, Palmer E, Vannucci R (1979) Mobius syndrome: neuropathologic observations. Acta Neuropathol Berl 48:11–17

Wishnick M, Nelson L, Reich E, Hubbard L (1981) Moebius syndrome with dominant inheritance. Am J Hum Genet 33: 96A

Ziter F, Wiser W, Robinson A (1977) Three-generation pedigree of a Mobius syndrome variant with chromosome translocation. Arch Neurol 34:437–442