ioidomycosis, by altering the T-cell immunologic response, makes patients susceptible to sarcoidosis.[4,5] At the same time, the incidence of bacterial and invasive fungal infections in patients with sarcoidosis is no greater than in the general population.[6,7]

REFERENCES

1. Einstein HE. Bilateral hilar adenopathy [letter to the editor]. Ann Intern Med 1973 May; 78:787

2. Parker MS, Dokoh S, Woolfenden JM, Buchsbaum HW. Hypercalcemia in coccidioidomycosis. Am J Med 1984 Feb; 76:341–344

3. Lieberman J, Rea TH. Serum angiotensin-converting enzyme in leprosy and coccidioidomycosis. Ann Intern Med 1977; 87(4):423–425

4. Drutz DJ, Huppert M. Coccidioidomycosis: factors affecting the host-parasite interaction. J Infect Dis 1983 Mar; 147:372–390

5. Seltzer J, Broaddus VC, Jacobs R, Golden JA. Reactivation of coccidioides infection. West J Med 1986 Jul; 145:96–8

6. Winterbauer RH, Kraemer KG. The infectious complications of sarcoidosis: a current perspective. Arch Intern Med 1976 Dec; 136:1356–1362

7. Sicherman HJ, Andersen HA, DeRemee RA. Sarcoidosis or fungal disease? Chest 1973 Jul; 64:36–38

Diminutive Russian Prosthetic Heart Valve as an Iatrogenic Cause of Mitral Stenosis

ANDREW D. MICHAELS, MD
NORA GOLDSCHLAGER, MD
San Francisco, California

ALTHOUGH PROSTHETIC HEART VALVE replacement is currently performed with acceptably low mortality, complications and morbidity related to prosthetic valves remain a substantial problem. Since the 1950s, more than 50 models of mechanical prosthetic valves have been developed throughout the world. From this field, only four models of single-tilting and bileaflet-tilting disk valves are currently available for use in the United States.[1,2,3] The significant cost and complexity of completing Food and Drug Administration application procedures, concern over product liability, and patent rights on design and raw materials have likely served to narrow the choice of devices for physicians and possibly even hamper the pace of new model development in the United States. Worldwide, however, there remains a much broader selection of mechanical prosthetic valves with a wide range of hemodynamic profiles, thrombogenicity, and durability.[4] We report a case of symptomatic iatrogenic mitral stenosis arising from the use of an inappropriately small mechanical mitral valve prosthesis designed, manufactured, and surgically implanted in Russia. The patient's clinical findings of obstruction to blood flow across the mechanical valve with concomitant thromboembolism mimicked that of prosthesis thrombosis. This case emphasizes the importance of placing particular scrutiny on foreign-made mechanical cardiac valves in the evaluation of prosthesis complications.

(Michaels AD, Goldschlager N. Diminutive Russian prosthetic heart valve as an iatrogenic cause of mitral stenosis. West J Med 1997 May; 166:347–350)

From the Division of Cardiology, Department of Medicine, University of California, San Francisco (Dr Michaels), and the Division of Cardiology, San Francisco General Hospital (Dr Goldschlager).

Reprint requests to Nora Goldschlager, MD, Division of Cardiology, Moffitt Hospital, Room 1186, San Francisco, CA 94143.

Report of a Case

The patient is a 56-year-old Russian pharmacist with history of rheumatic heart disease, chronic atrial fibrillation, and prosthetic mitral valve replacement who was admitted to San Francisco General Hospital with a transient ischemic attack (TIA). She was diagnosed with rheumatic mitral stenosis 18 years ago and developed atrial fibrillation four years later. Recurrent deep venous thromboses required bilateral femoral vein thrombectomy four years prior to admission. One year later, she underwent prosthetic mitral valve replacement in Russia without complications. She had no history of myocardial infarction, endocarditis, hypertension, diabetes mellitus, tobacco or alcohol use, or hyperlipidemia, and no family history of coronary or valvular disease.

The patient emigrated to the United States eight months prior to admission. She was prescribed warfarin, digoxin, and pentoxifylline (Trental), but ran out of all medications six months prior to admission. One month prior to admission, she noted the onset of progressive fatigue and decreased exercise tolerance. She also described new two-pillow orthopnea and intermittent chest pressure with associated nausea and diaphoresis that was not related to exertion or position. On the day of admission, she experienced while sitting the sudden onset of decreased sensation in the right arm, leg, and tongue. She also developed transient expressive aphasia with complete inability to speak which resolved within 20 minutes. Comprehension remained intact.

On physical examination in the Emergency Department performed 50 minutes after the onset of symptoms, the patient was afebrile. Blood pressure was 142/67 mmHg, heart rate 77 per minute, and respiration rate 16 breaths per minute. Pulse oximeter saturation was 95% on room air. Fundoscopic examination was normal. The chest was clear to auscultation and percussion. Central venous pressure was 5 cm H_2O with normal *v* waves. The carotid upstroke was normal and without bruits. The cardiac apical impulse was not displaced or sustained; a moderate left parasternal lift was present. The rhythm was irregularly irregular with a mechanical S1, a physiologically split S2, and an opening sound (OS) with a short S2-OS interval. A II/VI holosystolic blowing murmur at the apex radiated to the axilla, and there was a I/VI early diastolic apical rumble, and a II/VI crescendo-decrescendo early-peaking nonradiating flow murmur at the base. The liver was nonpulsatile with a span of 8 cm. There was no peripheral edema, and all peripheral pulses were normal. The patient was alert and oriented with fluent speech and normal comprehension. Cranial nerves

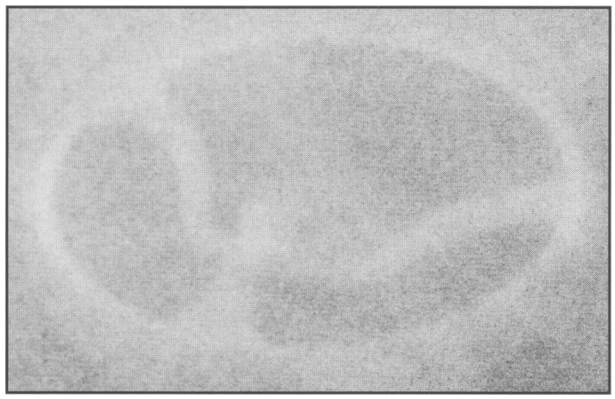

Figure 1.—The Russian-made EMIKS mechanical single-tilting mitral valve prosthesis is seen on lateral chest x-ray. The orifice ring and supporting struts are radio-opaque.

were normal. Mild right pronator drift as well as mild pyramidal weakness in the right arm and leg were noted. The right arm had mildly increased tone. Reflexes were 3+ and symmetric. Mild decreased pinprick sensation in the right arm and leg was elicited. Coordination and gait were normal, and there was no tremor or asterixis.

Complete blood count, electrolytes, blood urea nitrogen, creatinine, glucose, coagulation tests, thyroid function tests, and liver panel were normal. The electrocardiogram revealed atrial fibrillation with ventricular rate of 67 per minute. The mean frontal plane QRS axis and intervals were normal. Nonspecific ST segment depression was present in V3-6; Q waves were absent and left ventricular hypertrophy criteria were not met. Chest x-ray showed normal heart size and no pulmonary edema, infiltrates, or effusion. A mechanical single-tilting mitral valve prosthesis was noted (Figure 1).

The patient was admitted to the Neurology Service. A noncontrast head CT scan showed an old left lacunar stroke with no evidence of hemorrhage. She was treated with heparin for the TIA and all neurologic deficits resolved completely over the next 24 hours. A bilateral carotid Doppler ultrasound examination showed no hemodynamically significant stenosis in the common or internal carotid arteries. A transthoracic echocardiogram (TTE) showed moderate left atrial enlargement measuring 52 mm and no thrombus. The prosthetic mitral valve had an echocardiographic mean diastolic gradient of 20 mmHg. Moderate mitral regurgitation was present. Due to reflectance generated by the prosthesis, a vegetation or valvular thrombus could not be excluded. Ventricular size and function were normal, and aortic, tricuspid, and pulmonic valve morphology and function were normal.

Because of concern regarding the diastolic mitral valve gradient demonstrated on echocardiography, cardiac catheterization was performed. The pulmonary artery pressure was 41/15 mmHg. The pulmonary capillary wedge pressure was 14 mmHg with prominent *v* waves. The mean diastolic gradient across the mitral valve was 16 mmHg, and the calculated mitral valve area was 0.9 cm^2 (normal for single-tilting disk valve is 1.9–3.2 cm^2).[1] Coronary angiography was normal. Left ventriculography revealed normal systolic function and moderate mitral regurgitation.

Given the small calculated mitral valve area in a patient not taking anticoagulant medication for a mechanical prosthetic valve in the mitral position, the diagnosis of possible valve thrombosis was made. The patient was referred to the University of California San Francisco Medical Center for mitral valve replacement. Intraoperative transesophageal echocardiography revealed significant prosthetic paravalvular mitral regurgitation. The surgeons identified mild valve dehiscence, several loose silk sutures, and a significant paravalvular leak. Two discrete areas on the anterior annulus were separated from the annular ring. No valvular thrombosis, annular calcification, or pannus formation was noted, but the valve had a very small orifice measuring 1.1 cm^2 (Figure 2). The patient received a new 33-mm St. Jude Medical prosthetic valve with an area of 5.2 cm^2. Her postoperative course was uncomplicated, and she was discharged on warfarin on postoperative day five.

Discussion

Mechanical prosthetic valve thrombosis is a major complication of valve replacement. The reported incidence is 0.1 to 5.7 percent per patient-year.[5,6] Mitral position of the prosthesis[7] and suboptimal anticoagulation[8,9] are the two major predisposing factors to prosthetic valve thrombosis. Current recommendations for antithrombotic therapy for patients with mechanical prosthetic heart valves include warfarin treatment with an international normalized ratio of 4.0–4.9 for caged-ball, 3.0–3.9 for single-tilting disk, and 2.5–2.9 for bileaflet-tilting disk models.[1] Antiplatelet therapy with aspirin can be added in patients at high risk for embolism, such as those with atrial fibrillation, previous systemic embolization, documented intracardiac thrombus, or severe left ventricular dysfunction.[1] The clinical features of mitral and aortic valve thrombosis include pulmonary congestion and frank pulmonary edema, cardiogenic shock, and systemic embolism. Many embolic episodes are minor, resulting in events such as amaurosis fugax, tran-

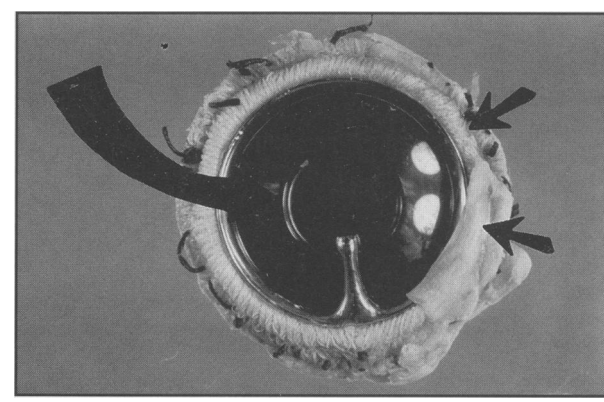

Figure 2.—Gross examination of the Russian valve prosthesis reveals an effective orifice area of 1.1 cm^2 measured from the tilting disc area (large arrow). Two areas on the anterior annulus (small arrows) are separated from the annular ring, resulting in paravalvular regurgitation.

sient neurologic ischemic attacks, or spontaneously resolving extremity ischemia. Major embolic episodes, however, include permanent neurologic deficits, extremity ischemia, and death.

Physical examination may demonstrate a new murmur of valvular regurgitation or stenosis. In addition, decreased intensity of the opening and/or closing metallic clicks may be appreciated, resulting from attenuated disk movement due to thrombus. In most patients with embolism, prosthetic valve thrombus is not seen on echocardiography because of the high reflectivity for ultrasound of the prosthesis itself. In addition, thrombi may form and then disappear.[10] Several studies have demonstrated the superiority of TEE compared to TTE in the documentation of prosthetic valve stenosis, regurgitation, endocarditis, and thrombosis.[11,12] In one study, the sensitivity for detecting morphologic prosthetic valve abnormalities was 83% for TEE compared with 22% for TTE ($P < 0.01$).[12]

In the case reported here, the patient was at high risk for prosthetic valve thrombosis given the combination of the low-flow mitral prosthesis position as well as the lack of anticoagulation. The patient's presenting prodrome of orthopnea and decreased exercise tolerance followed by the TIA was worrisome and suggested progressive valve obstruction. The physical examination findings of systolic and diastolic mitral murmurs in addition to the increased diastolic gradient across the mitral valve demonstrated by echocardiography and cardiac catheterization also increased the likelihood of prosthetic valve thrombosis. Finally, the calculated mitral valve area of less than one-half the expected valve area suggested the diagnosis of prosthetic valve thrombosis.

However, when the valve was visualized during surgery, no valvular thrombosis was identified. The mechanical valve did have significant paravalvular leak, likely due to insufficient anchoring from the unusual use of silk sutures. In general, silk loses strength over time and is unsuitable for insertion of prosthetic heart valves.[13,14] In addition, silk sutures are multifilament and provide a nidus for bacterial growth. Many US cardiac surgeons, including those at our medical center, prefer synthetic monofilament polypropylene for implanting valvular prostheses.[15]

The very small mitral valve area calculated in our patient was due to the small Russian-made prosthetic valve used, with a directly measured orifice area of 1.1 cm^2 on pathologic gross examination. The patient's TIA was likely due to either left atrial thrombosis resulting from chronic atrial fibrillation or transient prosthetic valve thrombosis that embolized or resolved on heparin therapy. The small mitral valve prosthesis was an unexpected finding; the effective orifice area for single-tilting disks (e.g., Björk-Shiley or Medtronic-Hall) for adults in the mitral position typically measure 1.9 to 3.2 cm^2.[1,16]

Chiefly because of cost constraints, Russia has manufactured and distributed its own prosthetic heart valves modeled after the Monostrut version of the Björk-Shiley single-tilting disk design.[17-20] The experience with this "EMIKS" disk prosthesis is largely limited to the Russian medical community, with no mention of this model in exhaustive reviews of the evolution of heart valve development.[3,16] Reports addressing the Russian experience with valve replacement indicate a hospital mortality of 3.3%, a prosthesis thrombosis rate of 0.05% per patient-year, and a 10-year complication rate of 13%.[21,22] These mortality and complication rates are comparable to our experience. However, researchers report that the EMIKS valves have mean gradients of 4.2 mmHg.[23] Hemodynamic studies have indicated that the effective opening area of these valves is 2.6 cm^2.[24] It is of great concern that the mitral valve in this case had a 16 mmHg diastolic gradient with an unusually small orifice of 1.1 cm^2, varying significantly from the published hemodynamic results.

This case emphasizes the importance of comprehensively evaluating prosthetic valve function in patients presenting with clinical features of valve failure, particularly when the model, size, and thrombogenicity of the particular prosthetic valve are not known. Because of the historically limited supply of prosthetic valves in Russia, cases of iatrogenic mitral stenosis from hemodynamically compromised Russian prosthetic valves may be encountered frequently in immigrants to the United States.

REFERENCES

1. Vongpatanasin W, Hills LD, Lange RA. Prosthetic heart valves. N Engl J Med 1996; 335:407–416

2. Jamieson WR. Modern cardiac valve devices—bioprostheses and mechanical prostheses: state of the art. J Cardiac Surgery 1993; 8:89–98

3. Karp RB, Sand ME. Mechanical prostheses: old and new. Cardiovasc Clinics 1993; 23:235–253

4. Rábago G. A worldwide overview of valve usage. *In* Rábago G, Cooley DA (Eds): Heart Valve Replacement and Future Trends in Cardiac Surgery. New York: Futura Publishing, 1987, pp 3–9

5. Metzdorff MT, Grunkemeier GL, Pinson CW, Starr A. Thrombosis of mechanical cardiac valves: a qualitative comparison of the Silastic ball valve and the tilting disc valve. J Am Coll Cardiol 1984; 4:50–53

6. Edmunds LH Jr. Thromboembolic complications of current valvular prostheses. Ann Thoracic Surg 1982; 34:96–106

7. Cannegieter SC, Rosendaal FR, Briet E. Thromboembolic and bleeding complications in patients with mechanical heart valve prostheses. Circulation 1994; 89:635–641

8. Ryder SJ, Bradley H, Brannan JJ, Turner MA, Bain WH. Thrombotic obstruction of the Björk-Shiley valve: the Glasgow experience. Thorax 1984; 39:487–492

9. Butchart EG. Thrombosis, embolism, and bleeding. *In* Bodnar E, Frater R (Eds): Replacement cardiac valves. New York: McGraw-Hill, 1992, pp 77–98

10. Hancock EW. Artificial valve disease. *In* Schlant RC, Alexander RW (Eds): The Heart: Arteries and Veins. Eighth edition. New York: McGraw-Hill, 1994, pp 1539–1545

11. Zabalgoitia M, Garcia M. Pitfalls in the echo-Doppler diagnosis of prosthetic valve disorders. Echocardiography 1993; 10:203–212

12. Daniel WG, Mugge A, Grote J, Hausmann D, Nikutta P, Laas J, et al. Comparison of transthoracic and transesophageal echocardiography for detection of abnormalities of prosthetic and bioprosthetic valves in the mitral and aortic positions. Am J Cardiol 1993; 71:210–215

13. Hunt TK, Goodson WH: Wound healing. *In* Way LW (Ed): Current Surgical Diagnosis and Treatment. San Mateo: Appleton & Lange, 1991, pp 95–108

14. Actis DGM, Bognolo G, Actis DA, Cattaneo C, Di Summa M. A rare complication of mitral valve replacement: sudden cardiac death for immobilization of disc valve by an unraveled suture. J Cardiovasc Surgery 1995; 36:167–169

15. Cooley DA. Simplified techniques of valve replacement. J Cardiac Surgery 1992; 7:357–362

16. Morse D, Steiner RM, Fernandez J (Eds) Guide to Prosthetic Cardiac Valves. New York: Springer-Verlag, 1985

17. Bain WH, Nashef SAM. Tilting disk valves. *In* Bodnar E, Frater RWM (Eds): Replacement Cardiac Valves. New York: Pergamon Press, 1991, p 197

18. Iskrenko AV, Tarichko IV, Konstantinov BA. Clinical use of the EMIKS and LIKS Russian disk rotation prostheses. Khirurgiia 1987; 6:18–22

19. Burakovski VI, Iofis NA, Shumakov VI, Semenovskii ML, Manukian VE. New disk-shaped "Emiks" valve for isolated mitral valve prosthesis. Grudnaia

Khirurgiia 1986; 1:10–14

20. Bukatov AS, Iofis NA, Kevorkova RA, Kostretsov AS. EMIKS artificial heart valves. Meditsinskaia Tekhnika 1987; 5:55–56

21. Tsukerman GI, Faminskii DO, Pomortseva LV. A trial of the use of EMIKS and LIKS disk prostheses over 10 years. Grudnaia I Serdechno-Sosudistaia Khirurgiia 1993; 6:8–11

22. Kevorkova RA, Iofis NA, Dzevishek EV, Agafonov AV, Kalugin VI, Kuznetsova EI, et al. Increasing the duration of the artificial heart valves "EMIKS." Meditsinskaia Tekhnika 1989; 6:9–15

23. Tsukerman GI, Dobrova NB, Faminskii DO, Pomoretseva LV, Gvakhariia IN, Chigogidze NA, et al. Clinical characteristics of the Soviet low-profile heart valve prostheses EMIKS and LIKS. Vestnik Akademii Meditsinskikh Nauk Sssr 1989; 10:68–75

24. Semenovskii ML, Manukian VE, Chestukhin VV. Hemodynamic characteristics of the EMIKS disk artificial heart valves. Meditsinskaia Tekhnika 1987; 5:13–16

Gastrointestinal Bleeding and Gastric Outlet Obstruction From Peutz-Jeghers Polyposis

Diagnosis and Treatment

DOUGLAS A. CORLEY, MD
TIMOTHY M. UYEKI, MD
JOHN P. CELLO, MD
San Francisco, California

PEUTZ-JEGHERS SYNDROME is an uncommon disorder, inherited in an autosomal dominant pattern, and characterized by mucocutaneous pigmentation and hamartomatous polyps.[1-4] Although these polyps have been described in many organs, including the nasopharynx, gallbladder, and urinary bladder, they are seen primarily in the gastrointestinal tract. In the gastrointestinal tract, the polyps may cause bleeding, obstruction, and intussusception. Only three cases of patients with gastric outlet obstruction from Peutz-Jeghers polyps have been described, all of which were treated surgically.[5-7]

We describe a case of Peutz-Jeghers polyposis in an adolescent with Bardet-Biedl syndrome presenting with symptoms of small bowel obstruction, hematochezia, and gastric outlet obstruction. He was successfully treated by a combined endoscopic and surgical approach. This is the first report of the successful endoscopic treatment of gastric outlet obstruction from Peutz-Jeghers polyposis.

The Bardet-Biedl syndrome is a genetic disorder inherited in an autosomal recessive pattern, usually characterized by having at least four of five cardinal signs. These signs are mental retardation, obesity, hypogenitalism, polydactyly, and pigmentary retinopathy. Some authors do not include mental retardation as one of the cardinal signs.[8] There is no known association of the Bardet-Biedl syndrome with intestinal polyposis.

(Corley DA, Uyeki TM, Cello JP. Gastrointestinal bleeding and gastric outlet obstruction from Peutz-Jeghers polyposis: diagnosis and treatment. West J Med 1997 May; 166:350–352)

From the Division of Gastroenterology, Department of Medicine (Drs Corley and Cello), and the Department of Pediatrics (Dr Uyeki), San Francisco General Hospital Medical Center, University of California, San Francisco, School of Medicine.

Reprint requests to Douglas A. Corley, MD, GI Unit, 3-D, San Francisco General Hospital Medical Center, San Francisco, CA 94110.

Report of a Case

The patient, a 15-year-old male adolescent, was previously diagnosed with the Bardet-Biedl syndrome. For three months, he had weekly abdominal pain characterized by severe periumbilical and left upper quadrant cramping that lasted 30 to 90 minutes, then spontaneously resolved. Separate from these episodes, he had weekly postprandial vomiting—30 to 90 minutes after meals—of partially digested, nonbilious material. During this time he also noted three episodes of hematochezia that filled the toilet bowl with blood. His bowel movements between these episodes were normal.

His father had moderate perioral and acral melanosis and required a blood transfusion due to hematochezia when he was in his 20s; an operation in China at that time removed a probable intestinal polyp. The patient's brother also had the Bardet-Biedl syndrome, diagnosed by the presence of developmental delay, retinitis pigmentosa, moderate obesity (>95th percentile for age), and polydactyly; he did not have any gastrointestinal symptoms. Neither parent possessed characteristics of the Bardet-Biedl syndrome, although the father has distant relatives in China with learning disabilities and visual problems.

On examination the patient appeared healthy but overweight (>95th percentile), and he had a blunted affect. He had mild perioral, buccal, pharyngeal, acral, and genital melanosis. His hands showed surgically corrected polydactyly, and his feet had uncorrected postaxial polydactyly. His genitalia had previously been noted to be normal for his age. His fundi were poorly visualized, and a previous optometric examination revealed astigmatism.

On colonoscopy to the cecum, several large polyps greater than 2 cm were noted; these were removed during two procedures, with initial resolution of his hematochezia.

Figure 1.—Endoscopy shows gastric outlet obstruction from a prepyloric polyp.