Subtotal Versus *Total Parathyroidectomy with Forearm Autograft for Secondary Hyperparathyroidism in Chronic Renal Failure*

HIROSHI TAKAGI, M.D., M.S.D.,* YOSHIHIRO TOMINAGA, M.D.,† KAZUHARU UCHIDA, M.D.,† NOBUO YAMADA, M.D.,† MACHIO KAWAI, M.D.,† TADAYUKI KANO, M.D.,† TAKESHI MORIMOTO, M.D.*

Forty-three patients with chronic renal failure and secondary hyperparathyroidism underwent parathyroidectomy; 20 of the 43 underwent subtotal parathyroidectomy (Group A) and 23 patients underwent total parathyroidectomy and parathyroid autotransplant in the forearm (Group B). Postoperative clinical improvement was similar in both groups. In the immediate postoperative period eight patients in Group A who had severe bone changes and 21 patients in Group B needed supplemental calcium administration. The grafted tissues in all cases functioned well; reimplantation of the cryopreserved parathyroid tissues was unnecessary. One case in each group showed a recurrence. One patient in Group A was submitted to reexploration of the neck with a lateral approach. The other patient in Group B underwent excisions of the transplanted parathyroid tissues on three separate occasions under local anesthesia. The second operation was definitely easier and safer to manage after a total parathyroidectomy with autotransplantation to the forearm.

From the Department of Surgery, Aichi Cancer Center Hospital, and the Organ Transplant Center, Nagoya Second Red Cross Hospital,† Nagoya, Japan*

THE NUMBER OF PATIENTS on long-term hemodialysis due to chronic renal failure is steadily increasing. In spite of improved management with introduction of an active form of vitamin D, many patients with renal osteodystrophy due to secondary hyperparathyroidism resistant to conservative treatment are referred to us for surgical parathyroidectomy.[1,2]

Hitherto the common surgical procedure in patients with secondary hyperparathyroidism has been a subtotal parathyroidectomy with the aim of preserving sufficient viable tissue *in situ* to maintain normal calcium homeostasis. Since the stimulus of parathyroid hyperfunction remains, however, hyperparathyroidism may recur and require a secondary operation in a certain number of cases.[3] In 1975, Wells et al.[4] described the technique of total parathyroidectomy with autotransplantation of parathyroid tissue to the forearm and its application in patients with secondary hyperparathyroidism. The rationale for this procedure is that a second neck exploration, with all its attendant risks, can be avoided, and that excessive parathyroid tissue can easily be removed from the forearm under local anesthesia if secondary hyperparathyroidism recurs.

This paper compares the clinical outcome of subtotal parathyroidectomy to that of total parathyroidectomy with autotransplantation to the forearm musculature.

Clinical Materials

For preoperative diagnosis of secondary hyperparathyroidism, the serum calcium, phosphorus, alkaline phosphatase, and parathyroid hormone (PTH) levels were obtained together with bone x-rays. Computed tomography (CT), scintigraphy with $^{201}TlCl$ and $^{99m}TcO_4^-$ and ultrasonography were undertaken; a follow-up study was conducted from July of 1973 to October 1983.[1,2] Forty-three patients diagnosed as chronic renal failure and secondary hyperparathyroidism underwent parathyroid surgery.

Twenty of 43 patients (*i.e.*, the first 19 patients and one with only three parathyroid glands) were submitted to subtotal parathyroidectomy (Group A) from July of 1973 to July of 1981. The remaining 23 patients underwent total parathyroidectomy and parathyroid autograft in the forearm (Group B) between March of 1981 and October of 1983.

The age and sex distribution in the two groups of patients at the time of parathyroidectomy in relation to hemodialysis treatment are shown in Table 1. The preoperative laboratory and clinical findings are presented in Table 2.

Supported by grant "Organ Transplantation" from Aichi Cancer Center Hospital and Grant No. 55KO-1 from National Cardiovascular Center.

Reprint requests: Hiroshi Takagi, M.D., M.S.D., Transplant Unit, Department of Surgery, Aichi Cancer Center Hospital, Chikusa-ku, Nagoya, Japan.

Submitted for publication: December 12, 1983.

As a preoperative treatment all patients were dialysed the day before operation. The next dialysis was performed on the second day after operation.

Technique of Parathyroidectomy

Subtotal Parathyroidectomy

The thyroid and parathyroid glands were exposed through a conventional neck incision, with division of the strap muscles at the midline. A thorough search was made for the parathyroids with the assistance of preoperative image diagnosis, and after identification of all glands subtotal parathyroidectomy was performed. Between one-third and one-fourth of a well vascularized gland was left *in situ.* All glands were histologically verified.[5]

Total Parathyroidectomy with Autotransplantation to the Forearm

The neck dissection was the same as in subtotal parathyroidectomy. All excised glands were histologically verified. Approximately fifteen 1 × 1 × 3 mm parathyroid slivers were implanted into the forearm muscle in the area about 5 × 5 cm. Some of the parathyroid tissue removed from the neck was preserved as described by Wells for future reimplantation in the event of a permanent and complete hypoparathyroid state.[4]

Postoperative Management

After surgery serum calcium levels were monitored three times a day during the first 2 to 4 days and then daily until stable. As soon as the serum calcium concentration dropped close to 7 mg/100 ml, constant infusion of calcium gluconate was administered intravenously to maintain serum calcium at more than 8 mg/100 ml. Intravenous calcium was gradually reduced with the addition of oral calcium lactate combined with dihydrotachysterol 0.5 to 1.0 ng/day until serum calcium was maintained between 8 and 10 mg/100 ml. As of 1978 all patients received 1α,OH cholecalciferol instead of dihydrotachysterol.[6]

TABLE 1. *Age and Sex Distribution at the Time of Parathyroidectomy in Relation to Hemodialysis Treatment*

	Group A (N = 20)	Group B (N = 23)
Men	14	18
Women	6	5
Mean age (years)	33.8 (Range 22–53)	45.2 (Range 31–57)
Mean duration of hemodialysis treatment (months)	61.0 (Range 5–104)	100.3 (Range 32–146)

TABLE 2. *Preoperative Laboratory and Clinical Findings*

	Group A (N = 20)	Group B (N = 23)
Elevated serum calcium (> 11 mg/dl)	5	5
Elevated level of parathyroid hormone	18	22
Elevated alkaline phosphatase	19	18
Bone changes	16	22
Soft tissue calcification	10	13
Pathologic fracture	9	8
Pruritus	9	9
Bone and joint pain	11	19
Mental disturbance	2	11
Muscular weakness	2	11
Image diagnosis applied	11	23

Results

Total Weight of Excised Parathyroid Glands

Figure 1 shows the total weight of excised parathyroid glands in both A and B groups of patients. Group A included five patients in whom the total weights of excised parathyroid gland were less than 500 mg because they underwent surgery before the introduction of image diagnosis of parathyroid glands.

Fourteen lower glands in 12 patients of both groups were excised by thymic resection.

Postoperative Course

In most patients there was a rapid decrease in serum calcium and PTH during the first postoperative days. Hypocalcemia was generally evident between the first and the fifth day after surgery, and hypocalcemia tended to be evident earlier in group B (Table 3). Eight of 20 patients in Group A needed intravenous calcium administration in the immediate postoperative period, whereas all but two patients in Group B required intravenous calcium administration in the same period.

Eight patients in Group A who required supplement calcium administration had severe bone changes. One of the two exceptional patients in Group B whose four excised parathyroid glands weighed 6110 mg and did not require intravenous calcium administration before iniciation of graft function may have the fifth parathyroid gland somewhere in the mediastinum; clinical symptoms such as pruritus, bone pain, and soft tissue calcification have been gradually relieved. In another patient in Group B whose excised four glands weighed 1080 mg and showed mild bone changes, the serum calcium level dropped from 10.2 mg/dl to only 7.8 mg/dl.

Calcium administration was much longer in Group B, although some patients could have been compensated by the hemodialysis, which is performed with a calcium content of 3.6 mEq/L.

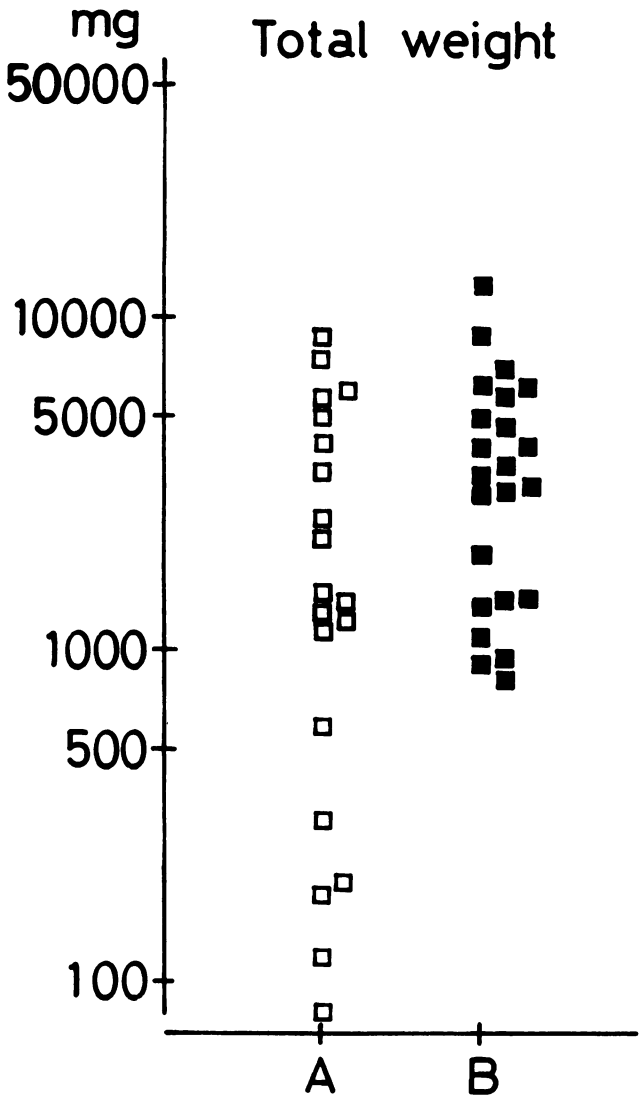

FIG. 1. Total weight of excised parathyroid glands of Groups A and B. Average: 2672 ± 2595 mg in Group A and 3932 ± 2839 mg in Group B.

In 17 of 23 patients, a parathyroid hormone gradient[7] could be demonstrated in blood withdrawn from the anticubital vein of the grafted arm, when compared with the nongrafted arm on the eighth to 68th day after surgery (average 26th day).

No functionless parathyroid grafts were found in any patient of Group B, and it has never been necessary to use the cryopreserved tissues in any patients.

Clinical Improvement After Surgery

In the patients of both groups clinical improvement after surgery was very remarkable. Bone pain was usually relieved within 24 to 48 hours, and pruritus usually disappeared in the first 2 or 3 days after the operation. Soft tissue calcium deposits either disappeared or were markedly diminished within 6 months after parathyroidectomy. The serum alkaline phosphatase level normalized more rapidly after surgery in Group B, and radiographic improvement of the bones after operation was more rapid in Group B also.

Recurrence

One patient in each group showed a recurrence and underwent another operation.

Patient 13, who underwent subtotal parathyroidectomy leaving one-half of the left upper gland (approximate weight, 550 mg), 2 years earlier had developed reelevation of the serum calcium, alkaline-phosphatase, and PTH levels (Fig. 2). Image diagnosis of the remaining left upper gland showed a remarkable enlargement.[1] Reexploration of the neck with a lateral approach[8] was carried out, and the remaining left upper gland (5220 mg) was excised, and a part of it was autografted into the forearm.

Patient 25, who had total parathyroidectomy and parathyroid autograft, earlier had shown reelevation of PTH associated with itching and irritability (Fig. 3); ^{201}TlCl scintigraphy of the forearm showed high uptake in the grafted area.[1] The transplanted parathyroid glands were gradually excised on three separate occasions under local anesthesia: the total weight was 6.0 g (Figs. 4, 5). Both patients recovered satisfactorily with none of the above symptoms following reoperations.

Mortality and Morbidity

No postoperative death resulted in either group. Forty-two of the 43 patients were still alive at this writing (1 month–10 years after surgery). The death of the one patient who passed away 10 months after surgery was ascribed to sepsis caused by gingival abscess.

Three patients temporarily developed unilateral palsy of the recurrent nerve. No septic complications were noticed in the neck or the forearm wound.

Discussion

The pathogenesis of renal osteodystrophy is complicated by a number of factors, including: (1) phosphate

TABLE 3. *Postoperative Supplemental Calcium Administration*

	Group A (N = 20)	Group B (N = 23)
Number of patients with calcium administration	8	21
Starting day of calcium administration (days)		
Mean	2.0	1.3
Range	1–5	1–3
Duration of calcium administration (days)		
Mean	15.6	59.5
Range	7–30	14–160

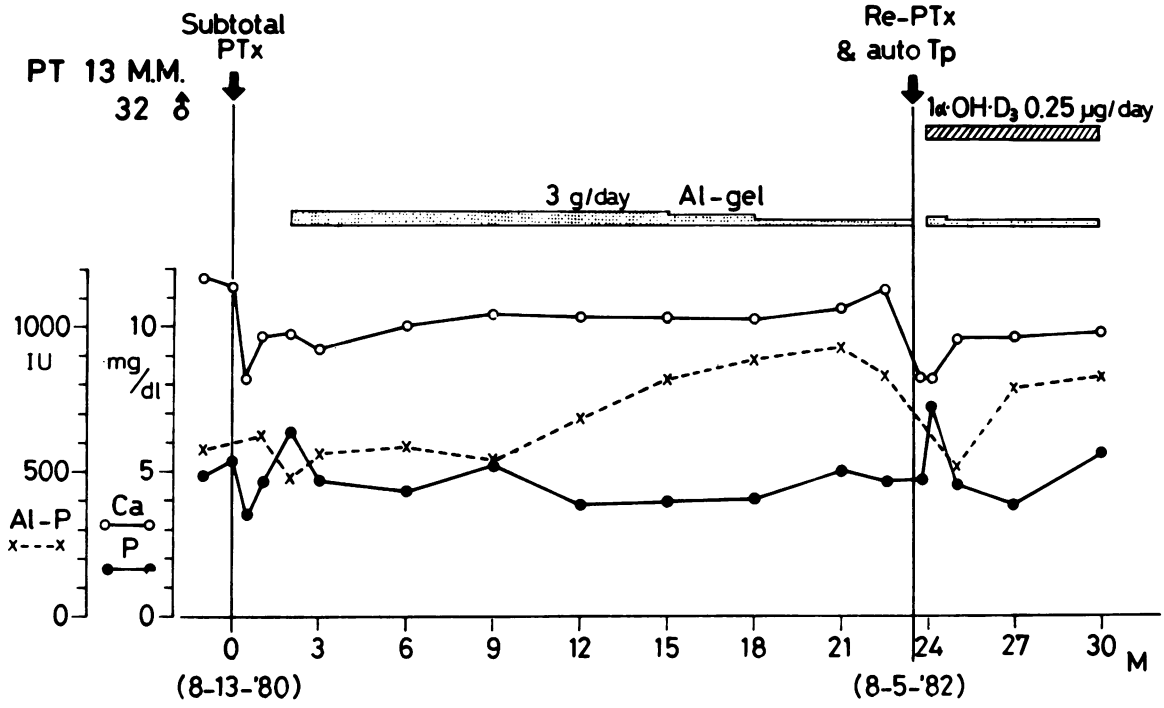

FIG. 2. Postoperative course of patient 13. PTx–Parathyroidectomy; Auto Tp–Autotransplantation in the forearm; Al-P–Serum alkaline phosphatase level; Ca–Serum calcium level; P–Serum phosphorus level; Al-gel–Dried aluminum hydroxide Gel.

retention, secondary to a decrease in the number of nephrons[9]; (2) failure of the diseased kidneys to hydroxylate 25-hydroxy-vitamin D to the biologically active metabolite, 1,25-dihydroxy vitamin D, with subsequent defective internal absorption of calcium[10]; (3) resistance of the bone to the action of parathyroid hormone (PTH)[11]; and (4)

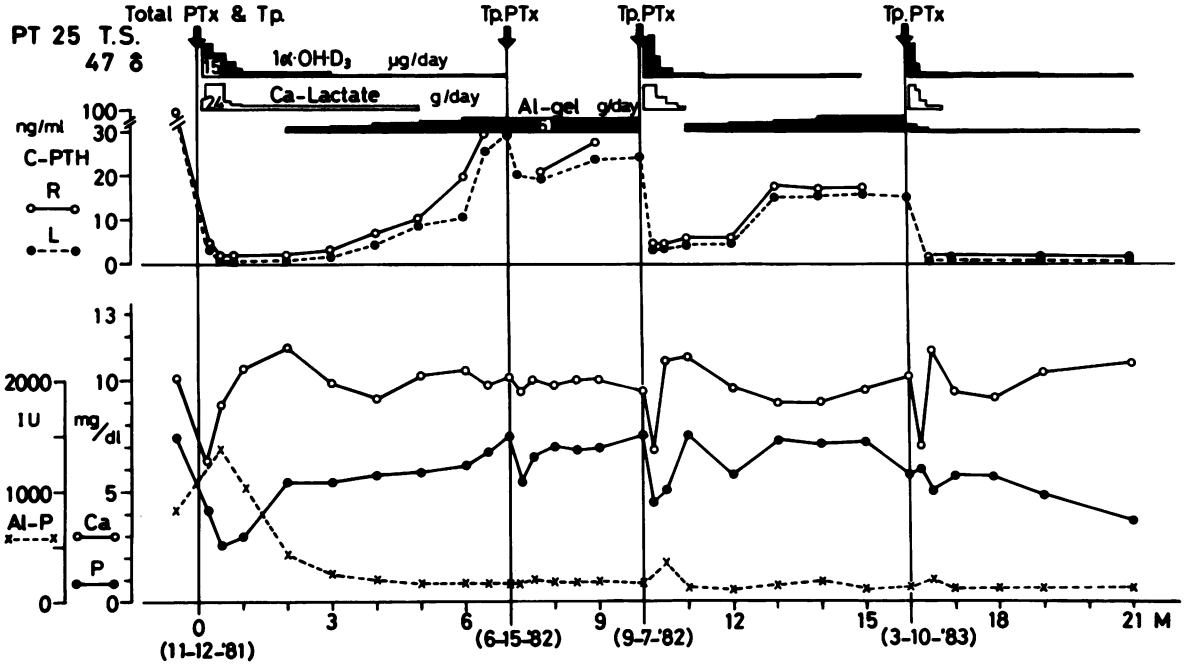

FIG. 3. Postoperative course of patient 25. Total PTx and Tp–Total parathyroidectomy and autotransplantation in the forearm; Tp PTx–Excision of transplanted parathyroid tissues; C-PTH–Serum C-terminal parathyroid hormone level; Al-P–Serum alkaline phosphatase level; Ca–Serum calcium level; P–Serum phosphorus level; Al-gel–Dried aluminum hydroxide Gel.

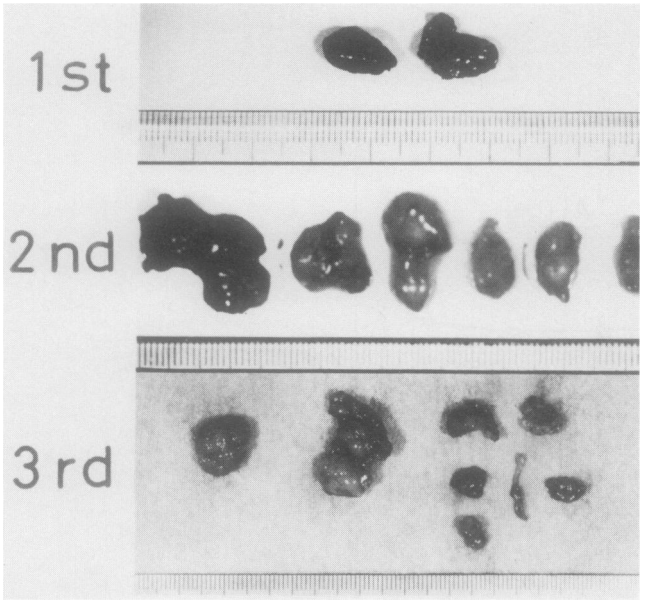

FIG. 4. Reexcised parathyroid glands on three separate occasions from the right forearm of patient 25.

aluminium absorption from dialysate.[12] Therefore, accurate diagnosis of secondary hyperparathyroidism is not always easy.

The recent introduction of CT, scintigraphy with $^{201}TlCl$ and $^{99m}TcO_4^-$, and ultrasonography have proven valuable for (1) definite diagnosis of secondary hyperparathyroidism, (2) localization, and (3) diagnosis for effectiveness of conservative treatment.[1,2]

The previous history of the patients who had been on hemodialysis treatment for a certain period was relatively uniform. There was no association with primary hyperparathyroidism, and the enlargement of the parathyroid glands was supposed to be secondary from the standpoint of end-stage renal failure. Although about 60% of these patients had four evenly enlarged parathyroid glands, some 40% of them showed four unevenly enlarged parathyroid glands with one or two glands weighing less than 100 mg.

Histopathologic patterns of hyperplasia are easily divided into two distinctly different patterns, diffuse and nodular. About 70% of these cases showed the same histopathological patterns of hyperplasia, either diffuse or nodular, in all excised glands. However, one or two of four glands in about 30% of the cases evidenced a different histopathological pattern. It is interesting that the four excised parathyroid glands of a given patient with chronic renal failure do not necessarily show similarities either in weight or the histopathologic pattern of hyperplasia.[13]

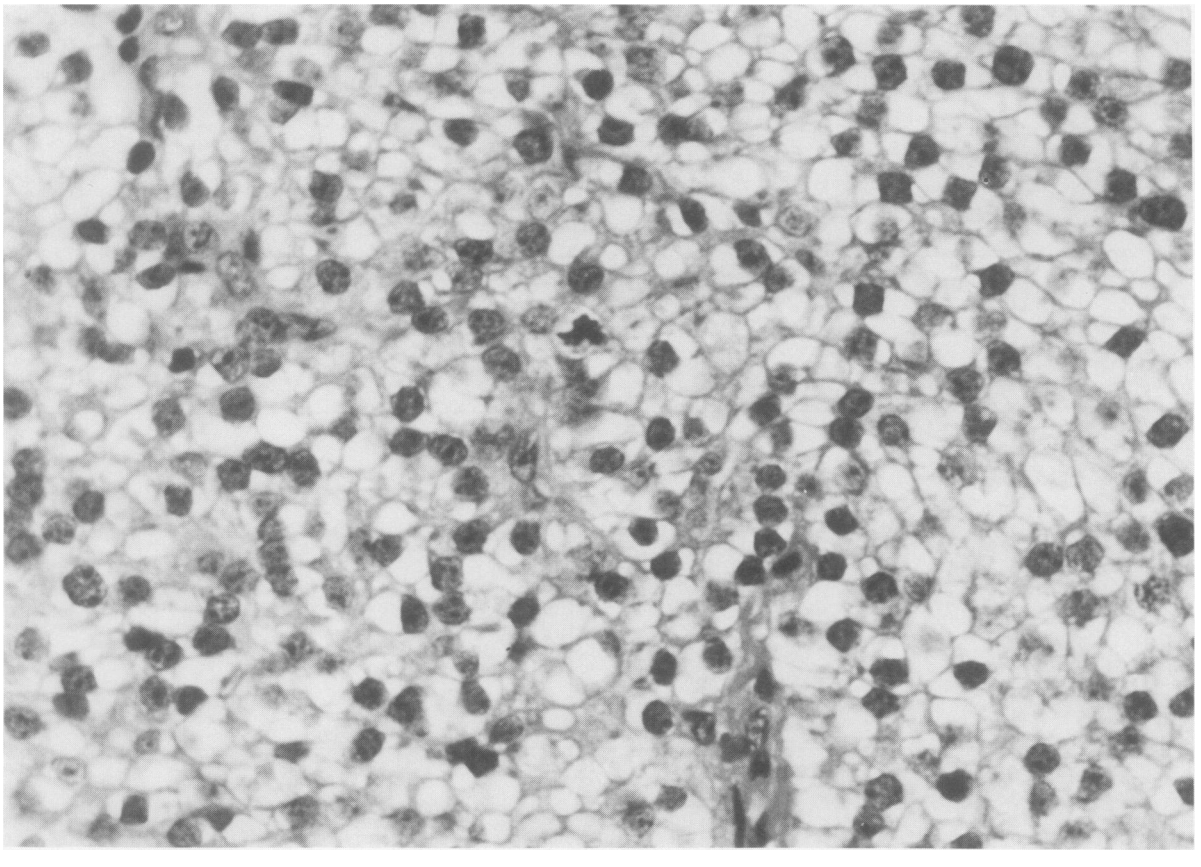

FIG. 5. Microscopic view of a removed parathyroid tissue fragment of patient 25 10 months after autotransplantation. Chief-cell hyperplasia with a mitosis in the center (H + E ×500).

As the surgical treatment for secondary hyperparathyroidism both subtotal parathyroidectomy and total parathyroidectomy with autotransplantation to the forearm resulted in almost the same clinical improvement. However, postparathyroidectomy recurrence of secondary hyperparathyroidism can be anticipated whether the parathyroidectomy is subtotal or total with parathyroid autotransplantation. With prolonged dialysis, the remnants may continue to develop hyperplasia and subsequently may require reexcision. The case of reoperation for recurrent disease in a total parathyroidectomy with autograft in the forearm, without the risk of a general anesthesia or recurrent largngeal nerve damage following reexploration of the neck, underscores the value of this approach when parathyroid glandular mass must be further reduced.[14]

The authors have never encountered any hypocalcemic syndrome in the immediate postoperative period whenever the serum calcium level was maintained above 7 mg/dl; this is hardly difficult with our protocol for postoperative management.

Although it has been reported that a majority of patients undergoing subtotal parathyroidectomy under hemodialysis treatment never required calcium supplementation,[3,5] eight of 20 of the present patients whose x-rays showed severe bone changes required supplemental calcium administration due to hypocalcemia during the immediate postoperative period.

The function of the grafted tissue was extremely satisfactory in all these patients. This experience in addition to other reports[7,15] suggests that cryopreservation of parathyroid tissue is not obligatory in these patients.

Recent approaches in subtotal parathyroidectomy leave *in situ* a remnant of parathyroid tissue of approximately the size of a normal gland (*e.g.*, 100 mg) in order to make this technique more effective. However, this is not always easy and sometimes accompanied by the risk of permanent hypoparathyroidism, particularly when four glands are evenly enlarged more than 1000 mg. The blood supply is so profuse that it is very difficult to stop bleeding from the cut surface of a small remnant of a parathyroid gland in such cases.

References

1. Takagi H, Tominaga Y, Uchida K, et al. Image diagnosis of parathyroid glands in chronic renal failure. Ann Surg 1983; 198:74–79.
2. Takagi H, Tominaga Y, Uchida K, et al. Preoperative diagnosis of secondary hyperparathyroidism using computed tomography. J Comput Assist Tomogr 1982; 6:527–528.
3. Malmaeus J. Secondary hyperparathyroidism in chronic renal failure. Scand J Urol Nephrol Suppl 1983; 70:1–63.
4. Wells SA, Gunnells JC, Shelburne JD, et al. Transplantation of the parathyroid glands in man: clinical indications and results. 1975; 78:34–44.
5. Wilson RE, Hampers CL, Bernstein DS, et al. Subtotal parathyroidectomy in chronic renal failure: a seven-year experience in a dialysis and transplant program. Ann Surg 1971; 174:640–654.
6. Diethelm AG, Adams PL, Murad TM, et al. Treatment of secondary hyperparathyroidism in patients with chronic renal failure by total parathyroidectomy and parathyroid autograft. Ann Surg 1981; 193:777–793.
7. Rothmund M, Wagner PK. Total parathyroidectomy and autotransplantation of parathyroid tissue for renal hyperparathyroidism. A one- to six-year follow-up. Ann Surg 1983; 197:7–16.
8. Feind CR. Re-exploration for parathyroid adenoma. Am J Surg 1964; 108:543–546.
9. Bricker NS, Slatopolsky E, Reiss E, et al. Calcium, phosphorus and bone in renal disease and transplantation. Arch Intern Med 1969; 123:543–553.
10. DeLuca HF. Vitamin D-1973. Am J Med 1974; 57:1–12.
11. Massry SG, Coburn JW, Lee DBN, et al. Skeletal resistance to parathyroid hormone in renal failure. Ann Intern Med 1973; 78:357–364.
12. Gorsky JE, Dietz AA. Aluminum concentrations in serum of hemodialysis patients. Clin Chem 1981; 27:932–935.
13. Takagi H, Tominaga Y, Uchida K, et al. Polymorphism of parathyroid glands in patients with chronic renal failure and secondary hyperparathyroidism. Endocrinol Japan 1983; 30:463–468.
14. Max MH, Flint LM, Richardson JD, et al. Total parathyroidectomy and parathyroid autotransplantation in patients with chronic renal failure. Surg Gynecol Obstet 1981; 153:177–180.
15. Wells SA, Farndon JR, Dale JK, et al. Long-term evaluation of patients with primary parathyroid hyperplasia managed by total parathyroidectomy and heterotopic autotransplantation. Ann Surg 1980; 192:451–458.