CASE REPORTS

Refer to: Scotvold MJ, Sareen C, Ruvalcaba RHA, et al: Acanthosis nigricans associated with tuberous sclerosis. West J Med 125:70-72, Jul 1976

Acanthosis Nigricans Associated with Tuberous Sclerosis

MARVIN J. SCOTVOLD, MD
CHANDRA SAREEN, MD
R. H. A. RUVALCABA, MD
VINCENT C. KELLEY, MD, PhD
Seattle

TUBEROUS SCLEROSIS is an autosomal dominant hereditary disease with variable expression. It is characterized clinically by mental retardation, seizures and numerous skin lesions—of which the most characteristic are the cutaneous angiofibromas mistakenly called "adenoma sebaceum." Pathologically it is characterized by multiple tumors and malformations involving the brain, skin and viscera. Various endocrinopathies have been described with tuberous sclerosis.[1]

The purpose of this paper is to describe the case of a severely retarded girl in which a diagnosis of tuberous sclerosis was made, and present the first reported association of acanthosis nigricans occurring with tuberous sclerosis.

Report of a Case

The patient is a 13-year-old white girl who is a resident of Rainier School, a State of Washington institution for the mentally and physically handicapped. She was born at term to a normal mother and father. Labor and vaginal delivery were spontaneous and uncomplicated; the birth weight was 7 pounds 10 ounces; and the neonatal period was unremarkable. Growth, developmental landmarks and language acquisition were normal until about 24 months of age when the parents noted the patient was becoming hyperactive and aggressive, and was progressively losing her speech. By 6 years of age, the patient did not speak and was unable to understand verbal commands. Seizures began at 12 months of age and were finally brought under control at 4 years of age with administration of phenytoin sodium (Dilantin®), phenobarbital and mephenytoin (Mesantoin®). Bilateral malar adenoma sebaceum papules became apparent between three and four years of age.

The patient was admitted to hospital at Seattle Children's Orthopedic Hospital and Medical Center at 5 years of age. On physical examination, she was found to be retarded and hyperactive. Small, discretely papular, slightly violaceous cutaneous angiofibromas, "adenoma sebaceum" lesions, distributed bilaterally on the malar area in a butterfly distribution were noted. There were

Figure 1.—Cutaneous patch of macular leukoderma.

From the Departments of Pediatrics and Medicine (Drs. Scotvold and Sareen); and the Division of Pediatric Endocrinology and Metabolism (Drs. Sareen, Ruvalcaba and Kelley); University of Washington School of Medicine, and the Rainier School, Buckley, Washington (Dr. Ruvalcaba).

This investigation was supported in part by Public Service Grants 2TI-AM-5190 and AM-05250 and by the Department of Social and Health Services, State of Washington.

Submitted, revised, February 20, 1976.

Reprint requests to: R. H. A. Ruvalcaba, MD, Ranier School, Community Services Division, P.O. Box 600, Buckley, WA 98321.

numerous leukodermic macules, "ash-leaf shaped white macules,"[2] scattered over the trunk, three small tan-brown, slightly elevated shagreen patches on the buttocks, and many punctate, focal, yellowish scar-like spots on the choroidal part of the retina. Findings on an electroencephalogram were abnormal, showing a spike wave focus in the anterior temporal region. On a pneumoencephalogram, very slight dilatation of the right lateral and superior portion of the third ventricles was noted. No further follow-up studies were undertaken and no intravenous pyelograms or skeletal survey x-ray studies were made. She was discharged with a diagnosis of tuberous sclerosis.

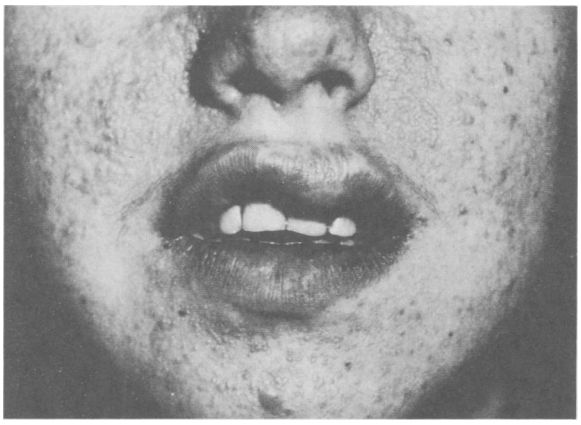

Figure 2.—Adenoma sebaceum papules of the face in a butterfly distribution of cheeks.

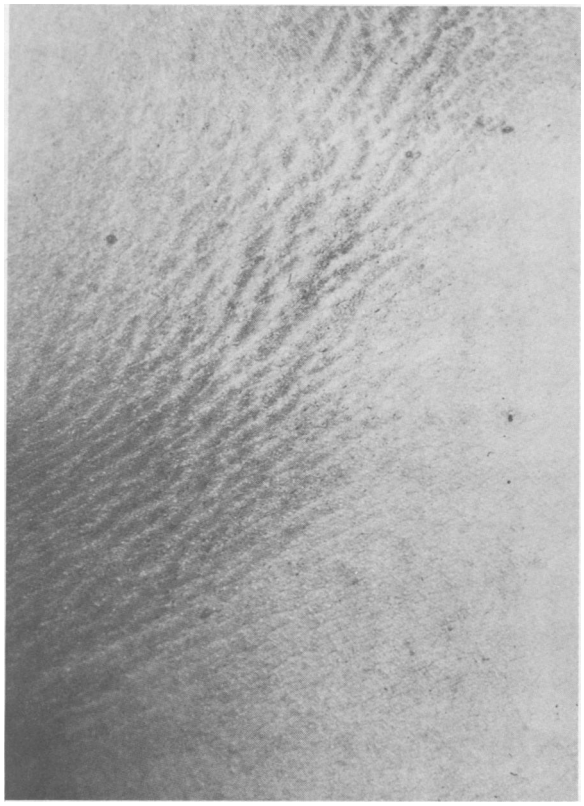

Figure 3.—Acanthosis nigricans on the axillae.

At 6 years of age, the patient was admitted to Rainier School. On physical examination at 13 years of age, it was noted that she was not obese, that she was profoundly retarded and that her mental age was 14 months. Also noted were multiple large cutaneous patches of macular leukoderma (Figure 1); papillary fibromas on the neck; varying sized shagreen patches in the lumbosacral and buttocks area; multiple bilateral erythematous adenoma sebaceum papules on the nose, malar area and chin (Figure 2), and a bilateral axillary vault eruption characterized by a soft, velvety, verrucous hyperpigmentation that was compatible with a clinical diagnosis of acanthosis nigricans (Figure 3). There were no periungual or oral fibromas, fibromatous plaques or nodules on the head or neck, or poliosis (circumscribed gray hair) in the eyebrows, lashes or scalp.

A skin biopsy study of the axillary acanthosis nigricans lesion (Figure 4) showed striking epidermal papillomatosis and moderate hyperkeratosis, with no significant acanthosis or hyperpigmentation. The suprapapillary plates projected upward as discrete finger-like projections, each containing abundant keratin within the valleys formed by each projection.

Findings on baseline laboratory studies were all within normal limits. These studies included a complete hemogram and urinalysis; determinations of blood urea nitrogen, serum electrolytes, calcium, phosphorus, bilirubin, alkaline phosphatase, serum glutamic oxaloacetic transami-

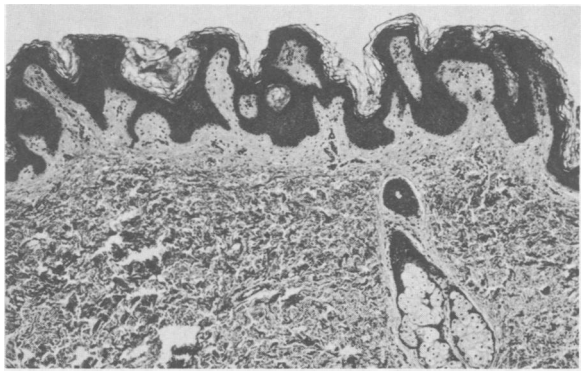

Figure 4.—Skin biopsy study of axillary lesion. Note the epidermal papillomatosis and moderate hyperkeratosis, with no significant acanthosis.

nase, serum glutamic pyruvic transaminase, cephalin flocculation and total plasma proteins with immunoelectrophoresis; x-ray films of the skull and chest bone age films; intravenous pyelogram; electrocardiogram, and electroencephalogram. Thyroid function, carbohydrate metabolism and the pituitary-adrenal axis were evaluated as previously reported.[1] The former both gave results within normal limits; however, the urinary steroid responses to intravenously given adrenocorticotropic hormone (ACTH) and metyrapone were found to be low, indicating a low adrenal reserve.[1]

Discussion

Acanthosis nigricans is a skin disorder of undetermined cause that can occur independently, as a result of a hereditary predisposition or as a cutaneous manifestation of any one of many underlying systemic or malignant diseases.[2,3] It presents clinically as a verrucous, hyperpigmented, hyperkeratotic cutaneous lesion that predominantly involves the folds or flexural areas of the skin in a symmetrical fashion. The normal skin markings are intensified, the cutaneous surface is studded with small papillomatous or nodular growths and the lesion has a striking soft, velvety texture. Although it has a predilection for the axilla, neck and groin, it can occur on the face, breasts, flexor creases of the elbows and knees, inner aspect of the thighs and mucous membranes.

Acanthosis nigricans has been found in association with underlying adenocarcinomas of the gastrointestinal tract, pancreas, prostate, ovary, breast and lung. It usually occurs in people over 40 years of age. It may be the first clinical expression of the tumor, and it usually runs a parallel course with the malignancy.[3,5] Acanthosis nigricans may be acquired as a rare autosomal dominant tract. As such, it may be present at birth, or it more commonly begins or is exacerbated at puberty. After puberty it generally becomes stationary or regresses.[4,6] Acanthosis nigricans can also occur as a part of several congenital syndromes. These include Bloom's syndrome, lipoatrophic diabetes, Wilson's disease and chondrodystrophy.[3,4,7] It has also been found in association with numerous metabolic and endocrine abnormalities including acromegaly; eosinophilic pituitary adenomas associated with gigantism; hypopituitarism secondary to a chromophobe adenoma; Cushing's disease; Addison's disease; Stein-Leventhal syndrome; hypothyroidism and hyperthyroidism; diabetes mellitus; benign encephalopathy, and pronounced obesity with nutritional, endocrine, or constitutional causes, and in patients treated with nicotine or oral contraceptives.[3,4,7-12] The degree of acanthosis nigricans associated with obesity appears to be proportional to the degree of obesity. The onset of acanthosis nigricans usually occurs at the time the obesity develops, tends to subside as the obesity subsides and usually disappears when the weight returns to normal.

The medical literature is replete with numerous and unnecessary divisions or subtypes of acanthosis nigricans.[2,3] These include malignant acanthosis nigricans and juvenile acanthosis nigricans. The latter has been further subdivided into benign acanthosis nigricans, acanthosis nigricans as part of several congenital syndromes, and pseudoacanthosis nigricans. However, acanthosis nigricans is one disease with the same clinical and histopathological manifestations no matter what other condition it is associated with. Therefore, if acanthosis nigricans is found in any patient, it should point toward a search for an underlying disease process. At this time, however, acanthosis nigricans should not be considered one of the expected cutaneous manifestations of tuberous sclerosis unless a significant number of patients with tuberous sclerosis are found to have acanthrosis nigricans.

Summary

This report describes the case of a 13-year-old severely retarded girl, the resident of an institution, in which diagnosis of tuberous sclerosis was made, and presents the first report of acanthosis nigricans occurring with tuberous sclerosis.

1. Sareen CK, Ruvalcaba RHA, Scotvold MJ, et al: Tuberous sclerosis: Clinical, endocrine, and metabolic studies. Am J Dis Child 123:34-39, Jan 1972
2. Fitzpatrick TB, Szabo G, Yoshiaki H, et al: White leaf-shaped macules: Earliest visible sign of tuberous sclerosis. Arch Derm 98:1-6, Jul 1968
3. Ebling FJ, Rook A: The epidermis and keratinization, *In* Rook A, Wilkinson DS, Ebling FJG (Eds): Textbook of Dermatology, Vol 2. Oxford, Blackwell Scientific Publications, 1968, chap 30, pp 1059-1062
4. Curth HD: Pigmentary changes of the skin associated with internal diseases. Postgrad Med 41:439-449, May 1967
5. Brown J, Winkelmann RK: Acanthosis nigricans: Study of 90 cases. Medicine (Balt) 47:33-51, Jan 1968
6. Curth HD, Acher BM: Genetic studies in acanthosis nigricans. Arch Derm 79:55-66, Jan 1959
7. Reed WB, Ragsdale W Jr, Curtis AC, et al: Acanthosis nigricans in association with various genodermatoses. Acta Dermatoverner (Stockholm) 48:465-473, 1968
8. Brown J, Winkelmann RK, Randall RV: Acanthosis nigricans and pituitary tumors. JAMA 198:619-623, Nov 7, 1966
9. Winkelmann RK, Scheen SR Jr, Underdahl LD: Acanthosis nigricans and endocrine disease. JAMA 174:1145-1152, Oct 1960
10. Scott RW, Klein AW, Leyden JJ: Acanthosis nigricans associated with a benign encephalopathy. Arch Derm 109:78-80, Jan 1974
11. Tromovitch TA, Jacobs PH, Kern S: Acanthosis nigricans-like lesions from nicotinic acid. Arch Derm 89:222-223, Feb 1964
12. Curth HO: Acanthosis nigricans following use of oral contraceptives. Arch Derm 111:1069, Aug 1975