J. Anat. (1986), **146**, pp. 105–115
With 8 *figures*
Printed in Great Britain

The adrenal and renal veins of man and their connections with azygos and lumbar veins

W. S. MONKHOUSE AND A. KHALIQUE

Department of Human Morphology, University of Nottingham Medical School, Nottingham NG7 2UH

(*Accepted* 9 *August* 1985)

INTRODUCTION

The normal textbook description of the asymmetrical disposition of human adrenal (suprarenal) veins is sufficiently well known to dispense with the need for its reiteration here. Variations in this pattern have been detailed by Pick & Anson (1940) and Anson, Cauldwell, Pick & Beaton (1948) and other workers have also given descriptions (Gagnon, 1956; Johnstone, 1957; Clark, 1959). The present study was prompted by a recent case of phaeochromocytoma in which blood catecholamine levels (assayed in this department) were high, not in the inferior vena cava near the levels of entry of the renal and adrenal veins (as is usually the case), but in the superior vena cava and the right atrium of the heart. This could be explained by postulating that the veins draining the adrenal gland might in some cases possess connections with the tributaries of the azygos system of veins, and this paper presents the results of a survey of renal and adrenal veins reporting on, amongst other things, the existence of such adrenal-azygos connections.

METHODS

The investigation was performed on 57 white European cadavers. Of these, 25 (16 female, 9 male) had previously been embalmed (although teaching requirements rendered only 13 of these suitable for study on the right side), and 32 were fresh postmortem specimens (24 female, 8 male). The survey therefore included 45 right sides and 57 left sides. Vessels were exposed by dissection and removal of surrounding fat and connective tissue. It was sometimes necessary to remove part of the liver in order to allow satisfactory access to the veins of the right adrenal gland. The aorta was removed to expose the prevertebral venous plexus, the roots of the azygos and hemiazygos veins and any connections of these with renal or adrenal veins. Deep dissection of the ascending lumbar and segmental lumbar veins involved the removal of the medial vertebral attachment of the psoas major muscle and its fibrous arches. All dissections were recorded as drawings or photographs. Measurements recorded in the text and in Tables 1 and 2 were made with a millimetre rule.

Table 1. *Dimensions of adrenal veins (mm)*

Right adrenal vein	
length	7·0 (4–15)
internal diameter	3·5 (2–6)
Left adrenal vein	
from adrenal gland to junction with inferior phrenic vein	
length	13·5 (2–32)
from junction with inferior phrenic vein to left renal vein	
length	16·0 (9–28)
internal diameter	4·5 (3–9)

Values expressed as means (range in parentheses).

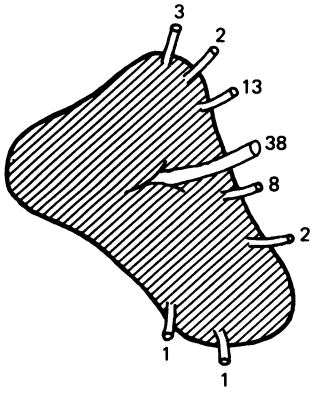

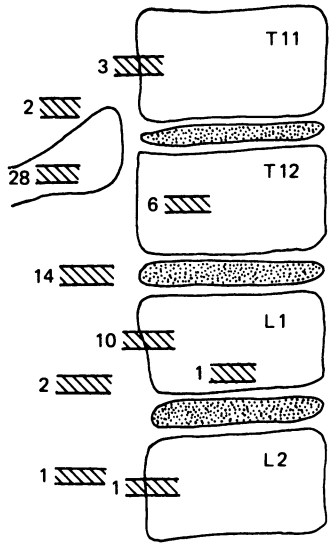

Fig. 1. Drawing showing the incidence (57 cadavers) of the position of emergence of the right central adrenal vein. Total number (including duplicated and triplicated specimens) = 68.

Fig. 2. Drawing showing the incidence (57 cadavers) of the position of entry of the right adrenal vein into the inferior vena cava in relation to both vertebral level and costovertebral junction. Total number (including duplicated and triplicated specimens) = 68.

RESULTS

Adrenal veins

Right adrenal vein (45 specimens)

Dimensions are given in Table 1. The position of exit of the main right adrenal vein from the anterior surface of the gland is shown in Figure 1. It most commonly entered the right posterolateral quadrant of the inferior vena cava at a level between the head and neck of the twelfth rib (Fig. 2), on average 45 mm (range 0–85 mm) above the entry of the right renal vein.

In 13 specimens the central vein was duplicated, and in 5 specimens it was triplicated. In these 18 specimens with duplication or triplication, two 'accessory' veins had connections with the right renal vein and were associated with the adrenal gland

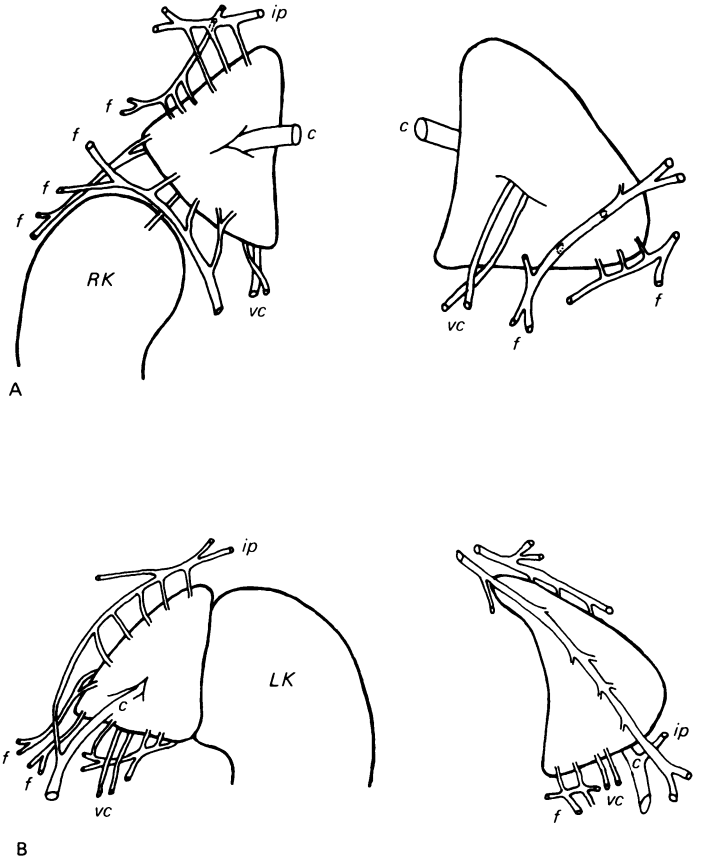

Fig. 3 (A–B). Drawings showing the superficial veins of the right (Fig. 3A) and left (Fig. 3B) adrenal glands. Anterior aspects are shown on the left, posterior aspects on the right. *RK*, right kidney; *LK*, left kidney; *c*, central vein; *f*, veins of perirenal fat; *ip*, inferior phrenic vein; *vc*, venae comitantes of inferior adrenal artery.

overlapping the medial border of the superior pole of the right kidney, the adrenal extending inferiorly as far as the hilum and resting on the right renal vein itself. In 4 specimens with duplication or triplication of the right adrenal vein, the 'accessory' veins were situated superiorly and communicated either with the inferior phrenic vein or with one of its tributaries.

The total number of main right adrenal veins in the 45 specimens (including duplications and triplications) was 68; of these, 26 veins approached the inferior vena cava from above, 11 approached more or less perpendicularly, and 31 approached from below.

The superficial veins of the right adrenal gland are shown in Figure 3A. From the superior border of the gland, most of these joined the inferior phrenic veins. From the posterior surface of the gland, most of the superficial veins joined the veins of the surrounding perirenal fat, and in 3 specimens these included veins emerging from the capsule which were substantially larger than the other superficial veins. From the inferior border of the adrenal gland, most superficial veins joined the veins of the perirenal fat, and in several specimens veins were seen to penetrate the renal capsule.

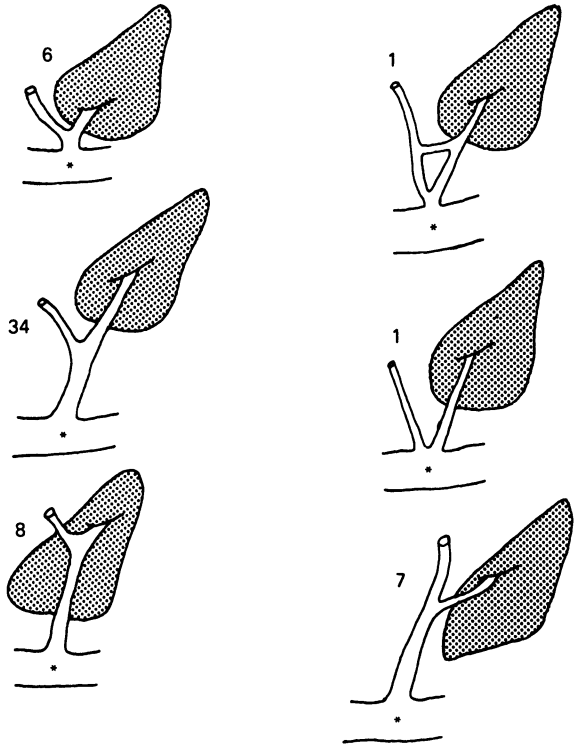

Fig. 4. Drawings showing the modes of formation of the adrenophrenic trunk by the junction of the left adrenal vein with the left inferior phrenic vein. Figures indicate incidence in 57 cadavers. Adrenal gland shaded. *, left renal vein.

Left adrenal vein (57 specimens)

Dimensions are given in Table 1. The central vein of the left adrenal gland joined the left inferior phrenic vein in 55 specimens to form an adrenophrenic trunk entering the left renal vein medial to the entry of the left gonadal vein, and in all but one specimen to the left of the aorta. Details of the formation of the adrenophrenic trunk are given in Figure 4. There was no instance in this study of duplication or triplication of the left adrenal vein.

The superficial veins of the left adrenal gland, examined only in the 25 embalmed cadavers, were similar to those of the right side and are shown in Figure 3B. From the posterior surface of the adrenal gland the venae comitantes of the inferior adrenal artery drained into the left renal vein. Also posteriorly were smaller vessels draining to the veins of the perirenal fat or occasionally to the left renal vein.

Connections of the superficial veins with the azygos venous system (25 embalmed cadavers only)

Communicating vessels connecting the adrenal and azygos veins were found in this study on the left side only. In 10 specimens a substantial vein was found posteriorly on the left side, and in 5 of these this vein (mean diameter 2·5 mm, range 1·5–4·5 mm) ran over the posterior surface of the adrenal gland receiving stumps from the gland. In the other 5 specimens, it emerged as a single trunk from the gland substance itself, thus resembling the main vein anteriorly. This posterior vein was

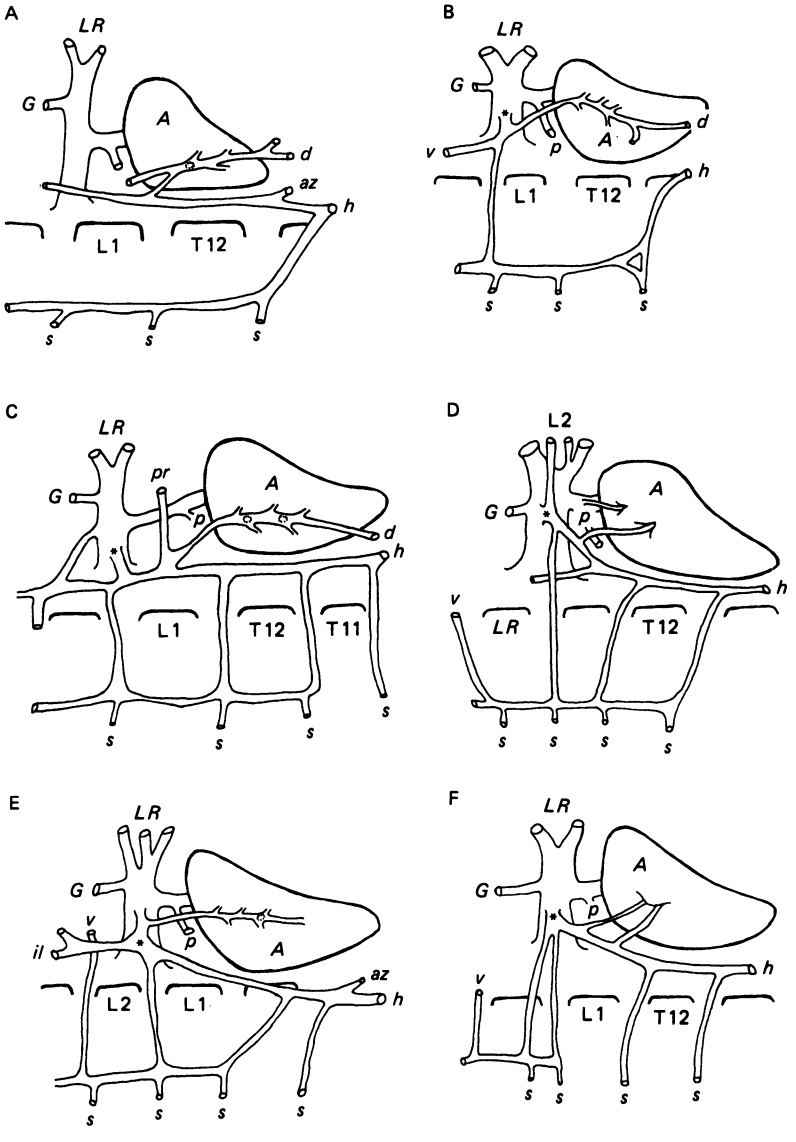

Fig. 5(A–F). Drawings illustrating various arrangements of veins posterior to the left kidney. The veins issuing from the renal hilum are shown uppermost in each drawing (marked *LR*) and are drawn as if lifted anteriorly to reveal their posterior aspects. *A*, adrenal gland; *G*, gonadal vein; *LR*, left renal veins issuing from hilum of left kidney; T12, L1, etc., vertebral levels; *az*, to azygos vein; *d*, from inferior surface of diaphragm; *h*, to hemiazygos vein; *il*, to left common iliac vein; *p*, left inferior phrenic vein; *pr*, posterior tributary (from the hilum) of left renal vein; *s*, segmental lumbar vein; *v*, to inferior vena cava. * denotes anastomotic channel connecting left renal vein with lumbar and/or azygos veins.

duplicated in two cadavers and triplicated in one. These vessels drained into the roots of the hemiazygos vein, and sometimes also to channels connecting lumbar veins with renal veins and the inferior vena cava (see below), the posterior surface of the main (anterior) adrenal vein and to the renal vein itself. Examples of these connections are shown in Figure 5.

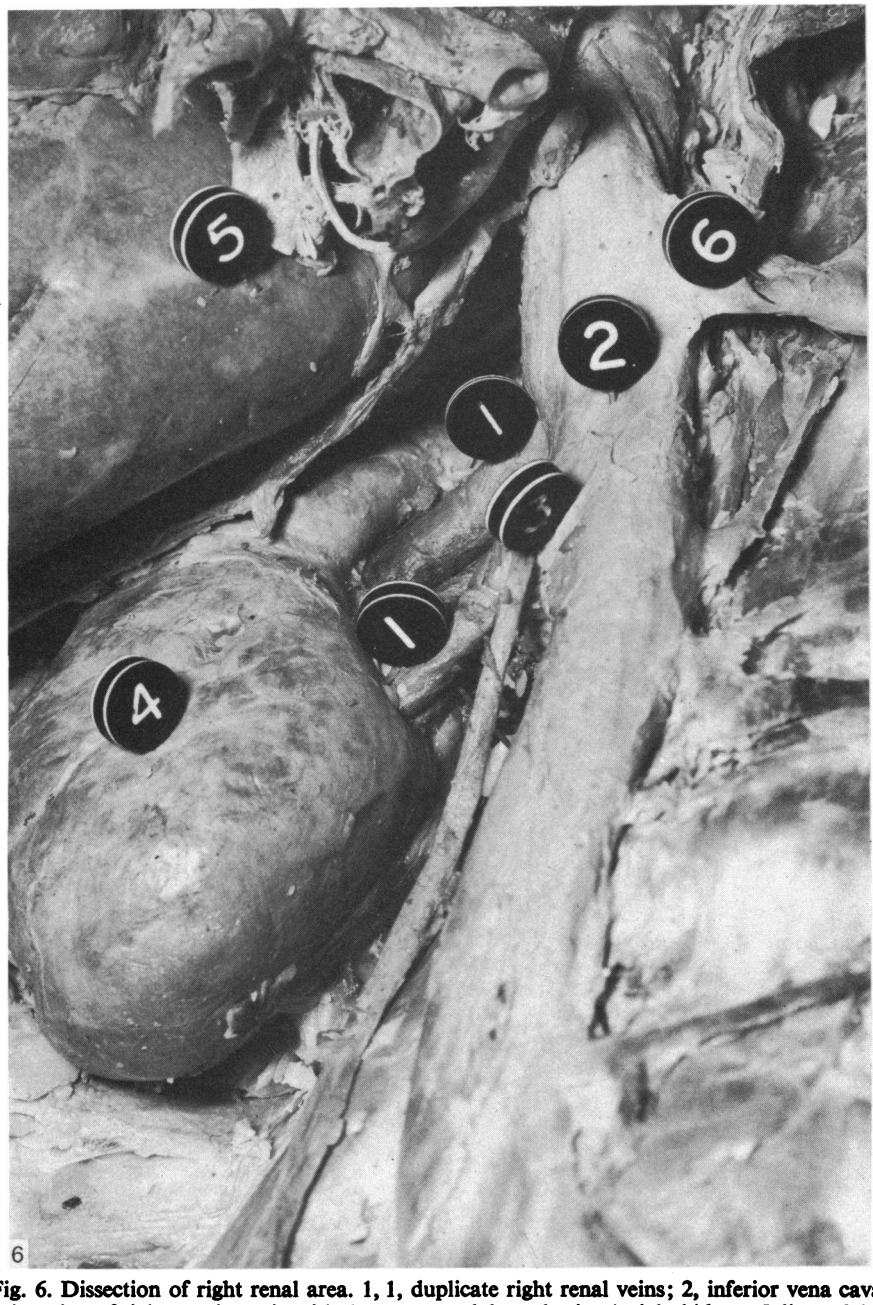

Fig. 6. Dissection of right renal area. 1, 1, duplicate right renal veins; 2, inferior vena cava; 3, junction of right ovarian vein with the more caudal renal vein; 4, right kidney; 5, liver; 6, left renal vein.

Renal veins (57 specimens)

Dimensions are given in Table 2. The position of entry of both renal veins into the inferior vena cava was just below the level of the intervertebral disc between the first and second lumbar vertebrae. In 31 specimens both renal veins joined the inferior vena cava at the same level; in 22 the right vein was slightly lower than the left vein, and in 4 it was slightly higher.

Table 2. *Dimensions of renal veins (mm)*

Right renal vein	
length	19·0 (12–30)
internal diameter	13·7 (10–19)
Left renal vein	
length	79·0 (50–100)
internal diameter at junction with left adrenophrenic trunk	12·3 (9–15)
internal diameter at junction with inferior vena cava	15.8 (12–21)

Values expressed as means (range in parentheses).

Right renal vein

This was formed by the confluence of between two and four vessels issuing from the hilum of the right kidney. In 7 specimens these tributaries included veins which passed dorsal to the renal pelvis. In 4 specimens there were accessory renal veins, of mean diameter 3·5 mm (range 2·0–5·0 mm) and mean length 31·0 mm (range 23–48 mm), passing from the medial border of the superior pole of the right kidney. Three of these passed directly to the inferior vena cava to enter above the main right renal vein; one arched inferiorly to join the main renal vein medial to the hilum of the right kidney. In one specimen, the right renal vein was duplicated with both veins lying adjacent, each entering the inferior vena cava through independent openings. In this cadaver the right ovarian vein joined the lower renal vein (Fig. 6).

Left renal vein

This was formed by the confluence of between two and four vessels issuing from the hilum of the left kidney. In 14 specimens these tributaries included veins which passed dorsal to the renal pelvis. This dorsal tributary (usually single but duplicated in one specimen) joined the main left renal vein 56 mm (range 42–78 mm) to the left of the inferior vena cava. In 5 of these 14 specimens, the dorsal tributary of the left renal vein (draining the renal parenchyma) communicated with other areas of the venous system (lumbar, renal and azygos veins – see below).

Left sided connections between renal and somatic veins

In 42 (out of 57) specimens there were venous channels communicating with the left renal vein which did not drain the renal parenchyma but which formed connections with segmental lumbar veins, and/or with the azygos system (hemiazygos on the left). Some of these also communicated with the inferior vena cava passing either ventral to the aorta (4 specimens) or dorsal to it (2 specimens), thus forming a circumaortic venous ring. In one specimen (Fig. 5 E) a vein was noted connecting the reno-azygo-lumbar vessels to the left common iliac vein, thus forming a left inferior vena cava. The left gonadal vein in this cadaver, however, took its normal course and terminated in the left renal vein rather than in this left inferior vena cava. In 29 specimens these connections were in accordance with the description of Lejars (1888): a posterior branch of the left renal vein which split into "une branche lombaire et une branche destinée à l'azygos, les deux réunies en un canal commun; canal réno-azygo-lombaire". This pattern and some variants are shown in Figures 5, 7, 8; Figures 5 F and 8 show specimens which conform to Lejars' description given above.

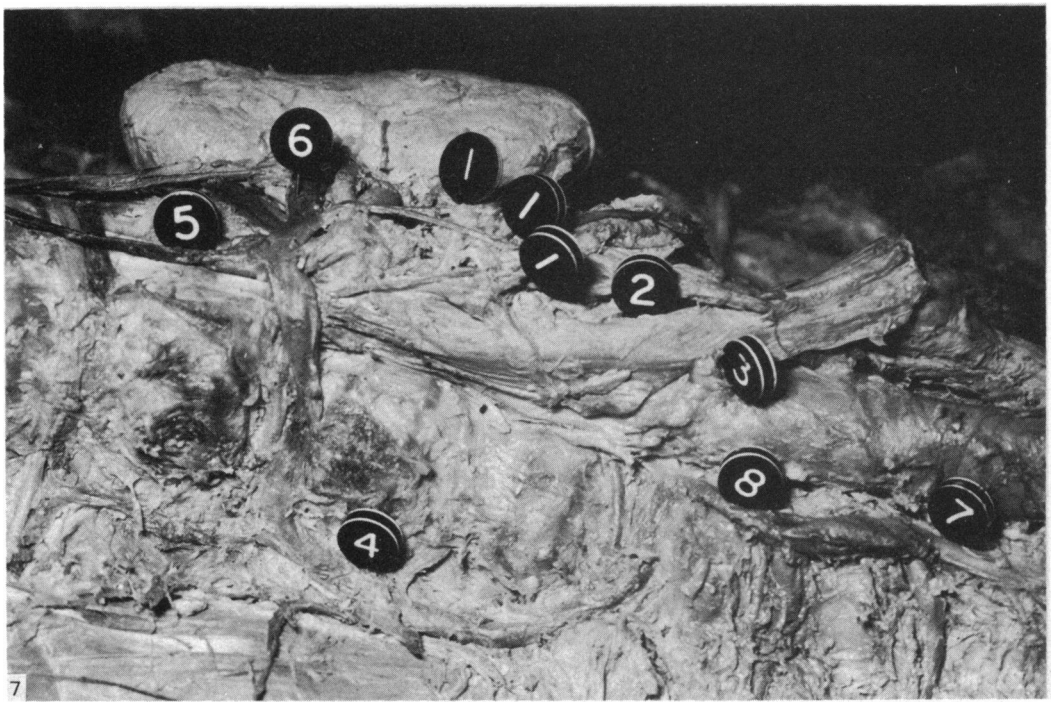

7



8

Fig. 7. Dissection of left renal area with left kidney lifted anteriorly and to the right to expose its posterior surface. 1, posterior superficial adrenal veins; 2, left crus of diaphragm; 3, aorta; 4, ascending lumbar vein (note communication from posterior aspect of left renal vein); 5, left gonadal vein; 6, posterior tributary of left renal vein; 7, 8, hemiazygos vein.

Fig. 8. Dissection of left renal area with left kidney lifted anteriorly and to the right to expose its posterior surface. 1, posterior tributary of left renal vein; 2, left renal artery; 3, left gonadal vein; 4, left ureter; 5, aorta; 6, reno-azygos channel; 7, reno-lumbar channel; 8, between coeliac and superior mesenteric arteries.

DISCUSSION

These findings on the right side of 18 out of 45 cases of duplication or triplication of the main adrenal vein conflict with those of Anson *et al.* (1948), since their study (on 450 cadavers) reported no duplication or triplication. The present findings are, though, in broad agreement with those of Cade (1954), and they also confirm Clark's observation (1959) of the existence of tributaries of the renal veins situated dorsal to the renal pelvis. However, while Clark found such vessels on the left side only, our work reports them on both sides. The formation of the adrenophrenic trunk on the left side, as reported in this paper, does not differ substantially from previous accounts (Anson *et al.* 1948; Cade, 1954; Gagnon, 1956; Johnstone, 1957; Hidai, 1976), although no cadaver in the present study showed a bifurcation of the left adrenal vein (as has been reported elsewhere).

The superficial veins usually omitted from textbooks of anatomy (and, surprisingly, by Anson *et al.* 1948) have been described previously (Johnstone, 1957; Mikaelsson, 1970; Miękoś, 1976). Gagnon argues that these superficial veins are unimportant in the drainage of the gland as a whole, but it seems likely that they may provide alternative drainage pathways in the event of blockage of the main veins, and they may have a role through their intraglandular connections (Dobbie & Symington, 1966) in the controversial proposition of bidirectional blood flow within the gland (Miękoś, 1976). They could also be implicated in the concept of a portal circulation for raw materials for the adrenal gland from extraglandular fat (Mikaelsson, 1970).

The variable and complex connections between the left posterior adrenal veins and the renal, lumbar and azygos systems would explain the high levels of adrenomedullary catecholamines found in the patient whose case was referred to in the Introduction; at operation, a large phaeochromocytoma was found on the left side, and the venous effluent from this tumour may well have been discharged via the azygos system in addition to or instead of via the left adrenal and renal veins. There are few other reports of such adreno-azygos connections, and although Gagnon (1956) mentions the drainage of the superficial adrenal veins into the azygos and hemiazygos veins, he neither describes them in detail nor gives the incidence.

Pick & Anson (1940) reported that accessory renal veins were much less common than accessory renal arteries. The present investigation found, on the right side, only 4 instances of accessory veins out of a total of 57 specimens. This incidence (7·2 %) is lower than that of Pick & Anson (27·8 %). Accessory veins on the left side are even rarer: Pick & Anson give an incidence of 1 %; in this study none was found.

Many of the variations in the disposition of the renal veins and the connections between renal and somatic veins (including circumaortic venous rings and left inferior vena cava) have been described in detail elsewhere (Davis, Milloy & Anson, 1958; Milloy, Anson & Cauldwell, 1962). They may be explained by the embryological development of the abdominal venous structures which involves, briefly, the conversion of a symmetrical cardinal venous system to an asymmetrical arrangement with, normally, the inferior vena cava on the right (McClure & Butler, 1925; Gladstone, 1929; Chuang, Mena & Hoskins, 1974*a*, *b*). The classical description of a circumaortic venous ring usually involves the division of the left renal vein to give a preaortic and a retroaortic component, usually implying that these two components are of similar size. In this present study, however, the two cases of circumaortic venous ring both involved retroaortic components of relatively small diameter: they could not be described as being the result of a bifurcation of the renal vein.

Without doubt, in the cases in this study the main vein passed in its normal position ventral to the aorta.

The pattern described by Lejars (1888) was found in this study in 29 out of 57 cadavers, less than the 42 out of 50 reported by Auvert (1967). None the less, some sort of communication between renal, lumbar and azygos (hemiazygos) veins was found in 42 out of 57 cadavers. Certainly, all the posterior collateral trunks of the left renal vein are indicative of its potential capacity to act as a connecting pathway between the inferior and superior venae cavae. Lejars, in the same paper, also reported the existence of connections between the renal capsular network of veins and the hepatic portal or mesocolic veins: we found no such connection in this study.

SUMMARY

There exist many variations in the manner of formation, dimensions and place of termination of the central adrenal veins. In addition, some superficial adrenal veins may be substantial in size and may themselves drain directly into the renal veins and/or into other vessels which communicate with azygos and lumbar veins. This provides a route for venous adrenal blood to the heart via the azygos system and the superior vena cava rather than via the inferior vena cava. Variations in the formation and disposition of the renal veins are also described and the patterns of communication between somatic veins (including veins of the azygos and lumbar systems) and the left renal vein are illustrated and discussed in relation to the findings of others.

We gratefully acknowledge the support and encouragement of Professor R. E. Coupland, the general assistance of Mr F. Young and Mr C. Binch, and the photographic skills of Mr A. S. Pyper and Mr I. Harriman.

REFERENCES

ANSON, B. J., CAULDWELL, E. W., PICK, J. W. & BEATON, L. E. (1948). The anatomy of the pararenal system of veins, with comments on the renal arteries. *Journal of Urology* **60**, 714–737.

AUVERT, J. (1967). La veine rénale gauche. *Presse médicale* **75**, 1405–1407.

CADE, S. (1954). Adrenalectomy for hormone dependent cancers: breast and prostate. *Annals of the Royal College of Surgeons of England* **15**, 71–107.

CHUANG, V. P., MENA, C. E. & HOSKINS, P. A. (1974*a*). Congenital anomalies of the inferior vena cava: a review of embryogenesis and presentation of a simplified classification. *British Journal of Radiology* **47**, 206–213.

CHUANG, V. P., MENA, C. E. & HOSKINS, P. A. (1974*b*). Congenital anomalies of the left renal vein: angiographic consideration. *British Journal of Radiology* **47**, 214–218.

CLARK, K. (1959). The blood vessels of the adrenal gland. *Journal of the Royal College of Surgeons of Edinburgh* **4**, 257–262.

DAVIS, R. A., MILLOY, F. J. & ANSON, B. J. (1958). Lumbar, renal, and associated parietal and visceral veins based upon a study of 100 specimens. *Surgery, Gynecology and Obstetrics* **107**, 1–22.

DOBBIE, J. W. & SYMINGTON, T. (1966). The human adrenal gland with special reference to the vasculature. *Journal of Endocrinology* **34**, 479–489.

GAGNON, R. (1956). The venous drainage of the human adrenal gland. *Revue canadienne de biologie* **14**, 350–359.

GLADSTONE, R. J. (1929). Development of the inferior vena cava in the light of recent research, with especial reference to certain abnormalities, and current descriptions of the ascending lumbar and azygos veins. *Journal of Anatomy* **64**, 70–93.

HIDAI, H. (1976). Studies on locality diagnosis of adrenal tumours: anatomical study on adrenal and juxta-adrenal veins in Japanese and its contribution to adrenal vein catheterization method. *Japanese Journal of Urology* **67**, 1018–1024.

JOHNSTONE, F. R. C. (1957). The suprarenal veins. *American Journal of Surgery* **94**, 615–620.

LEJARS, F. (1888). Les voies de sûreté de la veine rénale. *Bulletin et Mémoires de la Société anatomique de Paris* (Mai) 63-ième année, 5-ième série, 504–511.

McClure, C. F. W. & Butler, E. G. (1925). The development of the inferior vena cava in man. *American Journal of Anatomy* **35**, 331–383.

Milloy, F. J., Anson, B. J. & Cauldwell, E. W. (1962). Variations in the inferior caval veins and in their renal and lumbar communications. *Surgery, Gynecology and Obstetrics* **115**, 131–142.

Miękoś, E. (1976). Connections of superficial and internal adrenal veins. *International Urology and Nephrology* **8**, 277–281.

Mikaelsson, C. G. (1970). Venous communications of the adrenal glands. Anatomic and circulatory studies. *Acta radiologica diagnosis* **10**, 369–393.

Pick, J. W. & Anson, B. J. (1940). The renal vascular pedicle. *Journal of Urology* **44**, 411–434.