J Clin Pathol 1988;**41**:633–643

Tumour associated antigens in diagnosis of serous effusions

J MEZGER,*‡ W PERMANETTER,‡ A L GERBES,† W WILMANNS,*‡ R LAMERZ†

*From the Departments of Medicine *III and †II, Klinikum Grosshadern, the ‡Department of Pathology, University of Munich and the Institute of Clinical Haematology, Munich, West Germany*

SUMMARY The use of tumour associated antigens in the diagnosis of serous effusions was studied in 76 patients with benign and 200 patients with malignant disease. Tissue polypeptide antigen (TPA), α fetoprotein, and CA 125 were found to be of little value. At cut off points of 3 ng/ml, 10 U/ml, and 30 U/ml, respectively, carcinoembryonic antigen (CEA), biliary glycoprotein I (BGP I), and CA 19-9 discriminated between benign and malignant serous effusions with a sensitivity of between 24% and 67%. The immunocytochemical staining for these markers resulted in malignant cells being detected in 18% to 33% of cases. Various combinations of conventional cytological examination, effusion fluid tumour marker determination, and immunocytochemical analysis identified malignant cells in serous effusions in up to 72% of cases; conventional cytology alone detected tumour cells in only 30%.

We describe an investigation into the use of tumour markers for the discrimination of benign and malignant serous effusions. Although conventional cytology, the classic diagnostic tool for ascitic and pleural effusions, detects malignant cells with a specificity of almost 100%, its sensitivity is unsatisfactory. Various investigators have reported that routine cytological examinations recognise malignant cells in serous effusions with a sensitivity of between only 28 and 60%.[1-6] In our series positive cytological results were noted in only 42 of 139 (30%) serous effusions from patients with histologically confirmed malignancies.

Tumour associated antigens may be used in the diagnosis of serous effusions in two ways: firstly, the antigen titres may be determined in the effusion fluid by methods used for the examination of serum; secondly, the antigens may be detected immunocytochemically in cells from the effusion.

For carcinoembryonic antigen (CEA), tissue polypeptide antigen (TPA), biliary glycoprotein I (BGP I), and CA 19-9 and CA 125, we tested the ability of both methods to discriminate between benign and malignant causes of serous effusions and, in addition, the value of determining concentrations of α fetoprotein (AFP) in serous effusion fluid. Serum concentrations of CEA and CA 125 were also determined in some of the patients.

Accepted for publication 9 February 1988

Patients and samples

One hundred and seventy six pleural effusions, 97 ascitic effusions, and three abdominal drainage fluid specimens were collected from 276 patients aged between 18 and 83 years. Two hundred samples came from patients who had been documented as having malignant disease on the basis of clinical evaluation together with radiological studies, surgical biopsy, or necropsy. In all but eight cases the origin of the neoplasm was clearly established. In 76 patients none of the examinations showed evidence of malignant disease. The diagnoses of all patients are listed in table 1. Necropsy was performed in 32 patients between one week and one year after collection of serous effusion fluid samples. In all but two malignant cases (n = 24) tumour was found in the pleura or peritoneum.

CONVENTIONAL CYTOLOGY

Conventional cytological diagnoses were made by three independent observers without knowledge of the clinical diagnoses from cytospin preparations stained by the Pappenheim technique and periodic acid Schiff reagent. The findings were recorded as "positive", "negative", or "suspicious" for the presence of malignant cells.

IMMUNOCYTOCHEMICAL STAINING ANTIBODIES

Indirect immunocytochemical staining using peroxidase or alkaline phosphatase conjugated antibodies

Table 1 *Diagnosis in 273 patients with ascitic and pleural effusions*

	Ascitic	*Pleural*
Benign effusions:		
Cirrhosis of liver	27	1
Congestive heart failure	3	5
Alcoholic hepatitis	1	
Ovarian fibroma	1	
Osteomyelofibrosis	1	
Chiari disease	1	
Tuberculosis		9
Pneumonia		6
Viral pleuritis		5
Connective tissue disease		2
Amyloidosis		1
Mediastinal tumour, complete remission after radiation		4
Bronchial tumour, complete remission after pneumonectomy		2
Bronchial adenoma		1
Pancreatitis		1
Perforated gastric ulcer		1
Rupture of the oesophagus		1
Malignant effusions:		
Carcinomas		
Gastrointestinal	20	7
Ovary	15	7
Breast	14	51
Kidney	1	5
Non-small cell lung cancer		5
Small cell lung cancer		5
Various	2	1
Unknown primary	4	4
Lymphomas/leukaemias	4	21
Mesotheliomas		8
Sarcomas	2	4
Melanomas		2
Teratomas		1

was performed by our own modification of standard techniques, as previously described.[7 8] For immunocytochemical studies we used the following antibodies: rabbit polyclonal antibodies to CEA, absorbed with human lung and colon mucosa extract, as previously described;[9] murine monoclonal antibodies to CEA (CEA-84, from Hofmann-LaRoche, Basel, Switzerland) and two of our own monoclonal antibodies; rabbit polyclonal antibodies to TPA (Mallinckrodt Diagnostica, Dietzenbach, West Germany); rabbit polyclonal antibodies to BGP I-like antigen, prepared as previously described;[10] monoclonal antibody OC 125 to the antigen CA 125 (kindly provided by Dr RC Bast, Boston, USA); monoclonal antibody to CA 19-9 (Isotopen Diagnostik, Dreieich, West Germany); and immunoglobulins from a murine myeloma cell line as controls.

EFFUSION FLUID TUMOUR MARKER ASSAY

After centrifugation at 3000 rpm for 20 minutes, the samples were frozen at −20°C and stored for up to six months before assay. CEA, α fetoprotein, and BGP I concentrations were determined by a double antibody radioimmunoassay, as previously described,[9 10] TPA by a commercial radioimmunoassay, and CA 19-9 and CA 125 by commercial immunoradiometric assays (Mallinckrodt Diagnostica, Dietzenbach, West Germany) according to the manufacturer's instructions. CEA and CA 125 concentrations were also determined in samples collected within three days after or before the puncture of the effusion in some of the patients.

The Mann-Whitney U test was used to assess the significance of differences in tumour marker values among patients with benign and malignant diseases. The χ^2 test was used to assess the correlation of tumour marker concentrations in serous effusion fluid and positive immunocytochemical findings. For comparison of serous effusion fluid and serum tumour marker values, the linear regression and the rank correlation coefficient (r_s) were determined. Optimal cut off limits for the discrimination of benign and malignant serous effusions were set with the use of receiver operating characteristic (ROC) diagrams. All statistical tests were performed as described by Sachs.[11]

Results

CONVENTIONAL CYTOLOGY

Malignant cells were recognised morphologically in 36 of 106 (34%) specimens from patients with carcinomas, three of 19 lymphomas/leukaemias, one of six sarcomas, one of seven mesotheliomas, and in one melanoma. In all other malignant cases the diagnosis of "suspicious" or "negative" was recorded; in 50 samples from benign diseases the diagnosis was "negative". In 87 patients serous effusion fluid only had been examined and conventional cytological diagnoses were not available.

IMMUNOCYTOCHEMICAL STAINING

In the control specimens eosinophilic and basophilic granulocytes were stained by the immunoperoxidase technique. None of the CEA antibodies stained mesothelial cells, lymphocytes, or macrophages. With the polyclonal anti-CEA and our own monoclonal antibodies to CEA, all granulocytes were positive with the peroxidase and the alkaline phosphatase method. Stained granulocytes could be easily distinguished from other positive cells by their morphology. CEA-84 did not stain any cells in benign effusions. Effusions containing positive cells apart from granulocytes were found in the same way with all CEA antibodies, mainly in patients with carcinomas of the breast, gastrointestinal tract, and non-small cell lung cancer (table 2). By their morphology and by comparison with Pappenheim stained slides, all CEA positive cells other than polymorphs seemed to be carcinoma cells (fig 1). Rabbit anti-CEA was used for most examinations as it gave the most intense staining.

In almost all specimens a diffuse or droplet-like

Table 2 *Detection (%) of tumour cells by cytology, immunocytochemistry, and combination of both methods in 136 patients*

		Positive findings				
			Immunocytochemistry			
	(n=)	*Cytology*	*CEA*	*BGP I*	*CA 19-9*	*Cytology and immunocytochemistry*
Carcinomas	87	34	27	18	33	66
Breast	32	19	31	12	6	56
Ovary	15	80	0	13	46	87
Gastrointestinal	15	40	47	13	60	73
Non-small cell lung cancer	14	29	57	35	57	64
Small cell lung cancer	2	50	0	0	50	50
Kidney	4	0	0	0	0	0
Various/unknown primary	5	20	20	60	40	60
Mesotheliomas	5	20	0	0	0	20
Lymphomas, leukaemias	14	2	0	0	0	14
Sarcomas	3	0	0	0	0	0
Benign diseases	27	0	0	0	0	0

staining of the cytoplasm of mesothelial cells was noted with TPA. When carcinoma cells could be distinguished from mesothelial cells by morphological criteria, they were found to be positive. Lymphocytes, granulocytes, and macrophages were not stained.

Granulocytes were positive in all cases with anti-BGP I. Apart from granulocytes, cells stained by anti-BGP I were found only in carcinomatous effusions, and these positive cells were characterised by their morphology as carcinoma cells (fig 2). A droplet-like staining of the cytoplasm of mesothelia was also observed in some cases. Effusions containing mesothelial or carcinoma cells positive for BGP I were found in patients with breast and gastrointestinal carcinomas and non-small cell lung cancer. In two cases of ovarian carcinoma, tumour cells were weakly stained.

In 11 of 14 serous effusions of ovarian carcinoma, tumour cells were labelled by OC 125. Positive cells, however, were also found in benign effusions and could be defined by their morphology as small clusters of proliferating mesothelia (fig 3), and occasionally as

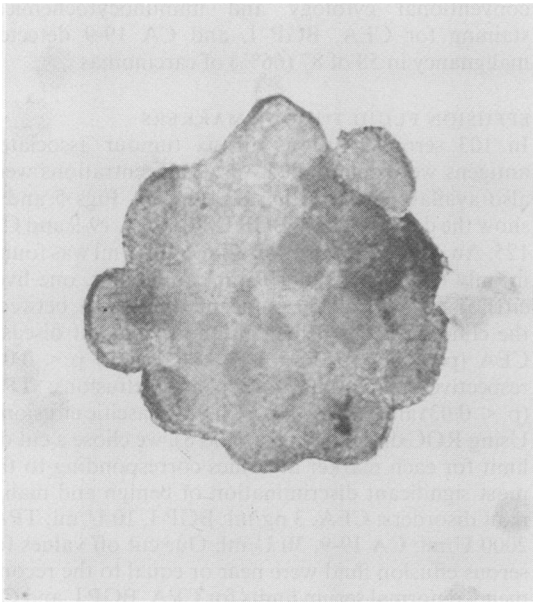

Fig 1 *Pleural effusion in non-small cell lung cancer, polyclonal anti-CEA, immunoperoxidase method: staining of carcinoma cell cluster.*

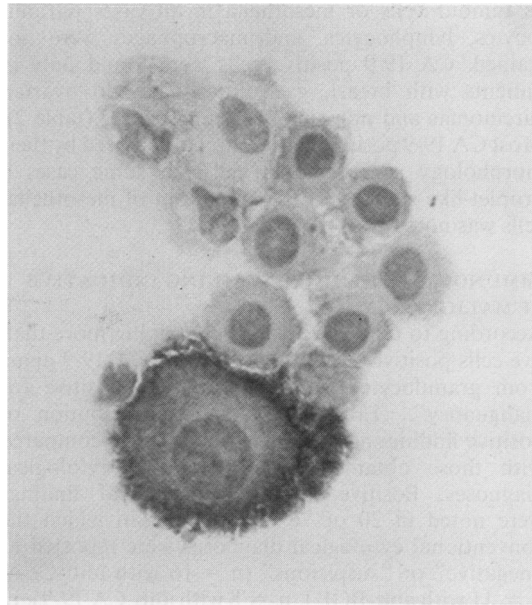

Fig 2 *Pleural effusion in breast carcinoma, anti-BGP I, immunoperoxidase method: staining of a single carcinoma cell.*

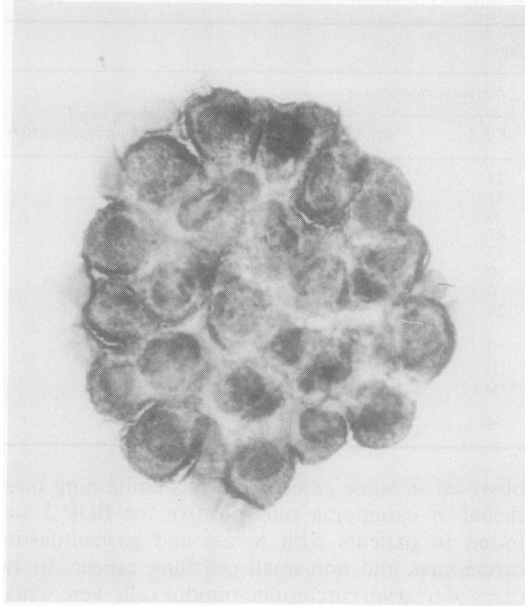

Fig 3 *Ascitic effusion in ovarian fibroma, OC 125, immunoperoxidase method: droplet-like staining of mesothelial cells.*

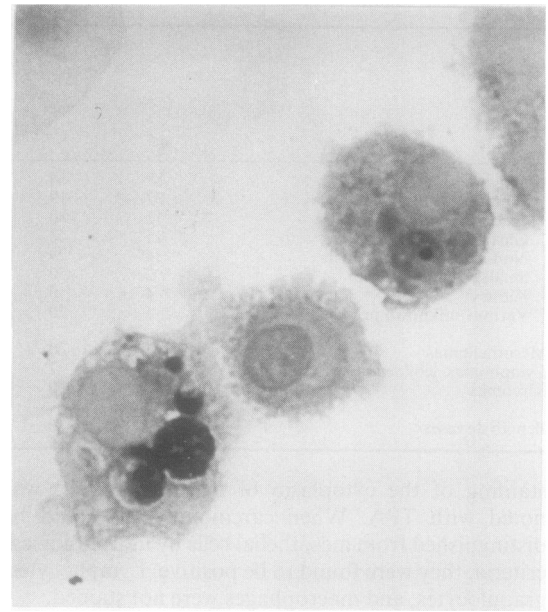

Fig 4 *Pleural effusion in breast carcinoma anti-CA 19-9, immunoperoxidase method: droplet-like staining of mesothelial cells.*

single mesothelial cells. CA 125 positive cell clusters and single cells were also observed in carcinomatous effusions. These cells could not be positively identified as tumour cells or mesothelia in all cases. Granulocytes, lymphocytes, and macrophages were not stained. CA 19-9 positive cells were found only in patients with breast, gastrointestinal, and ovarian carcinomas and non-small cell lung cancer (table 2). Most CA 19-9 positive cells were characterised by their morphology as carcinoma cells. In some cases a droplet-like staining of the cytoplasm of mesothelial cells was noted (fig 4).

IMMUNOCYTOCHEMICAL STAINING INDICATIVE OF MALIGNANCY

According to Ghosh, effusions containing more than five cells positive for CEA, BGP I, or CA 19-9 apart from granulocytes were classified as "positive for malignancy".[1] Table 2 shows the distribution of positive findings according to tumour type compared with those obtained by conventional cytological diagnoses. Positive immunocytochemical findings were noted in 20 of 76 (26%) cases in which the conventional cytological diagnoses were reported as "negative" or "suspicious" (n = 16 with anti-CEA, n = 11 with anti-BGP I, n = 8 with anti-CA 19-9). In 87 carcinomas tumour cells were identified in 30 (34%) serous effusions by conventional cytology alone. When immunocytochemical staining for only one marker was used in addition to conventional cytology, carcinoma cells were detected in 53% (CEA), 47% (BGP I), and 43% (CA 19-9). The combined use of conventional cytology and immunocytochemical staining for CEA, BGP I, and CA 19-9 detected malignancy in 58 of 87 (66%) of carcinomas.

EFFUSION FLUID TUMOUR MARKERS

In 103 serous effusions all six tumour associated antigens were determined; CEA concentrations were also available in a further 83 samples. Figs 5 and 6 show the data for CEA, BGP I, TPA, CA 19-9 and CA 125. An AFP concentration above 15 ng/ml was found in only five ascitic fluids (four carcinomas, one liver cirrhosis). We found significant differences between the concentrations in benign and malignant disease: CEA ($p < 0{\cdot}001$); BGP I ($p < 0{\cdot}05$ and $p < 0{\cdot}02$, respectively) in ascitic and pleural effusions; TPA ($p < 0{\cdot}03$) and CA 19-9 ($p < 0{\cdot}02$) in ascitic effusions. Using ROC diagrams (figs 7 and 8), we chose a cut off limit for each marker at values corresponding to the most significant discrimination of benign and malignant disorders: CEA, 3 ng/ml; BGP I, 10 U/ml; TPA, 2000 U/ml; CA 19-9, 30 U/ml. Our cut off values for serous effusion fluid were near or equal to the recommended normal serum limits for CEA, BGP I, and CA 19-9. They were about 20 times higher for TPA and unobtainable for CA 125.

The sensitivity, specificity, and positive and negative

predictive values for each marker and for the combination of two and three markers for these cut off limits are listed in table 3. The prevalence of increased concentration depended on the site of the primary lesion (table 4). In cases of benign disease with increased concentrations of serous effusion fluid tumour markers, CEA concentrations were raised in bronchial adenoma, pulmonary fibrosis after surgery, and after radiation of a thymoma with complete recovery over five years, in tuberculous and viral

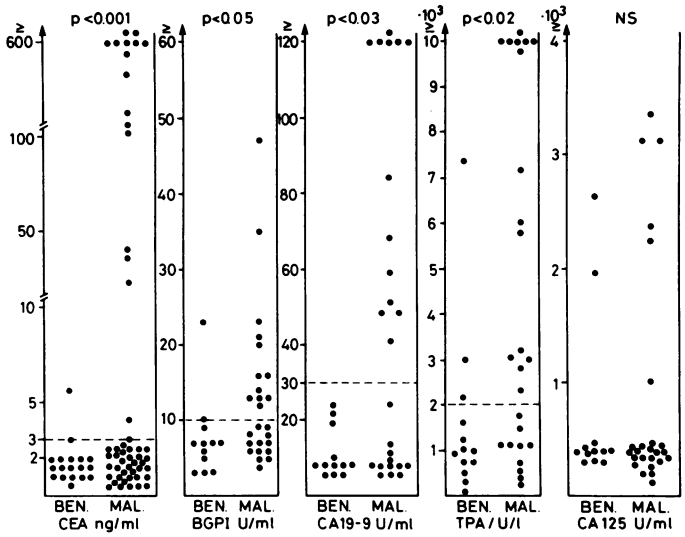

Fig 5 *Effusion fluid tumour marker concentrations in ascitic effusions. For CEA, 18 benign and 33 malignant cases; for BGP I, CA 19-9, TPA, and CA 125, 12 benign and 25 malignant cases.*

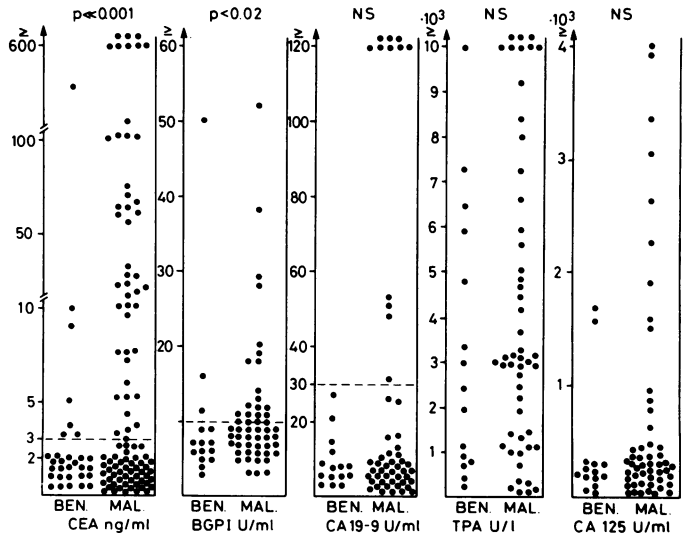

Fig 6 *Effusion fluid tumour marker concentrations in pleural effusions. For CEA, 30 benign and 96 malignant cases; for BGP I, CA 19-9, TPA, and CA 125, 15 benign and 51 malignant cases.*

pleuritis, sepsis, cirrhosis, congestive heart failure (3·6 to 9 ng/ml) and rupture of the oesophagus (390 ng/ml). BGP I was raised in bronchial adenoma (52 U/l), tuberculosis (11 U/l), congestive heart failure (16 U/l), and liver cirrhosis (23 U/l). In three drainage fluid specimens collected after laparotomy because of perforated duodenal and gastric ulcers or gall bladder, CEA concentrations of 18, 12, and 15 ng/ml, respectively, were obtained.

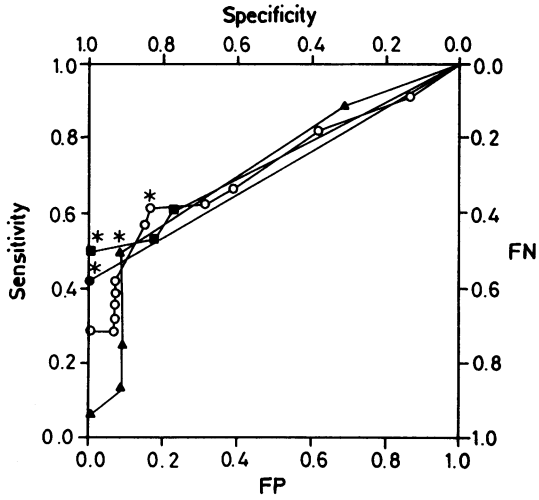

Fig 7 *ROC diagrams derived from data shown in fig 5 (ascitic effusions). ● = CEA, ▲ = BGP I, ■ = CA 19-9, ○ = TPA, * = cut off, FP = false positive, FN = false negative result.*

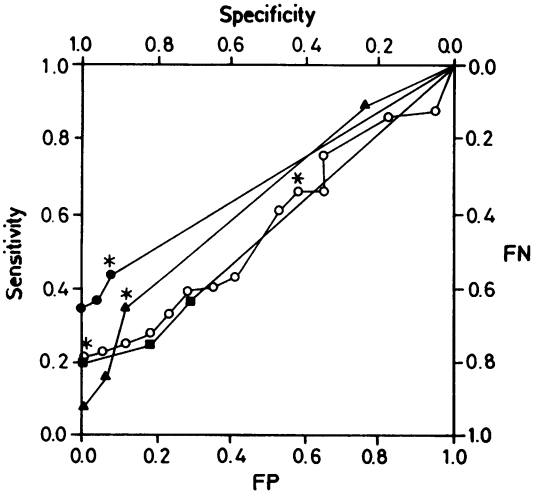

Fig 8 *ROC diagrams derived from data shown in fig 6 (pleural effusions). ● = CEA, ▲ = BGP I, ■ = CA 19-9, ○ = TPA, * = cut off, FP = false positive, FN = false negative result.*

CORRELATION OF IMMUNOCYTOCHEMICAL FINDINGS AND EFFUSION FLUID TUMOUR MARKER VALUES IN MALIGNANT CASES

For CEA, data from immunocytochemically stained slides and serous effusion fluid concentrations were available in 70 cases of malignancy. Values above the cut off limit were found in 13 of 15 immunocytochemically positive effusions. In 56 immunocytochemically negative serous effusions, diagnostically positive effusion fluid concentrations were found in 13 cases. The combined use of both methods improved the sensitivity in these cases from 21% and 37% to 40%. For BGP I, the corresponding values were: 12 immunocytochemically positive cases with six raised effusion fluid values and 19 immunocytochemically negative cases with eight raised effusion fluid values. This increased the detection rate from 39% and 45% to 65%. For CA 19-9 the corresponding values were: 11 immunocytochemically positive cases with eight positive effusion fluid values, 25 immunocytochemically negative cases with five diagnostically negative effusion fluid values. This improved the sensitivity from 31% (immunocytochemistry) and 36% (effusion fluid) to 44% (combined). There was a significant correlation between the immunocytochemical detection of tumour marker positive cells in serous effusions and effusion fluid values of the same marker indicative for malignancy (χ^2 test, $p < 0{\cdot}01$).

Table 3 *Percentage sensitivity, specificity, positive and negative predictive value of CEA, BGP I, TPA, and CA 19-9 compared with prevalence of malignant disease in 51 ascitic and 126 pleural effusions (CEA) and all markers in 37 ascitic and 66 pleural effusions*

					Predictive value:	
		Prevalence	*Sensitivity*	*Specificity*	*Positive*	*Negative*
CEA*	As	65	51	96	96	51
	Pl	76	48	78	87	32
BGP I†	As	68	48	92	92	46
	Pl	78	35	82	85	30
TPA‡	As	68	61	85	90	50
	Pl	78	67	41	74	30
CA 19-9§	As	68	52	100	100	50
	Pl	78	24	100	100	31
CEA + BGP I	As	68	64	92	95	61
	Pl	78	65	82	88	45
CEA + CA 19-9	As	68	56	100	100	52
	Pl	78	55	94	96	42
BGP I + CA 19-9	As	68	72	92	95	61
	Pl	78	47	82	88	35
	As	68	72	92	95	61
All markers	Pl	78	65	82	91	45

*3 ng/ml CEA, †10 U/ml BGP I, ‡2000 U/ml TPA, § 30 U/ml CA 19-9

Table 4 *Effusion fluid tumour marker concentrations indicative for malignancy*

	No (%) effusions tested for CEA > 3ng/ml	*No of effusions tested for all three markers*	*Percentage positive with CEA > 3 ng/ml*	*Percentage positive with BGPI > 10 U/ml*	*Percentage positive ith CA 19-9 > 30 U/ml*
Carcinomas	117 (50)	57	63	35	49
Breast	49 (57)	23	61	22	17
Ovary	12 (17)	4	25	50	25
Gastrointestinal	17 (82)	13	92	54	100
Non-small cell lung cancer	17 (76)	8	89	56	100
Small cell lung cancer	1 (100)	0			
Kidney	6 (0)	3	0	0	0
Various/unknown primary	5 (20)	5	20	20	50
Mesotheliomas	6 (17)	2	0	0	0
Lymphomas, leukaemias	18 (17)	10	10	50	50
Sarcomas	7 (17)	4	0	75	75
Teratomas	1 (0)	1	0	100	100
Melanoma	1 (100)	0			
Benign diseases	49 (6)	39	3	10	0

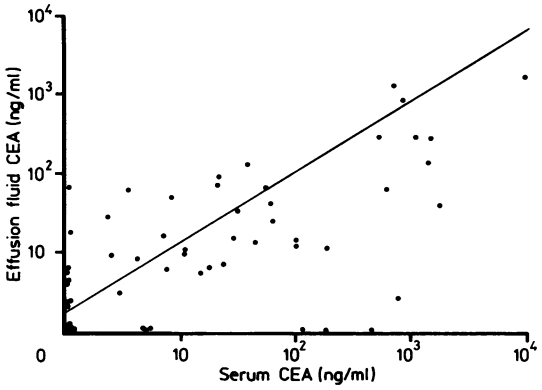

Fig 9 *Correlation of serous effusion fluid and serum CEA in 99 malignant cases. Regression line: serum CEA (ng/ml) = 0·171 × serous effusion fluid CEA + 16·4 (ng/ml).*

CORRELATION BETWEEN SEROUS EFFUSION FLUID AND SERUM CONCENTRATIONS OF CEA AND CA 125

In 40 of 49 benign cases serum CEA concentrations were below 3 ng/ml: the highest value was 7·3 ng/ml. Fig 9 charts the serum and serous effusion fluid CEA concentrations in 99 patients with malignant disease. In these patients the mean serum: serous effusion fluid CEA ratio was 13:1. In 11 malignant cases with positive immunocytochemical CEA staining the ratio was 46:5; in 46 malignant cases with negative immunocytochemical CEA staining the ratio was 11:9. There was a significant linear correlation between serum and serous effusion fluid CEA values ($r_s = 0{\cdot}77$, $p < 0{\cdot}01$). The regression line formula is:

$$\text{serum CEA (ng/ml)} = 0{\cdot}171 \times \text{effusion fluid CEA} + 16{\cdot}4 \text{ (ng/ml)}$$

CA 125 was determined simultaneously in sera and serous effusion fluid from 26 patients with benign and 44 patients with malignant disease. There was no significant difference between both groups either for serum or for effusion fluid values. Range and median serum CA 125 concentrations were 22–1837 U/l and 256 U/l in benign cases and 21–4323 U/l and 342 U/l in malignant cases. The corresponding effusion fluid values were 113–3410 U/l and 512 U/l in benign disease, and 99 to >40000 U/l and 812 U/l in malignant disease. There was a significant correlation of serum and effusion fluid CA 125 values in patients with benign as well as in those with malignant disease ($p < 0{\cdot}001$).

Discussion

In only about a third of the malignant serous effusions of our series were tumour cells detected by cytology alone, and this agrees with the findings of previous publications. There are three possible causes of the unsatisfactory sensitivity of conventional cytology. The effusion might be caused by a concomitant benign disease. In our series, however, in almost all malignant cases tumour was present in the pleura or the peritoneum at necropsy. Furthermore, in spite of disease in the serous membranes none or only a few tumour cells may have been released into the effusion fluid. The difficulty in identifying tumour cells arises from the polymorphism of proliferating mesothelial cells in benign as well as in malignant disorders of the pleura or the peritoneum. These proliferating mesothelial cells must not be confused with tumour cells, and a positive diagnosis must be made with caution.

Numerous simple laboratory tests have been assessed for their capacity to differentiate benign from malignant effusions, such as the content of lactic acid dehydrogenase,[12–15] glucose concentration,[12 18] protein concentration,[12 13 19] lactic acid content,[14 16 21] cell count,[16 17] pH values,[16 20] serum ascites ratio of

albumin,[22] and red cell count.[23] For some of these tests, the first optimistic reports were not confirmed in other studies. Other tests were applicable only in sterile effusions and gave false positive results in infected patients. The most promising examinations of this type are the determination of cholesterol[24] and fibronectin,[25 26] although both tests seem to be useful mainly in ascitic fluid and less so in pleural effusions.

Although until now none of the so-called tumour associated antigens could be shown to be specific for malignant disease, their determination seems to be a more direct approach to establishing the nature of the underlying disease. Numerous reports have documented the usefulness of determining CEA in serous effusion fluid as well as its immunocytochemical demonstration.

In our study the staining of granulocytes by antibodies to CEA and BGP I seems to have been caused by a cross reaction with non-specific cross reacting antigen (NCA).[27 28] It did not impair the value of these antibodies as granulocytes could easily be recognised by their morphology and could not be confused with tumour cells. Our data confirm that a positive reaction for CEA excludes a malignant mesothelioma or a non-neoplastic proliferation of serosa cells.[29–33] The diversity of the immunocytochemical staining for CEA in different tumour types is consistent with serological and immunohistochemical studies about the distribution of this antigen.[9 34–36]

TPA occurs closely related to the intermediate filaments of epithelial and carcinoma cells.[37 38] As in mesothelia the cytoskeleton proteins of epithelial and mesenchymal cells can be shown,[39] and it is not surprising that we also found TPA in mesothelia.

OC 125 recognises a determinant (CA125) which is associated with epithelial ovarian neoplasms.[40–42] As anti-CEA seldom stains ovarian carcinoma cells in serous effusions, OC 125 might fill a gap in effusion immunocytochemistry. Indeed, OC 125 reacted with tumour cells in almost all samples from ovarian carcinoma. On the other hand, our results confirm the findings of Kabawat, who reported that CA 125 also occurs in proliferating mesothelia.[43]

BGP I is antigenetically related to CEA and seems to occur mostly in normal gastrointestinal organs and gastrointestinal carcinomas.[10 44 45] The results of our immunocytochemical staining support the assumption that BGP I is a tumour associated antigen distributed differently from CEA. Like CEA, it occurs in carcinomas of the gastrointestinal tract and the lung, but unlike CEA it was found in breast carcinomas only rarely. Additionally, staining of ovarian carcinoma cells, though weak, was observed.

Like BGP I, CA 19-9 occurs mostly in benign and malignant gastrointestinal tissues.[35 46 47] In our study both immunocytochemically positive specimens as well as raised serous effusion fluid values were found mostly in gastrointestinal and ovarian carcinomas and only in a few breast carcinomas and non-small cell lung cancer.

The misdiagnosis of a neoplasm in patients with a benign disease could lead to very far reaching sequelae. Normally occurring antigens in serous membranes or in benign diseases are therefore not suitable for diagnostic tests. TPA and CA 125, therefore, do not seem to be suitable for the immunocytochemical diagnosis of tumours in serous effusions. CA 1[48] and epithelial membrane antigen[5 49] have been described as occurring only in malignant effusions. Other investigators, however, detected the antigens in mesothelia in benign specimens as well.[30 33 50] Antisera to keratin,[33] α fetoprotein,[32] pregnancy specific β 1-glycoprotein[32] and placental alkaline phosphatase[32] were found to stain only carcinoma cells, but provided little additional information when compared with CEA. The distribution of different molecular weight keratins showed that mesothelial and adenocarcinoma cells had a different staining pattern.[51] The monoclonal antibody B 72·3 was developed by immunising mice with a membrane enriched fraction of a human carcinoma. Ninetyfive per cent staining of adenocarcinoma cells in serous effusions and the absence of mesothelial cell staining has recently been reported for this antibody.[52] To our knowledge, the remarkable sensitivity of this monoclonal antibody has so far not been confirmed by other investigators. Furthermore, the monoclonal antibodies AUA1,[49] Ca 2, and Ca 3[53] have been described as specific for malignant cells in serous effusions.

In our study the occurrence of cells positive for CEA, CA 19-9, or BGP I was specific for the presence of a carcinoma. Not all positive cells, however, seem to be carcinoma cells. Obviously, material derived from a tumour and phagocytosed by mesothelia had been stained in some cases. The morphology of the cells in immunocytochemically stained slides and the fact that positive cells were found mostly in effusions diagnosed as positive by conventional cytology, indicate that positively stained cells in most cases were carcinoma cells. Positively stained cells, however, were also found in 26% of serous effusions from patients with malignant disease which had been diagnosed cytologically as "negative" or "suspicious". Therefore, immunocytochemical staining for these antigens seems to be helpful in diagnosis, although even with anti-CEA, the most sensitive of the three antibodies, tumour cells could be detected in only 24% of carcinoma cases. Nevertheless, compared with conventional cytology alone, the additional use of immunocytochemistry raised the sensitivity of the detection of a carcinoma from 32% to 63%. In effusions selected for the presence of tumour cells, a staining of adenocarcin-

oma cells by anti-CEA has been reported in 44% to 80% of cases.[30-33] Using antibodies to Ca 1 and HMFG-2 in addition to anti-CEA, Ghosh *et al* identified carcinoma cells in 15 of 53 cytologically negative effusions.[1] These figures cannot be directly compared with our results, as in our study a consecutive, unselected series was examined. Like CEA, BGP I and CA 19-9 are restricted to certain types of carcinomas. Therefore the antigenic pattern of the tumour cells might give valuable information about the site of the primary lesion. Thus in spite of the considerable effort necessary for this technique, immunocytochemical staining for all three antigens should be considered as part of the diagnostic procedure in cases with serous effusions of unknown origin.

Effusion fluid tumour markers can be determined by techniques used for the examination of serum and should be available more readily than immunocytochemical techniques. On the other hand, this method does not directly identify malignant cells and is thus more likely to give false positive results.

Stanford *et al* failed to show a significant difference between CEA concentrations in pleural effusions in patients with mesothelioma, inflammatory lung disease, and bronchial carcinoma.[54] In 15 reports on the determination of CEA in serous effusion fluid summarised by Faravelli in 1984,[2] and in other studies,[3 4 55-60] cut off values between 2·5 and 40 ng/ml were recommended for the discrimination of benign and malignant effusions, resulting in a specificity for malignancy of between 85% and 100% and a sensitivity of between 27% and 88%. This diversity seems to reflect both the different ranges of normal values for the tests applied as well as a different selection of patients. Furthermore, it emphasises that cut off values established for normal serum specimens cannot be applied to those of serous effusions without further investigation.

Our data confirm that high CEA values in serous effusion fluid in patients with benign disease are found more commonly in inflammatory disease.[54 60] Interestingly, high CEA concentrations also occurred in drainage and effusion fluid specimens from patients with perforations of gastrointestinal organs. CEA occurs in high concentrations in gastrointestinal mucus.[61]

In agreement with Braun *et al*,[62] we found a significant linear correlation between serum and serous effusion fluid CEA concentrations. In a considerable number of patients, however, a serous effusion fluid CEA value indicative of malignancy was combined with a normal serum CEA concentration and thus was able to provide diagnostically useful additional information. The mean value of serous effusion fluid: serum CEA ratios of 13:1 found in this study in patients with various malignant diseases was similar to those reported by Nystrom *et al*[63] and Asseo *et al*.[57] In agreement with observations by Di Stefano *et al*,[64] in patients with breast cancer the ratio was significantly lower. A high serous effusion fluid: serum tumour marker ratio could be indicative for a tumour mass in the pleural or peritoneal cavity, and a low ratio could indicate effusions caused only indirectly by the tumour. This assumption was supported by most of our results, as in effusions with a positive immunocytochemical CEA staining (indicative for neoplastic disease in the serous membranes) a much higher serous effusion fluid : serum CEA ratio was found than in immunocytochemically negative cases. In a few effusions containing tumour marker positive cells, however, low serous effusion fluid and serum tumour marker concentrations were found. This might be explained by reduced or absent secretion of these antigens by the tumour.

The formation of the antigens by mesothelial cells seems to explain the prevalence of high concentrations of CA 125 and TPA in serous effusion fluid. The close statistical correlation between CA 125 in serous effusion fluid and serum concentrations and the surprisingly high incidence of raised CA 125 serum concentrations in benign disorders affecting the serous membranes (also observed by Ianucci; abstract presented at International Symposium on Monoclonal Antibodies, Florence, Italy, 1984) and Bergmann *et al*[67] seem to indicate that in some cases the production of the antigen in mesothelium might be the cause of raised serum concentrations.

High CA 125 concentrations in effusion fluid can also occur in benign disease and are therefore not a recommendation for the diagnostic use of this test. To obtain sufficient specificity our cut off value for TPA (2000 U/l) in serous effusion fluid had to be set much higher than the discriminatory limit recommended for serum TPA (80–120 U/l).[66 67] This resulted in comparatively low sensitivity and positive predictive values. For similar reasons, BGP I concentrations in pleural effusions seem to be less helpful in diagnosis.

In contrast, determination of CA 19-9 in ascitic and in pleural effusions and that of BGP I in ascitic effusions are specific and sensitive enough to become valuable tools in diagnosis, although these tests are similar to determination of CEA in serous effusion fluid and are positive in only about ⅓ to ½ of malignant cases. As the single antigens exhibited raised concentrations in different patient groups (depending partly on the site of the primary lesion), the combination of two or three markers increased the sensitivity considerably. For some combinations, however, the specificity was too low for clinical use.

In agreement with the reports of Martinez-Vea *et al*[58] we found raised AFP concentrations in effusion

fluid only rarely. This reflects the narrow range of tumours which usually express this antigen. Couch[3] found that human β chorionic gonadotrophin gave a specificity for malignancy of 96% and a sensitivity of 36% at a cut off of 10 mIU/ml. High concentrations of α 1-acidylglycoprotein in serous effusion fluid are not specific for malignancy, but in a series of 50 patients values below 39 ng/ml were found only in benign disease.[58]

Until now tumour markers have not discriminated between benign and malignant aetiologies in serous effusions with satisfying sensitivity. On careful examination of benign specimens, however, cut off values can be derived for some antigens which are useful in identifying a tumour, especially an adenocarcinoma as the cause of the effusion. To date, the best antigen is CEA. As shown by our study, both the immunocytochemical staining for CA 19-9 and BGP I as well as the determination of the concentrations of these antigens in serous effusion fluid provide valuable additional information about the cause of pleural and peritoneal effusions. Depending on the circumstances, we recommend a combination of these methods to increase diagnostic accuracy.

We thank Ms M Darsow, G Wochinger, A Brandt and E Segura for excellent technical assistance. Drs W Klaubert, KE Häussinger, and F Cujnik generously provided effusion and serum specimens.

References

1 Ghosh AK, Mason DY, Spriggs AI. Immunocytochemical staining with monoclonal antibodies in cytologically "negative" serous effusions from patients with malignant disease. *J Clin Pathol* 1983;**36**:1150–3.
2 Faravelli B, D'Amore E, Nosenzo M, Betta PG, Donna A. Carcinoembryonic antigen in pleural effusions. *Cancer* 1984;**53**:1194–7.
3 Couch WD. Combined effusion fluid tumor marker assay, carcinoembryonic antigen (CEA) and human chorionic gonadotrophin (hCG), in the detection of malignant tumors. *Cancer* 1981;**48**:2475–9.
4 Booth SN, Lakin G, Dykes PW, Burnett D, Bradwell AR. Cancer-associated proteins in effusion fluids. *J Clin Pathol* 1977;**30**: 537–40.
5 To A, Coleman DV, Dearnaley DP, Ormerod MG, Steele K, Neville AM. Use of antisera to epithelial membrane antigen for the cytodiagnosis of malignancy in serous effusions. *J Clin Pathol* 1981;**34**:1326–32.
6 Rittgers RA, Loewenstein MS, Feinermann AE, *et al.* Carcinoembryonic antigen levels in benign and malignant pleural effusions. *Ann Intern Med* 1978;**88**:631–4.
7 Mezger J, Holzmann B, Arnholdt H, Riethmüller D, Huhn D. Markierung epithelialer Tumorzellen in zytologischen Präparaten mit monoklonalen Antikmörpern unter Verwendung einer verstärkten indirekten Immunperoxidasemethode. In: Urbanitz D, Haubeck HD, eds. *Aktuelle Aspekte zur Tumorimmunologie*. Berlin: Springer, 1985;65–73.
8 Mezger J, Endo K, Walter S, Wilkes J, Wilmanns W. A pitfall in immunocytochemistry—non specific staining of plasmacytoid cells with indirect immunocytochemical techniques. *J Tumor Marker Oncol* 1988;**3**: (in press).
9 Lamerz R, Ruider H. Bestimmungen von karzinoembryonalem Antigen bei Patienten mit Dickdarmtumoren. *Münch Med Wochenschr* 1976;**118**:371–6.
10 Lamerz R, Stieber P. Radioimmunological detection of biliary glycoprotein-like antigen (BGP I) in sera of healthy subjects and patients with benign and malignant gastrointestinal diseases. *Tumor Biology* 1986;**6**:326.
11 Sachs L. *Applied statistics*. New York: Springer, 1982.
12 Wördehoff D. Diagnostischer Wert laborchemischer Aszites-untersuchungen. *Leber Magen Darm* 1981;**11**:25–30.
13 Rovelstad RA, Bartholomew LG, Cain JC. Ascites IV. Clinical appraisal of the laboratory studies of ascitic fluid and blood as an aid to diagnosis. *Gastroenterology* 1959;**37**:339–45.
14 Bitelman B, Borges de Lima Rafin DB, DeSilva MD, Polak M, Bettarello A. Diagnostic value of lactic acid dehydrogenase activity determination in ascitic fluid. *Am J Gastroenterol* 1981;**76**:172.
15 Boyer TD, Kahn AM, Reynolds TB. Diagnostic value of ascitic fluid lactic dehydrogenase, protein and WBC levels. *Arch Intern Med* 1978;**138**:1103–5.
16 Bar-Meir S, Lerner E, Conn HO. Analysis of ascitic fluid in cirrhosis. *Am J Dig Dis* 1979;**24**:136–44.
17 Wilson JAP, Suguitan EA, Cassidy WA. Characteristics of ascitic fluid in the alcoholic cirrhotic. *Dig Dis Sci* 1979;**24**:645–8.
18 Polak M, Torres da Costa AC. Diagnostic value of the estimation of glucose in ascitic fluid. *Digestion* 1973;**8**:347–52.
19 Sampliner RE, Iber FL. High protein ascites in patients with uncomplicated hepatic cirrhosis. *Am J Med Sci* 1974. **267**:275–9.
20 Gitlin N, Stauffer JL, Silvestri RC. The pH of ascitic fluid in the diagnosis of spontaneous bacterial peritonitis in alcoholic cirrhosis. *Hepatology* 1982;**2**:408–11.
21 Brook I, Altman RS, Loebman WW, Seeff LB. Measurement of lactate in ascitic fluid. An aid in the diagnosis of peritonitis with particular relevance to spontaneous bacterial peritonitis of the cirrhotic. *Dig Dis Sci* 1981;**26**:1089–94.
22 Pare P, Talbot J, Hoefs JC. Serum-ascites albumin concentration gradient: A physiological approach to the differential diagnosis of ascites. *Gastroenterology* 1983;**85**:240–4.
23 DeSitter L, Rector WG. The significance of bloody ascites in patients with cirrhosis. *Am J Gastroenterol* 1984;**79**:136–8.
24 Jüngst D, Gerbes AL, Martin R, Paumgartner G. Value of ascitic lipids in the differentiation between cirrhotic and malignant ascites. *Hepatology* 1986;**6**:239–43.
25 Hafter R, Klaubert W, Gollwitzer R, von Hugo R, Graeff H. Crosslinked fibrin derivatives and fibronectin in ascitic fluid from patients with ovarian cancer compared to ascitic fluid in liver cirrhosis. *Thrombosis Res* 1984;**35**:53–64.
26 Schölmerich J, Volk BA, Köttgen E, Ehlers S, Gerok W. Fibronectin concentration in ascites differentiates between malignant and nonmalignant ascites. *Gastroenterology* 1984;**87**:1160–4.
27 Bordes M, Knobel S, Martin F. Carcinoembryonic antigen (CEA) and related antigens in blood cells and hematopoietic tissue. *Eur J Cancer* 1975;**11**:783–6.
28 Pattengale PK, Taylor CR, Engvall E, Ruoslahti E. Direct visualization of normal cross reacting antigen (NCA) in normal and neoplastic granulocytes. *Lab Invest* 1979;**40**:277.
29 Permanetter W, Wiesinger H. Immunohistochemical studies in effusion sediments of lysozyme, alpha-l-antitrypsin, tissue polypeptide antigen (TPA), keratin and carcinoembryonic antigen (CEA). *Acta Cytol* 1987;**31**:104–12.
30 O'Brien MJ, Kirkham SE, Burke B, *et al.* CEA, ZGM and EMA localization in cells of pleural and peritoneal effusion: A preliminary study. *Invest Cell Pathol* 1980;**3**:251–8.
31 Walts AE, Said JW. Specific tumor markers in diagnostic cytology. *Acta Cytol* 1983;**27**:408–16.
32 Orell SR, Dowling KD. Oncofetal antigens as tumor markers in the cytologic diagnosis of effusions. *Acta Cytol* 1983;**27**:625–9.
33 Ghosh AK, Spriggs AI, Taylor-Papadimitriou J, Mason DY. Immunocytochemical staining of cells in pleural and peritoneal effusions with a panel of monoclonal antibodies. *J Clin Pathol* 1983;**36**:1154–64.

34 Goldenberg DM, Sharkey RM, Primus FJ. Immunocytochemical detection of carcinoembryonic antigen in conventional histopathology specimens. *Cancer* 1978;**42**:1546–53.
35 Charpin C, Bhan AK, Zurawski VR, Scully RE. Carcinoembryonic antigen (CEA) and carbohydrate determinant 19-9 (CA 19-9) localization in 121 primary and metastatic ovarian tumors: an immunohistochemical study with the use of monoclonal antibodies. *Int J Gynecol Pathol* 1982;**1**:231–45.
36 Wang NS, Huang SN, Gold P. Absence of carcinoembryonic antigen-like material in mesothelioma. *Cancer* 1979;**44**:937–43.
37 Nathrath WBJ, Heidenkummer P, Arnholdt H, *et al.* Distribution of tissue polypeptide antigen in normal and neoplastic tissues. In: Peeters H, ed. *Protides and biological fluids.* Oxford: Pergamon Press, 1984:437–40.
38 Björklund B. Overview of TPA: specificity, immunocytochemistry and biological basis. In: Peeters H, *ed. Protides and biological fluids.* Oxford: Pergamon Press, 1984:425–30.
39 LaRocca PJ, Rheinwald JG. Coexpression of simple epithelial keratins and vimentin by human mesothelium and mesothelioma in vivo and in culture. *Cancer Res* 1984;**44**:2991–9.
40 Bast RC, Feeney M, Lazarus H, Nadler LM, Colvin RB, Knapp RC. Reactivity of a monoclonal antibody with human ovarian carcinoma. *J Clin Invest* 1981;**68**:1331–7.
41 Kabawat SE, Bast RC, Welch WR, Knapp RC, Colvin RB. Immunopathologic characterization of a monoclonal antibody that recognizes common surface antigens of human ovarian tumors of serous, endometrioid, and clear cell types. *Am J Clin Pathol* 1983;**79**:98–104.
42 Bast RC, Klug TL, St John E *et al.* A radioimmunoassay using a monoclonal antibody to monitor the course of epithelial ovarian cancer. *N Engl J Med* 1983;**309**:883–7.
43 Kabawat SE, Bast RC, Bhan AK, Welch WR, Knapp RC, Colvin RB. Tissue distribution of a coelomic epithelium-related antigen recognized by the monoclonal antibody OC125. *Int J Gynecol Pathol* 1983;**2**:275–85.
44 Svenberg T. Carcinoembryonic antigen-like substances of human bile. Isolation and partial characterization. *Int J Cancer* 1976;**17**:588–96.
45 Lamerz R, Reischle Ch, Stieber P, Wiebecke B. Occurrence of biliary glycoprotein-like antigen (BGP I) in normal and adult, inflammatory and cancerous tissues. *Tumor Biology* 1986;**6**:326.
46 DelVillano BC, Brennan S, Brock P, Bucher C, Liu V. Radioimmunometric assay for a monoclonal antibody-defined tumor marker, CA 19-9. *Clin Chem* 1983;**29**:549–52.
47 Dietal M, Arps H, Klapdor R. Morphologisch-klinische Korrelation der Tumormarker CA 19-9, CA 125 und CEA bei Pankreaskarzinomen. In: Greten H, Klapdor R, eds. *Neue tumorassoziierte Antigene.* Stuttgart: Thieme, 1985;78–85.
48 Woods JC, Harris H, Spriggs AI, McGee JOD. A new marker for human cancer cells. 3. Immunocytochemical detection of malignant cells in serous fluids with the Cal antibody. *Lancet* 1982;ii:512–4.
49 Epenetos AA, Canti G, Taylor-Papadimitriou J, Curling M, Bodmer WF. Use of two epithelium-specific monoclonal antibodies for diagnosis of malignancy in serous effusions. *Lancet* 1982;ii:1004–6.
50 Pallesen G, Jepsen FL, Hastrup J, Ipsen A, Hvidberg N. Experience with the Oxford tumour marker (Cal) in serous fluids. *Lancet* 1983;i:1326.
51 Walts AE, Said JW, Shintaku IP, Sassoon AF, Banks-Schlegel S. Keratin of different molecular weight in exfoliated mesothelial and adenocarcinoma cells—an aid to cell identification. *Am J Clin Pathol* 1984;**81**:442–6.
52 Johnston WW, Szpak CA, Lottich SC, Thor A, Schlom J. Use of a monoclonal antibody (B72·3) as an immunocytochemical adjunct to diagnosis of adenocarcinoma in human effusions. *Cancer Res* 1985;**45**:1894–900.
53 Bramwell ME, Ghosh AK, Smith WD, Wiseman G, Spriggs AI, Harris H. Ca 2 and Ca 3. New monoclonal antibodies evaluated as tumor markers in serous effusions. *Cancer* 1985;**56**:105–10.
54 Stanford CF, Neville AM, Laurence DJR. Concurrent assays of plasma and pleural-effusion levels of carcinoembryonic antigen in the diagnosis of pulmonary disease. *Lancet* 1978;ii:53.
55 Whiteside TL, Dekker A. Diagnostic significance of carcinoembryonic antigen levels in serous effusions. *Acta Cytol* 1979;**23**:443–8.
56 Lirzin P, Zeitoun P, Vandromme L, Salas H. Antigene carcinoembryonnaire dans les ascites et les epanchements pleuraux. *Gastroenterol Clin Biol* 1984;**8**:222–7.
57 Asseo PP, Tracopoulos GD. Simultaneous enzyme immunoassay of carcinoembryonic antigen in pleural effusion and serum. *Am J Clin Pathol* 1982;**77**:66–71.
58 Martinez-Vea A, Gatell JM, Segura F, *et al.* Diagnostic value of tumoral markers in serous effusions. *Cancer* 1982;**50**:1783–8.
59 Heyenga H, Morr H. Diagnostischer Stellenwert des carcinoembryonalen Antigens im Pleurapunktat. *Dtsch Med Wochenschr* 1982;**107**:818–21.
60 Loewenstein MS, Rittgers RA, Feinerman AE, *et al.* Carcinoembryonic antigen assay of ascites and detection of malignancy. *Ann Intern Med* 1978;**88**:635–8.
61 Go VLW, Ammon HV, Holtermuller KH, Krag E, Phillips SF. Quantification of carcinoembryonic antigen-like activities in normal human gastrointestinal secretions. *Cancer* 1975;**36**: 2346–50.
62 Braun HV, Dutter LE, Zaeske M. Statistical significance of carcinoembryonic antigen in plasma and pleural fluid. *Surgery* 1982;**92**:561–2.
63 Nystrom S, Dyce B, Wada J, Bateman JR, Haverback B. Carcinoembryonic antigen titers on effusion fluid. *Arch Intern Med* 1977;**137**:875–9.
64 Di Stefano A, Tashima CK, Fritsche HA, Geitner A, Cailleau R, Blumenschein GR. Carcinoembryonic antigen levels in malignant pleural fluids obtained from patients with mammary cancer. *Am J Clin Pathol* 1980;**73**:386–90.
65 Panucci A, Fabris C, Delfavero G, *et al.* Tissue polypeptide antigen (TPA) in pancreatic cancer diagnosis. *Br J Cancer* 1985;**52**:801.
66 Kew MC, Berger EL. The value of serum concentrations of tissue polypeptide antigen in the diagnosis of hepatocellular carcinoma. *Cancer* 1986;**58**:127–30.
67 Bergman JF, Bidart JM, George M, Beaugrand M, Levy VG, Bohuon C. Elevation of CA 125 in patients with benign and malignant ascites. *Cancer* 1987;**59**:213–7.

Requests for reprints to: Dr J Mezger, Mediazinische Klinik III, Klinikum Grosshadern, 8 München 70, West Germany.