present, it is virtually pathognomonic of pericardial tamponade. Alternation of only the QRS complex (Figure 3) is highly suggestive of tamponade when persistent and when seen in the appropriate clinical setting. Electrical alternans is thought to be the result of the rotational and pendular motion of the heart suspended in a fluid filled sac.[6]

Constrictive Pericarditis

Constrictive pericarditis is similar to pericardial effusion in that the major hemodynamic deficit results from a restriction of ventricular filling.[4] Unlike pericardial effusion, however, it is due to the presence of a fixed rigid encasement around the ventricles. Early in diastole the ventricular pressure is low and there is a prominent atrioventricular gradient permitting a rapid inflow of blood from the atria. The rigid encasement of the ventricles, however, prevents ventricular expansion so that ventricular pressure soon abruptly rises and reaches a plateau during the remainder of diastole (Figure 4). At this point the pressure in all four cardiac chambers is equal.

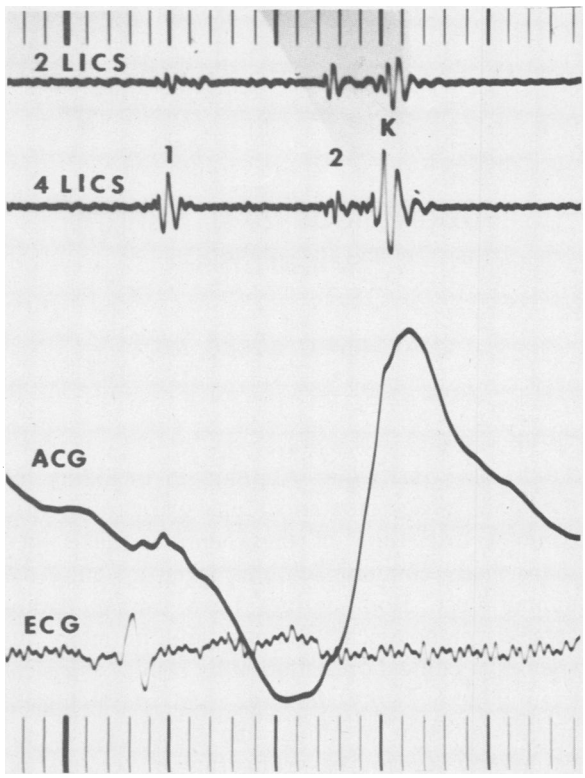

Figure 6.—Apexcardiogram (ACG) in chronic constrictive pericarditis. From top, phonocardiogram recorded in second left intercostal space (2 LICS) and in fourth left intercostal space (4 LICS), apexcardiogram and electrocardiogram. Note the systolic apical retraction and early diastolic bulge in the ACG. The latter coincides with the pericardial knock.

On physical examination the jugular venous pressure is elevated and a prominent X descent similar to that seen in effusion may be noted. However, the most striking feature of the venous pulse is the presence of a rapid diastolic collapse, the so-called Y descent (Figure 5). This corresponds to the period of rapid diastolic filling very early in diastole. On auscultation an early diastolic sound similar in timing to the ventricular gallop sound (S3) may be noted. This is referred to as a pericardial knock and occurs as ventricular diastolic pressure is rapidly rising (Figures 4 through 6). On palpation of the precordium a systolic apical retraction and early diastolic expansion may be appreciated (Figure 6). The early diastolic wave occurs coincident with the pericardial knock and with the rapid rise of ventricular diastolic pressure. Pulsus paradoxus may be seen in constrictive pericarditis, but is noted only in approximately a third of cases. In long-standing pericardial constriction chronic atrial fibrillation is commonly present. On x-ray films of the chest the heart is frequently normal in size but may be small or somewhat enlarged. The presence of pericardial calcification is an important diagnostic finding.

Viral Pericarditis

MILAN FIALA, MD*

VIRAL PERICARDITIS is frequently associated with myocarditis and the term myopericarditis is used to encompass both.[9] Clinical and experimental evidence of viral endocarditis has been presented.[10,11] It has been also suggested that viral or mixed streptococcal and viral valvulitis may lead to chronic valvular damage.[12] Viral pericarditis may be followed by chronic constrictive pericarditis.[13,14]

Viruses which have been associated, by virus isolation or antibody response or both, with heart disease in man include Coxsackie group B (types 1 to 5) and less often group A (types 4 and 16)

*Assistant Professor of Medicine, UCLA School of Medicine, Division of Infectious Diseases, Harbor General Hospital.

viruses, (enteric cytopathogenic human orphan (ECHO) viruses (types 9 and 22), influenza A and B, mumps, measles, rubella, variola, vaccinia, hepatitis, adenoviruses, Epstein-Barr virus, cytomegalovirus and varicella-zoster virus.[9,15]

Heart disease has been experimentally reproduced in mice with Coxsackie virus A-9 and B3 viruses,[16] and in adult monkeys, with Coxsackie B-4 virus which produced pancarditis, resembling rheumatic heart disease with valvulitis and myocarditis.[11,17] In adult mice, Coxsackie A-9 virus produced benign heart disease. In young mice, Coxsackie B3 virus caused virulent myocarditis with progressive myocardial injury. The severity of experimental virus infections was increased by factors such as exercise, hydrocortisone, undernutrition, alcohol, pregnancy and virulence of the infecting virus.[16]

Viral involvement of the heart may lead to a wide spectrum of clinical illness:[18,19]

- Symptoms of acute pericarditis.
- Chest pain mimicking myocardial infarction.
- Progressive congestive heart failure.
- A nonspecific influenza-like illness with fever, headache, muscle or joint pains and headache.

Relapses may occur, especially in patients presenting initially with symptoms of acute pericarditis. A history of antecedent viral syndrome with fever, headache, muscle pain, pleural effusion or pneumonitis, and absence of recent angina pectoris help to differentiate myopericarditis from coronary heart disease.

Coxsackie B viruses[18,19] have been recognized as the most common viral agents in pericarditis, either by demonstration of antibody rise or by isolation of virus from stool, throat or pericardial fluid. Other viruses have been incriminated usually only serologically. Other known infectious agents and other causes such as chest trauma; toxins; neoplasia; collagen vascular, hormonal and metabolic diseases need to be excluded by appropriate studies. In most cases, a specific cause cannot be, however, identified. In order to understand the cause of idiopathic cases of myopericarditis, it is helpful to remember that in experimental disease in mice, infectious virus is commonly present in excretions and heart tissue only during the incubation period and in the acute stage of the disease.[20] The presence of antibodies to the heart muscle and virus antigen in the heart may be the only remaining trace of virus activity in chronic noninfectious phase.

High prevalence of elevated neutralizing antibodies to Coxsackie group B viruses[21] decreases their diagnostic value. Demonstration of immunoglobulin M (IgM) type-specific antibodies to Coxsackie B viruses may help to establish an etiological diagnosis in those cases of myopericarditis where the usual diagnostic techniques fail.[22]

Patients with viral myopericarditis should be treated with complete bedrest. Mice infected with Coxsackie B viruses which were forced to swim for their life invariably died with enlarged hearts, whereas the heart size remained normal if they were allowed to rest.[23] The use of corticosteroids is controversial. In animal studies, corticosteroids administered during the acute phase of Coxsackie virus infection enhanced virus titers and lesions.[24] In the experience of some clinicians, however, steroids appear to be life-saving in later stages of the disease if the patient is developing heart failure in spite of full bedrest and digitalization.[25]

Tuberculous and Fungal Pericarditis

MATTHEW O. LOCKS, MD*

THERE IS CONSIDERABLE MERIT in including tuberculous pericarditis and fungal pericarditis in a conjoint discussion of these entities since they share many common features when affecting the human host. Both entities have similar pathogenesis, pathological findings, and in many instances, a clinical presentation by history, physical examination, x-ray findings and physiological alterations, that precludes the separation of tuberculous pericarditis from fungal pericarditis. Moreover, both categories of disease are usually accompanied by the development of cutaneous hypersensitivity to the specific infectious agent. Furthermore, the management of tuberculous

*Director, Chest Ward Service, Harbor General Hospital.