Clinical Medicine

Surgical Management of Traumatic Disruption of the Descending Aorta

J. NILAS YOUNG, MD; ROBERT J. STALLONE, MD; LEIGH I. G. IVERSON, MD; COYNESS L. ENNIX, Jr, MD; ROGER R. ECKER, MD; *and* IVAN A. MAY, MD, *Oakland, California*

During an 11½-year period, 20 consecutive patients presenting with a traumatic disruption of the proximal descending aorta underwent an emergency operative repair. The mean age was 26 years (range 15 to 62), and 13 (65%) were male. Associated injuries were frequent and required additional major operative procedures in half of the cases. Two patients died as a result of associated intracranial injuries, for a hospital survival of 90%. The operative repair was accomplished by graft replacement of the involved segment of the aorta in all but one patient who underwent a primary repair. Simple aortic crossclamping was used in 8 patients (40%) and heparinless femoral-femoral venoarterial bypass in 12 patients (60%). Neither renal failure nor paraplegia developed in any of the patients. Four patients required thoracic reoperations. These results indicate that an aggressive multidisciplinary surgical approach can produce favorable results in patients with traumatic descending aortic injuries.

(Young JN, Stallone RJ, Iverson LIG, et al: Surgical management of traumatic disruption of the descending aorta. West J Med 1989 Jun; 150:662-664)

Traumatic disruption of the descending thoracic aorta due to blunt chest trauma continues to be a challenging surgical problem. It has been our policy to surgically repair these lesions as soon as the diagnosis has been established and associated injuries assessed and addressed. In this report, we review the results of this approach.

Patients and Methods

Between January 1975 and July 1986, emergency surgical repair was carried out on 20 consecutive patients presenting with a traumatic disruption of the proximal descending aorta. All patients were referred from other institutions following an initial evaluation. The mean age was 26 years (range, 15 to 62), and 13 were male. The time from injury to aortic operation averaged 18 hours (range, 2 to 96). Of the 20 patients, 17 (85%) had associated injuries, and 11 (55%) had multiple associated injuries. Ten of the patients required additional major operative procedures for these associated injuries (Table 1). The most commonly required additional major operation was splenectomy (3 patients; 15%), followed by orthopedic and neurosurgical interventions.

Operative repairs were accomplished by replacing the involved segment of the aorta with an interpositional Dacron graft. Limited resection of the disrupted aorta was done to preserve all intercostal vessels in the distal segment. We used 3-0 polypropylene sutures placed in a running fashion. The proximal aortic crossclamp was placed between the left subclavian and left carotid arteries, and the distal aortic clamp was placed as close as possible to the tear while allowing an adequate tissue cuff for the distal anastomosis. One patient underwent a primary aortic repair. This was accomplished by simple reapproximation of the limited area of aortic disruption.

Two different approaches were used for distal aortic perfusion. Heparinless femoral-femoral venoarterial bypass (HFVAB) was used in 12 patients (60%). The specific elements of this technique have been previously described.[1-4] Briefly, a long (26F) polyvinyl-polymethane bonded catheter is inserted through the femoral vein into the right atrium to collect mixed venous blood, which is then returned to the left femoral artery by way of a roller pump, thus perfusing the abdominal viscera and distal thoracic aorta (Figure 1). Perfusion rates range from 1,500 to 2,000 ml per minute and may be adjusted to control the cardiac preload. An inspired oxygen concentration of 100% during the aortic crossclamping helps increase the oxygen content of the perfused mixed venous blood. The average crossclamp time in this group of patients was 46 minutes (range, 34 to 98).

Simple aortic crossclamping was used in eight patients (40%). Proximal hypertension in this group and in the group with HFVAB could be managed by the intravenous administration of sodium nitroprusside or trimethaphan camsylate. A mean proximal arterial pressure is maintained in the range of 60 to 90 mm of mercury. The average crossclamp time in this group was 23 minutes (range, 12 to 32). The decision to use simple crossclamping versus HFVAB was made by the operating surgeon.

Results

All but 2 of the 20 patients (90%) survived. The two hospital deaths occurred within 72 hours of the aortic repair and were due to associated massive intracranial injuries. Both patients had obvious critical neurologic injury and un-

From the Department of Cardiac and Thoracic Surgery, Samuel Merritt Hospital, Oakland, California.
Reprint requests to J. Nilas Young, MD, 3300 Webster St, Suite 304, Oakland, CA 94609.

derwent a craniotomy before the aortic repair. They were declared brain dead following the aortic operation, and life support was electively terminated. Neither renal failure nor paraplegia developed in any of the survivors. Paraparesis developed in one patient in the HFVAB group five days postoperatively, which ultimately cleared.

Four patients required a thoracic reoperation, one for early surgical bleeding, one for chylothorax, one for an expanding pseudoaneurysm at the distal anastomotic suture line, and one had an aortic obstruction at the proximal anastomotic site.

The chylothorax was managed by ligating the thoracic duct at the supradiaphragmatic level through a right thoracotomy. The pseudoaneurysm was repaired by direct suture. The obstructive lesion appeared to have resulted from a compressive hematoma at the level of the proximal anastomosis (distal aortic arch). The clinical findings in this patient were those of upper body hypertension and diminished femoral pulses. A second postoperative aortogram revealed the presence of obstruction at the proximal anastomotic site. At the second operation, a tubular Dacron graft was placed between the ascending aorta and the proximal descending thoracic aorta, thus bypassing the obstruction. The patient had no postoperative difficulty and is now normotensive with equal upper and lower extremity pulses.

Comments

Our results indicate that an aggressive surgical approach can be associated with favorable results in patients with dissecting aortic injuries. Earlier series reported renal failure

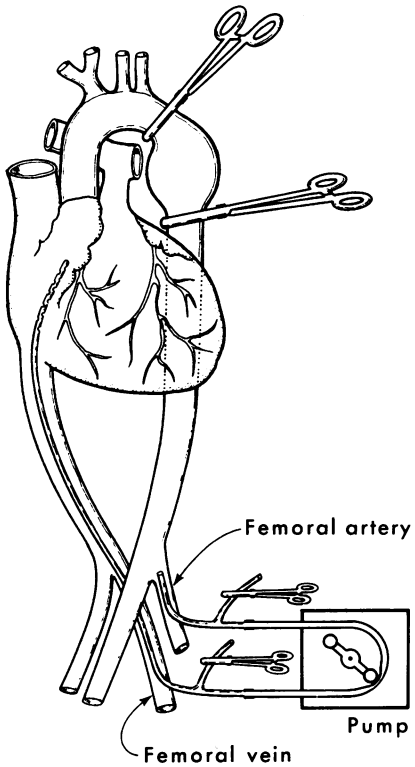

Figure 1.—Venous blood is drained from the right atrium by way of a long 26F cannula and is returned to the femoral artery by a roller pump. The lower part of the body is perfused with mixed venous blood.

TABLE 1.—*Profile of 20 Patients Having Emergency Operative Repair of Proximal Descending Aorta*

Patient	Age, yrs	Sex	Length of Time Injury to OR, h	Associated Major Injuries	Surgical Procedures for Associated Injuries	Significant Complications
1	21	♂	24	Fractured femur	None	Chylothorax; reoperation twice
2	23	♀	8	Massive cerebral contusion	Craniotomy	Died
3	42	♂	48	Multiple rib fractures	Popliteal embolectomy, fasciotomy, below-knee amputation	Pulmonary embolus; popliteal embolus
4	16	♂	12	Cerebral concussion	None	Pneumonia
5	18	♂	12	Ruptured spleen	Splenectomy	None
6	62	♀	12	Flail chest, fractured ankle	Open reduction right ankle	None
7	40	♂	1	Flail chest	None	None
8	26	♂	2	None	None	None
9	17	♂	24	Fractured jaw	None	None
10	25	♀	8	Ruptured spleen, fractured ankle	Splenectomy, open reduction right ankle	Hypertension
11	23	♂	24	Cerebral concussion, dislocation of left hip	Open reduction left hip	None
12	18	♂	8	Left hemopneumothorax, lumbar spine fracture	None	None
13	34	♂	8	Dislocated right knee, liver lacerations	Laparotomy, open reduction right knee	Surgical bleeding requiring reoperation; respiratory insufficiency
14	21	♂	36	Multiple rib fractures, myocardial contusion, ruptured spleen	Splenectomy	Respiratory insufficiency; hypertension
15	23	♀	8	Skull fracture, multiple trauma	Splenectomy; nephrectomy	Died 5 days postoperatively due to head injury
16	15	♂	6	Cranial epidural hematoma; fractured right tibia, fibula	Craniotomy	Pneumothorax, coarctation on anastomotic site
17	18	♂	96	Ruptured bladder; fractured left maxilla, pelvis, both legs	Laparotomy; bladder repair	Pleural effusion; ICU psychosis
18	59	♀	12	Left pneumothorax, fractured pelvis	None	Hypertension
19	24	♂	24	None	None	Anastomotic leak 2 wk postoperatively; reoperation twice; paraparesis 5 days postoperatively
20	21	♀	12	Multiple fractures both legs	None	None

ICU=intensive care unit, OR=operating room

rates ranging from 10% to 29%.[5,6] In contrast, there were no episodes of renal failure or paraplegia in our patients. The one episode of paraparesis that developed several days postoperatively was presumably due to dissection or hematoma formation distal to the surgical site with resulting compromise of spinal cord blood flow.

Because many of these patients had multiple injuries, including intracranial injuries, we have preferred to use techniques that do not require heparin therapy. On the basis of these results, heparinless femoral-femoral venoarterial bypass and simple aortic crossclamping are safe alternatives. With simple aortic crossclamping, however, the crossclamp times should probably be relatively brief because no distal organ protection exists with this technique.

We have preferred the use of HFVAB over aortic shunts that must be inserted into either the aortic arch, the ascending aorta, or the left ventricular apex. When HFVAB is used, the shunt tubing is completely out of the operative field. This obviates the necessity for dissecting mediastinal structures or portions of the aorta not involved with the operative repair. This may be particularly beneficial when an extensive mediastinal hematoma is present or when the patient has active bleeding from the area of aortic disruption. Because the HFVAB shunt tubing involves a long venous catheter, the pump must be kept in a continuous mode to prevent clotting within the tubing in an unheparinized patient. We have had no complications arising from residual thrombosis on either the venous or arterial side following HFVAB.

When possible, particularly in young patients, it is preferable to do a primary repair. Unfortunately, in many cases the aorta may be almost completely transected, and the recoiling of the proximal and distal ends makes it difficult to do a primary repair. Therefore, graft insertion is necessary to avoid tension on the suture lines. The experiences of others suggest that the indications for a primary repair may be expanded.[7]

It is apparent from our series that multiple associated injuries, with the exception of massive intracranial injuries, can often be dealt with effectively. The management of multiple injuries requires setting priorities. Acute intracranial injuries or life-threatening intra-abdominal injuries should be managed initially if the aortic disruption does not appear to be actively bleeding. An avoidance of systemic hypertension during the management of the associated injuries is especially important to prevent extension or rupture of the aortic tear. If active bleeding appears to be occurring from the aortic rupture site, or there is evidence of impending progression of the lesion as shown by increasing pain or compromise of the distal circulation, then the aortic injury should be managed initially. Systemic hypertension should be avoided postoperatively to prevent bleeding or dissection of the aortic repair. An efficient coordination of the various surgical disciplines involved is of the utmost importance to ensure survival of patients with multiple major injuries.

In conclusion, the present-day results of the management of thoracic aortic injuries due to blunt trauma can be associated with a high salvage rate even in the presence of multiple associated injuries. The prompt recognition and management of both the aortic lesion and other major injuries should result in a low incidence of mortality or residual morbidity.

REFERENCES

1. Wakabayashi A, Nakamura Y, Murphy KJ, et al: Heparinless left heart bypass for resection of thoracic aortic aneurysms. Am J Surg 1975; 130:212-218

2. May I, Ecker RR, Iverson LI: Heparinless femoral venoarterial bypass without an oxygenator for surgery on the descending thoracic aorta. J Thorac Cardiovasc Surg 1977; 73:387-392

3. Young JN, Iverson LIG, Ecker RR, et al: The management of descending thoracic aortic aneurysms using heparinless femoral venoarterial bypass. Chest 1981; 79:438-441

4. Stallone RJ, Iverson LI, Young JN: Descending thoracic aortic aneurysm: A ten-year surgical experience. Am J Surg 1981; 142:106-108

5. Sturm JT, Billiar TR, Dorsey JS, et al: Risk factors for survival following surgical treatment of traumatic aortic rupture. Ann Thorac Surg 1985; 39:418-421

6. Turney SZ, Attar S, Ayella R, et al: Traumatic rupture of the aorta: A five-year experience. J Thorac Cardiovasc Surg 1976; 72:727-734

7. Antunes MJ: Acute traumatic rupture of the aorta: Repair by simple aortic crossclamping. Ann Thorac Surg 1987; 44:257-259