adults until further study defines the risks and benefits of this practice. We also suggest reconsideration of labeling guidelines for sorbitol-containing products formulated for pharmacologic effects.

REFERENCES

1. Neuvonen PJ: Clinical pharmacokinetics of oral activated charcoal in acute intoxications. Clin Pharmacokinet 1982; 7:465-489
2. Hill RE, Kamath KR: 'Pink' diarrhea: Osmotic diarrhea from a sorbitol-containing vitamin C supplement. Med J Aust 1982; 1:387-389
3. Berg MJ, Berlinger WG, Goldberg MJ, et al: Acceleration of the body clearance of phenobarbital by oral activated charcoal. N Engl J Med 1982; 307:642-644
4. Berlinger WG, Spector R, Goldberg MT, et al: Enhancement of theophylline clearance by activated charcoal. Clin Pharmacol Ther 1983; 33:351-354
5. Ponds S, Jacobs M, Marks J, et al: Treatment of digitoxin overdose with oral activated charcoal. Lancet 1981; 2:1177-1178
6. Neuvonen PJ, Elonen E: Effect of activated charcoal on absorption and elimination of phenobarbitone, carbamazepine and phenylbutazone in man. Eur J Clin Pharmacol 1980; 17:51-57
7. Rumack BH (Ed): POISINDEX: An Emergency Poison Management System, 48th Ed. Englewood, Colo, Micromedex, 1986
8. Picchioni AL, Chin L, Gillespie T: Evaluation of activated charcoal-sorbitol suspension as an antidote. J Toxicol Clin Toxicol 1982; 19:433-444
9. Levy G: Gastrointestinal clearance of drugs with activated charcoal. N Engl J Med 1982; 307:676-678
10. Spyker PA: Activated charcoal reborn (Editorial). Arch Intern Med 1985; 145:43-44
11. Minocha A, Herold DA, Bruns DE, et al: Effect of activated charcoal in 70% sorbitol in healthy individuals. J Toxicol Clin Toxicol 1984-1985; 22:529-536
12. Epstein FH: Signs and symptoms of electrolyte disorders: Hypernatremia, *In* Maxwell MH, Kleeman CR (Eds): Clinical Disorders of Fluid and Electrolyte Metabolism, 3rd Ed. New York, McGraw-Hill, 1980
13. Osol A, Pratt R, Gennaro AR: United States Dispensatory, 27th Ed. New York, JB Lippincott, 1973, pp 1081-1082
14. Brown JL: Incomplete labeling of pharmaceuticals: A list of 'inactive ingredients.' N Engl J Med 1983; 309:439-441
15. Krenzelok EP, Keller R, Stewart R: Gastrointestinal transit times of cathartics combined with charcoal. Ann Emerg Med 1985; 14:1152-1155

Rhabdomyosarcoma of the Heart with Cerebral Metastases

STANLEY J. GEYER, MD
Seattle, Washington

RHABDOMYOSARCOMA OF THE HEART is a malignant neoplasm composed of cells that display features of striated muscle. This tumor is rare and accounts for less than 5% of all tumors and cysts of the heart and pericardium.[1] Cardiac rhabdomyosarcomas may occur in any of the four chambers of the heart, but a portion of the tumor always involves the myocardium, even when the intracavitary component predominates.[1] The clinical findings are determined by the anatomic location of the tumor and the degree of intracavitary obstruction.[2] The presenting features include congestive heart failure, precordial pain, pericardial effusion, conduction abnormalities, obstruction of the vena cava and sudden death.[2] Surgical treatment is usually not effective against cardiac rhabdomyosarcomas because of the extent of myocardial involvement or the presence of metastases. Because the tumor is rare, most reports consist of a single case or only a few cases and, thus, there are limited descriptions of the sites of metastases from this tumor.

A computer-assisted literature search elicited only one case[3] of cerebral metastases from cardiac rhabdomyosarcoma. In this report I describe the second case of cerebral involvement by this unusual neoplasm and the first case reported in the English language literature.

(Geyer SJ: Rhabdomyosarcoma of the heart with cerebral metastases. West J Med 1987 Nov; 147:596-597)

From the Laboratory Service, Veterans Administration Medical Center, and the Department of Pathology, University of Washington School of Medicine, Seattle.

Reprint requests to Stanley J. Geyer, MD, Veterans Administration Medical Center, 1660 S Columbian Way, Seattle, WA 98108.

Report of a Case

The patient, a 23-year-old man, had the sudden development of a cough productive of brown sputum. He had a systolic murmur and a pericardial friction rub. On radiographic examination there were bilateral pulmonary infiltrates, and a diagnosis of *Mycoplasma pneumoniae* was made. He did well, with resolution of the pneumonia, but one month later pulmonary edema developed. He had a high-pitched, heaving systolic and diastolic murmur.

A chest radiograph showed increased size of the left atrium, and an electrocardiogram revealed sinus tachycardia with nonspecific ST-T changes. An echocardiogram showed a mass in the left atrium, and cardiac catheterization revealed that the mass in the left atrium extended through the mitral valve. The patient underwent right and left atriotomies and atrioseptostomy for resection of the tumor. The tumor arose from the posterior wall of the left atrium. The surgical specimen showed rhabdomyosarcoma, and the margins of the specimen were free of tumor. The resected tumor was 10 by 8 by 6 cm and had a firm, white, fleshy appearance with areas of hemorrhage and necrosis. On microscopic examination of the primary tumor there was a neoplastic proliferation of cells with abundant eosinophilic cytoplasm and large, hyperchromatic nuclei displaying numerous mitoses. Cross-striations characteristic of skeletal muscle differentiation were found in the tumor cells (Figure 1).

The patient did well postoperatively, was evaluated for metastases and found to be free of tumor. He received chemotherapy consisting of cyclophosphamide (Cytoxan), 200 mg, and vincristine sulfate, 2 mg, intravenously per week for 12 weeks and dactinomycin, 0.5 grams, intravenously for 5 days every 3 months. After the 11th postoperative week, the vincristine therapy was discontinued because of tingling in the patient's hands. He received the other chemotherapy without apparent toxicity.

Six months later the patient had throbbing pain in the left pectoral region, shoulder and upper arms. He was admitted to hospital where a workup included a bone scan and multigate analysis (MUGA) scans, which were normal. He continued to

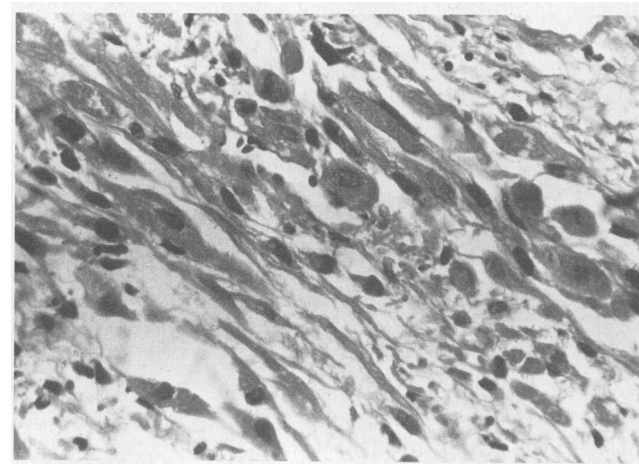

Figure 1.—Tumor cells from the occipital mass contain cross-striations, which identify the tumor as a rhabdomyosarcoma (Hand E, original magnification × 450).

receive chemotherapy and was diagnosed as having the shoulder-hand syndrome. On the third day of hospital stay the patient complained of bumping into objects on his right side and had had loss of vision in the right visual field. The results of a neurologic evaluation were unremarkable except for the loss of vision, and arrangements were made for formal visual field examinations as an outpatient. The patient was discharged to be followed in the outpatient oncology clinic and to continue to receive chemotherapy.

The patient was readmitted two months later when he complained of bifrontal headaches and was noted to have a right temporal field cut. On physical examination on readmission, he had mild anomic aphasia, right hemiparesis and right homonymous hemianopia. He also had bilateral papilledema. A computed tomographic scan showed a hypervascular enhancing mass in the left occipital region with an associated transfalcial shift and trapped left temporal horn (Figure 2). Because it was felt this could be a metastatic mass, the patient was given antiedema agents and anticonvulsant medications. A neurosurgical consultant thought there were several lesions on the scan and that surgical procedures would be of no benefit. The patient had a steady downhill course and, despite continued treatment with antiedema agents and radiation therapy, he became comatose and died a month after readmission. The autopsy examination revealed metastatic rhabdomyosarcoma in the left parieto-occipital lobe with associated severe cerebral edema. There was hemorrhagic necrosis of the central white matter in the left occipital lobe. Tumor also was present in the soft tissue near the aortic arch, in the mesenteric fat as a solitary lesion and in the bone marrow.

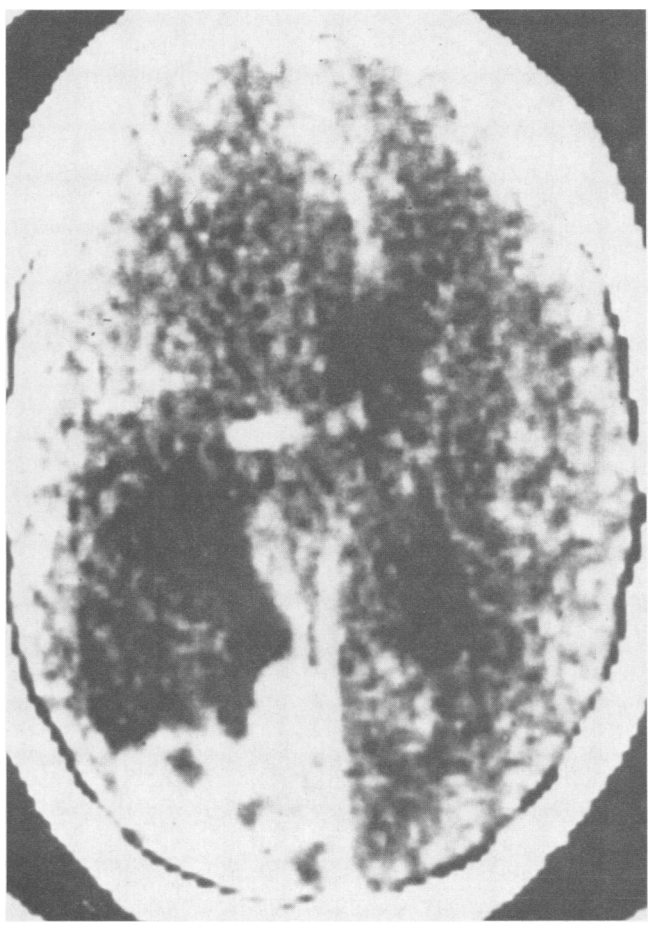

Figure 2.—The computed tomographic scan shows a mass in the left occipital region with a transfalcial shift.

Discussion

This case is only the second reported occurrence of cerebral metastases from a primary cardiac rhabdomyosarcoma. The left atrial location of the tumor and the surgical manipulation to remove it explain the access of the malignant cells to the systemic circulation and thus to the brain and the other sites of metastases found in this patient. Emboli originating in the left side of the heart generally involve the brain, the kidneys and the spleen, so that it is somewhat surprising that metastases in this case were not more widespread. Because primary rhabdomyosarcomas of the heart are rare, the distribution of their metastases is unknown and the likelihood of cerebral involvement is similarly unknown. Common sites of metastases from noncardiac rhabdomyosarcomas, however, are lungs, kidneys, heart, adrenals and mediastinum.[4] Cerebral metastases from rhabdomyosarcomas, regardless of primary site, are generally reported to be rare, although in one study,[5] cerebral metastases were reported in 4 of 15 patients with rhabdomyosarcomas.

Despite their apparent rarity, cerebral metastases should be considered in the differential diagnosis of neurologic symptoms in patients known to have rhabdomyosarcomas. This patient's neurologic problems were attributed initially to factors other than metastases from his cardiac rhabdomyosarcoma, as metastatic sarcoma in the brain is reported to be unusual. In the other reported case of cerebral metastases from a cardiac rhabdomyosarcoma, the patient, a 50-year-old woman with tachycardia and an apical murmur, suffered from what was considered to be multiple strokes. The diagnosis of cerebral metastases from a cardiac rhabdomyosarcoma was not made until the patient died and an autopsy revealed the primary tumor in the left auricle and left ventricle with cerebral metastases.[3] Similarly, a noncardiac rhabdomyosarcoma developed in a 14-year-old girl with neurologic symptoms without radiographic or electroencephalographic evidence of cerebral metastases.[6] The autopsy examination showed a circumscribed metastatic lesion in the frontal region. Cerebral metastases from rhabdomyosarcomas may produce equivocal neurologic signs and symptoms, and the diagnosis of cerebral metastases may not be clear from radiographic examinations. Additional autopsy studies would be helpful in determining the incidence of cerebral metastases from rhabdomyosarcomas and in correlating the presence and distribution of metastatic lesions with neurologic symptoms.

REFERENCES

1. McAllister HA Jr, Fenoglio JJ Jr: Tumors of the Cardiovascular System. Armed Forces Institute of Pathology Atlas of Tumor Pathology, 2nd series, Fascicle 15, 1978, pp 88-95

2. Colucci WS, Braunwald E: Primary tumors of the heart, chap 42, *In* Braunwald E (Ed): Heart Disease—A Textbook of Cardiovascular Disease, 2nd Ed. Philadelphia, WB Saunders, 1984, pp 1457-1469

3. Zhuravlev NV, Cherniaev AL, Boĭko EG: Rhabdomyosarcoma of the heart [Author's trans] Arkh Pathol 1980; 42:73-75

4. Hajdu SI: Pathology of Soft Tissue Tumors. Philadelphia, Lea & Febiger, 1979, pp 325-352

5. Espana P, Chang P, Wiernik PH: Increased incidence of brain metastases in sarcoma patients. Cancer 1980; 45:377-380

6. Kleinhert R, Beham A, Rosanelli G: Alveolar rhabdomyosarcoma in a young female patient metastasizing to the brain. Acta Neuropathol (Berl) 1985; 67:341-344