Articles

Neurologic Complications of Lightning Injuries

MICHAEL CHERINGTON, MD; PHILIP R. YARNELL, MD;
and SCOTT F. LONDON, MD, *Denver, Colorado*

Over the past ten years, we have cared for 13 patients who suffered serious neurologic complications after being struck by lightning. The spectrum of neurologic lesions includes the entire neuraxis from the cerebral hemispheres to the peripheral nerves. We describe these various neurologic disorders with regard to the site of the lesion, severity of the deficit, and the outcome. Damage to the nervous system can be a serious problem for patients struck by lightning. Fatalities are associated with hypoxic encephalopathy in patients who suffered cardiac arrests. Patients with spinal cord lesions are likely to have permanent sequelae and paralysis. New technology for detecting lightning with wideband magnetic direction finders is useful in establishing lightning-flash densities in each state. Florida and the Gulf Coast states have the highest densities. Colorado and the Rocky Mountain states have the next highest.

(Cherington M, Yarnell PR, London SF: Neurologic complications of lightning injuries. West J Med 1995; 162:413-417)

Most serious lightning injuries occur when there is damage to either the cardiovascular or neurologic systems. The nervous system is particularly susceptible to damage from lightning strikes. Despite this vulnerability, a single large series describing the neurologic complications of lightning injuries has not been reported. Because of the sporadic nature of lightning, the literature consists of articles reporting only a few, usually one or two, cases.[1-31] Over the past ten years we have examined and treated 13 patients with neurologic complications following lightning injuries and believe this is the largest single series of such sequelae.

These patients represent a wide spectrum of neurologic problems. Two new cases are reported here. The remaining 11 have been reported previously,[32-34] but these cases will be summarized here to delineate the spectrum of neurologic sequelae from lightning injuries.

Report of Cases

Case 1

The patient, a 57-year-old-man, was struck by lightning while sitting in his golf cart. At the site, he was found to be unconscious and in ventricular fibrillation. After treatment with DC shock and the intravenous administration of lidocaine, epinephrine, and atropine sulfate, his rhythm converted to sinus tachycardia with a rate of 140 beats per minute. He was transported to the hospital, but never regained consciousness. His left tympanic membrane was ruptured. His pupils reacted minimally to light stimulation. He had no volitional movements of his limbs, but did have occasional myoclonic activity in all four limbs. He was diagnosed as having severe hypoxic brain injury due to cardiac arrest and treated with divalproex sodium. A computed tomographic (CT) scan of the brain showed findings consistent with hypoxic encephalopathy (Figure 1). The patient died three days after admission.

Case 2

The patient, a 30-year-old man, walked to his closed glass patio door during an evening lightning storm. The right side of his face was near the glass door. He had an atypical sensation in his right eyebrow that felt like "static electricity" or "crawling ants." A moment later he saw a flash of lightning on his patio. On awakening the next morning, he noticed that he had weakness of the right side of the face, and he could not close his right eye during his morning shower. A neurologic examination four days later revealed an isolated right facial nerve palsy. He did not have any hearing loss, hyperacusis, or abnormalities of taste. Tympanic membranes and gross testing of hearing were normal. Magnetic resonance imaging (MRI) of the brain was normal. At follow-up clinical examination three weeks later, the patient was improved with only mild residual facial weakness. An electromyogram showed abnormalities consistent with an acute neurogenic lesion. Fibrillation potentials were found in muscles supplied by the right facial nerve. He did not return for electrophysiologic evaluation of seventh cranial nerve function.

Discussion

Our 13 patients who suffered neurologic complications after being struck by lightning are listed in Table 1.

From the Lightning Data Center, St Anthony Hospital Central, Denver, Colorado.
Reprint requests to Michael Cherington, MD, Lightning Data Center, St Anthony Hospital, 4231 W 16th Ave, Denver, CO 80204-1374.

ABBREVIATIONS USED IN TEXT

CT = computed tomographic
MRI = magnetic resonance imaging

Cases of neurologic sequelae to lightning strikes described in clinical or neuropathologic detail in the English-language literature are listed in Table 2.[1-31] In addition, neurologic complications were summarized from cases in the European literature (mostly from Germany and France), including the following: Parkinson's disease, 3 cases; cerebellar ataxia, 1 case; spinal amyotrophy, 9 cases; stroke—aphasia, hemiparesis—7 cases.[35]

We excluded from our literature review those patients who had no serious neurologic sequelae, but who may have had one of the following symptoms: transient loss of consciousness, transient amnesia, transient paresis or paresthesias, cataracts or other ophthalmic problems, hearing loss and other eighth nerve problems, or psychological problems. According to some estimates, nearly 75% of all lightning victims suffer a brief period of loss of consciousness, and 80% suffer brief periods of paresthesias or pareses.[7,36,37] Psychological features of lightning strikes have been described elsewhere.[18,38]

With our 13 cases and the cases in the literature in mind, we have addressed the following questions:

- Why do so many cases occur in Colorado?
- Who is likely to suffer a lightning injury with neurologic complications?

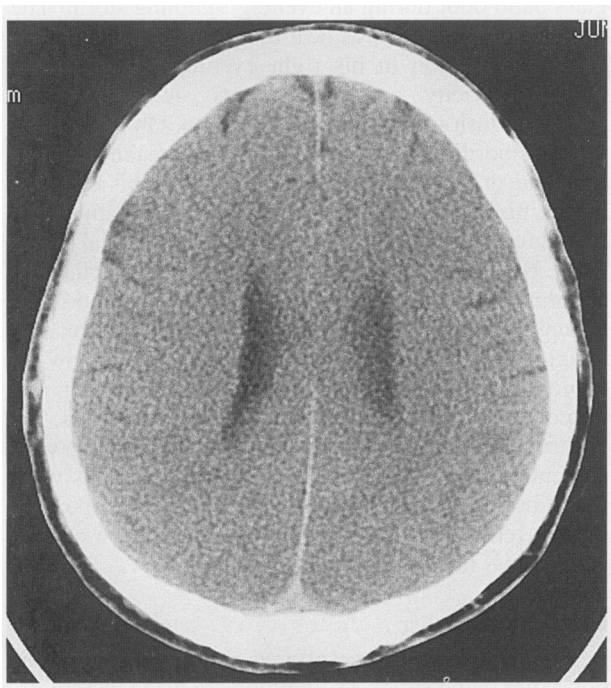

Figure 1.—The brain computed tomographic scan shows loss of gray-white differentiation and absence of sulci, consistent with hypoxic brain injury.

- What is the spectrum of neurologic damage?
- What are the most serious neurologic complications?

Why Do So Many Cases Occur in Colorado?

Colorado has a high lightning-flash density. With the development and use of the wideband magnetic direction finders, the number of cloud-to-ground lightning flashes per unit of time per unit area can be measured.[39] The North American continent is covered by a network of magnetic direction finders that allow for the determination of lightning-to-ground flash density for each state.[40] Florida and the other Gulf Coast states have the highest densities, and Colorado and the Rocky Mountain states have the next highest.[41] The number of lightning injuries and deaths is highest in those states with high lightning-flash density. Furthermore, a recent analysis of numbers of lightning injuries and deaths from several data sources in Colorado elicited even more cases than listed in the National Oceanic and Atmospheric Association's *Storm Data*.[42]

Who Is Likely to Suffer a Lightning Strike With Neurologic Complications?

Our experience closely parallels that in the medical literature with regard to sex and age of lightning victims.Most are men. Only 2 of our 13 patients were women; 7 of the 37 patients in the literature were women. The average age of our 13 patients was 27.2 years with a range of 11 to 64 years. The average age of the patients in the literature was 27.2 years with an age range of 7 to 70 years.

Of our 13 patients, 9 were engaged in outdoor recreational activity when they were struck by lightning. These activities are representative of those listed in the literature.[32,43] Outdoor lightning victims are most often found in two categories: occupational and recreational. Farming, roofing, and ranching are among the more dangerous occupations. High on the list of recreational activities associated with lightning injuries and deaths are golfing, fishing, swimming, boating, camping, hiking, and field sports.

Lightning strikes occur in one of three ways:

- *Direct strike.* This is the most serious type of lightning strike and is usually fatal.
- *Side flash.* This is a much more common form. In this type, lightning first strikes another object, such as a tall tree, and then the current takes the path of least resistance by "flashing" to the person who is standing next to the tree.
- *"Stride potential."* After lightning strikes the ground, electrical current travels along the surface of the earth. If a person happens to be standing in the path of the current with the legs astride, there is likely to be a voltage difference between each foot. The current may then take a path up one leg and down the other. In the case of a rock climber, the current may enter the body

TABLE 1.—*Neurologic Complications of Lightning Strikes*

Case	Age, yr	Sex	Complication	Site	Outcome
1	38	M	Hypoxic encephalopathy	Ski slope	Died
2	11	M	Hypoxic encephalopathy	Football field	Died
3	57	M	Hypoxic encephalopathy	Golf course	Died
4	20	M	Hypoxic encephalopathy	Roof	Impaired
5	33	M	Cerebellar lesion	Tent	Improved
6	64	F	Cerebellar dysfunction	Horse trail	Improved
7	15	M	Cerebellar infarction	Campsite	Improved
8	27	F	Concussion	Metal fence	Prolonged poststress
9	10	M	Concussion; incoordination	Campsite	Improved
10	57	M	Spinal cord lesion	Under tree	Paralyzed
11	16	M	Spinal cord lesion	Campsite	Paralyzed
12	21	M	Spinal cord lesion	Work site	Paralyzed
13	31	M	Cranial nerve VII injury	Near window	Improved

through an arm touching a boulder and exit through the lower extremities.

In addition to sustaining damage from the primary effects of lightning, patients are vulnerable to secondary injuries from direct physical trauma. Physical trauma should be considered in patients who suffer secondary fractures of the head and cervical trauma from falling if they are rendered unconscious. Patients may also be injured from falling debris such as broken tree trunks. Clinicians should also be aware of blast injuries resulting from the explosive forces associated with thunder. Ruptured tympanic membranes are the most common blast injuries found in lightning victims.

Although cardiac and neurologic damage is responsible for most of the morbidity and mortality of lightning victims, other organ systems are also vulnerable. Clinicians must be aware of other complications including rhabdomyolysis, renal failure, adult respiratory distress syndrome, pulmonary edema, cataracts, uveitis, and retinal lesions.[30,44,45]

Many of the abnormalities seen in lightning victims resemble those that occur in patients who suffer electric shock from generated high-voltage-electricity accidents. There are some differences, however. Those injured from electrical accidents are more likely to have severe burns, rhabdomyolysis, muscle necrosis, deep tissue damage, and gangrene. As a result, they are more likely to suffer renal failure and to need surgical amputation of limbs.

The reason for these more severe burns and tissue necrosis in electrical accidents relates to the longer duration of exposure to alternating current compared with the brief exposure to the direct current of lightning. Alternating current at 60 Hz tends to cause tetanic muscle spasms. When this happens, patients may be unable to release their grip from the power source, and therefore the duration of contact is increased. The ultimate degree of injury in either lightning or technical electrical trauma is related to the amount of current, the time of passage, the path of the current, and the resistance of the specific tissue.[11,32,46]

What Is the Spectrum of Neurologic Damage?

The cases already described in the literature involved lesions of the entire neuraxis. Our experience is consistent with those reports. We have treated patients with

TABLE 2.—*Literature Review of Lightning Neurologic Sequelae*

Case	Age, yr	Sex	Neurologic Sequelae	Reference
1	--*	M	Seizures	Critchley, 1934[1]
2	38	F	Wilson's disease	Young, 1934-1935[2]
3	52	M	Parkinson's disease	Langworthy, 1936[3]
4	38	F	Hemiparesis	Draper, 1937[4]
5	39	M	Extrapyramidal syndrome	Paterson and Turner, 1944[5]
6	28	M	Small cerebral hemorrhages	Lynch and Shorthouse, 1949[6]
7	18	M	Small cerebral hemorrhages	Lynch and Shorthouse, 1949[6]
8	51	M	Intracranial hemorrhage	Arden et al, 1956[7]
9	52	M	Epidural hematoma	Morgan et al, 1958[8]
10	10	M	Seizures	Ravitch et al, 1961[9]
11	15	M	Anoxic encephalopathy	Hanson and McIlwraith, 1973[10]
12	68	M	Parkinson's disease	Apfelberg et al, 1974[11]
13	15	M	Cerebral edema	Kravitz et al, 1977[12]
14	14	F	Cerebral edema	Myers et al, 1977[13]
15	7	F	Cerebral hypoxia	Myers et al, 1977[13]
16	15	F	Spinal atrophy	Myers et al, 1977[13]
17	21	M	Subarachnoid hemorrhage	Strasser et al, 1977[14]
18	25	M	Myelopathy	Sharma and Smith, 1978[15]
19	26	M	Cerebellar syndrome	Suri and Vijayan, 1978[16]
20	10	M	Seizures	McCrady-Kahn and Kahn, 1981[17]
21	11	M	Cerebellar ataxia	Kotagal et al, 1982[18]
22	9	M	Cerebral edema	Kotagal et al, 1982[18]
23	29	M	Cerebral infarct	Krob and Cram, 1983[19]
24	46	M	Truncal ataxia	Krob and Cram, 1983[19]
25	34	M	Cerebral edema	Krob and Cram, 1983[19]
26	20	M	Intracranial hemorrhage	Mann et al, 1983[20]
27	21	M	Hemiparesis	Peters, 1983[21]
28	31	F	Median nerve lesion	Amy et al, 1985[22]
29	22	M	Basal ganglia hematoma	Stanley and Suss, 1985[23]
30	15	M	Parietal infarct	Frayne and Gilligan, 1987[24]
31	22	M	Progressive myelopathy	Davidson and Deck, 1988[25]
32	58	M	Cerebellar syndrome	Morocutti et al, 1989[26]
33	70	F	Bulbar palsy	Saddler and Thomas, 1990[27]
34	45	M	Sagittal sinus occlusion	Lehman, 1991[28]
35	36	M	Autonomic failure	Weeramanthri et al, 1991[29]
36	19	M	Polyneuropathy	Hawkes and Thorpe, 1992[30]
37	15	M	Intracranial hematoma	Steinbaum et al, 1994[31]

*Age not given.

lesions involving the neocortex, cerebellum, spinal cord, and peripheral nerve.

The neuropathy of lightning injuries was described 60 years ago.[1] The neuropathologic findings of the central nervous system include the following: focal petechial hemorrhages and chromatolysis of pyramidal cells, Purkinje's cells of the cerebellum, and anterior horn cells. The most striking pathologic abnormality of peripheral nerves is a localized ballooning of myelin sheaths. The introduction of imaging techniques (MRI and CT scans) has given clinicians an ability to learn about the site and characteristics of these lesions that previously could be learned only at postmortem examinations.

Both our experience and that reported in the literature are similar in showing that central nervous system lesions are much more common than peripheral nerve lesions. Lesions of the brain are the most common neurologic complications. These lesions include the following processes: cerebral infarction, hypoxic encephalopathy often due to cardiac arrest, basal ganglial degeneration, and intracranial hematoma. Myelopathies and cerebellar lesions occur less often. Peripheral nerve lesions are most uncommon in our experience and are rarely reported in the literature. We saw only one patient with a cranial nerve lesion. He had an isolated facial nerve lesion, which is rare following a lightning strike. The largest number of cases of spinal amyotrophy are detailed in the European literature.[35]

Brief sympathetic nervous system instability characterized by pulseless, cyanotic, and weak extremities is common in victims of lightning strikes. These signs, along with tachycardia and hypertension, resolve in a matter of minutes or hours and are the result of increased catecholamine release.[12] The term "keraunoparalysis" has been used for the short-lived limb weakness associated with this hyperadrenergic state.[30] Permanent dysfunction of the sympathetic nervous system as the result of lightning injuries is much less common.[29,30]

Delayed neurologic syndromes have been described rarely after both lightning and electrical trauma.[1,35] These delayed syndromes (myelopathy and spinal muscular atrophy) are reported to occur days, weeks, and even months after the electrical trauma. The mechanism is unknown. In an article on the delayed syndromes in patients with electrical injuries, it was speculated that exposure to electric fields is similar to the effects of irradiation.[47] That there is a cause and effect between electrical trauma and a delayed pathologic response in lightning strike victims has yet to be proved. With regard to the possibility that delayed and progressive syndromes can be caused by lightning and electrical trauma, the following caution has been offered[48(p236)]:

> The attempt to link together a series of alleged facts or assumptions, each improbable in a particular degree, as the basis for a conclusion, contrary to the cumulative mathematical chances, may lead to serious error, whether or not it is honestly or sincerely arrived at.

What Are the Most Serious Neurologic Complications?

Three of our patients died; all had severe hypoxic encephalopathy after suffering cardiac arrest. Two were struck at high elevations in the Rocky Mountains. One was skiing in April; the other was struck in June while sitting in a golf cart. The third was a child who was struck while playing football. The cerebral edema evident by imaging studies in our patients is a posthypoxic, cytotoxic edema due to cardiac arrest.[49]

The surviving ten patients can be divided into three groups based on the level of their neurologic lesions:

- *Lesions above the foramen magnum.* All of these patients suffered an initial major insult. All of them eventually recovered, however. The lesions included cerebral infarction and cerebellar atrophy. The patient with cerebellar atrophy is of particular interest because the MRI uncovered atrophy of the cerebellar vermis within days after the lightning strike. This first case of a cerebellar syndrome after lightning strike, verified by MRI, provided evidence of possible rapid degeneration of the cerebellum.
- *Cranial nerve palsy.* One patient had an ipsilateral seventh nerve palsy, which subsequently abated.
- *Spinal cord lesions.* These patients were all left with a major deficit such as paralysis and did not return to their normal preinjury state.

REFERENCES

1. Critchley M: Neurological effects of lightning and of electricity. Lancet 1934; 1:68-72

2. Young JD: Bilateral lenticular degeneration with the possibility of an electrical burn acting as an etiological factor. N Orleans Med Surg J 1934-1935; 87:541-544

3. Langworthy OR: Neurological abnormalities produced by electricity. J Nerv Ment Dis 1936; 84:13-26

4. Draper PA: Neuro-psychiatric effects of electric trauma. Colo Med 1937; 34:650-653

5. Paterson JH, Turner WA: Lightning and the central nervous system. J R Army Med Corp 1944; 82:73-75

6. Lynch MJG, Shorthouse PH: Injuries and death from lightning. Lancet 1949; 1:473-478

7. Arden GP, Harrison SH, Lister J: Lightning accident at Ascot. Br Med J 1956; 1:1450-1453

8. Morgan ZV, Headley RN, Alexander EA, et al: Atrial fibrillation and epidural hematoma associated with lightning stroke. N Engl J Med 1958; 259:956-959

9. Ravitch MM, Lane R, Safar P, et al: Lightning stroke: Reports of a case with recovery after cardiac massage and prolonged artificial respirator. N Engl J Med 1961; 264:36-38

10. Hanson GC, McIlwraith GR: Lightning injury: Two case histories and a review of management. Br Med J 1973; 4:271-274

11. Apfelberg DB, Masters FW, Robinson DW: Pathophysiology and treatment of lightning injuries. J Trauma 1974; 14:453-460

12. Kravitz H, Wasserman MJ, Valaitis J, et al: Lightning injury: Management of a case with ten-day survival. Am J Dis Child 1977; 131:413-415

13. Myers GJ, Colgan MT, VanDyke DH: Lightning strike disaster among children. JAMA 1977; 238:1045-1046

14. Strasser EJ, Davis RM, Menchey MJ: Lightning injuries. J Trauma 1977; 17:315-319

15. Sharma M, Smith A: Paraplegia as a result of lightning injury. Br Med J 1978; 2:1464-1465

16. Suri ML, Vijayan GP: Neurological sequelae of lightning (a case report). J Assoc Physicians India 1978; 26:209-212

17. McCrady-Kahn VL, Kahn AM: Lightning burns. West J Med 1981; 134:215-219

18. Kotagal S, Rawlings CA, Chen S, et al: Neurologic, psychiatric, and cardiovascular complications in children struck by lightning. Pediatrics 1982; 70:190-192

19. Krob MJ, Cram AE: Lightning injuries: A multisystem trauma. J Iowa Med Soc 1983; 6:221-225

20. Mann H, Kozic Z, Boulos MI: CT of lightning injury. AJNR 1983; 4:976-977

21. Peters WJ: Lightning injury. Can Med Assoc J 1983; 128:148-150

22. Amy BW, McManus WF, Goodwin CW Jr, Pruitt BA Jr: Lightning injury with survival in five patients. JAMA 1985; 253:243-245

23. Stanley LD, Suss RA: Intracerebral hematoma secondary to lightning stroke: Case report and review of the literature. Neurosurgery 1985; 16:686-688

24. Frayne JH, Gilligan BS: Neurological sequelae of lightning strikes. Clin Exp Neurol 1987; 24:195-200

25. Davidson GS, Deck JH: Delayed myelopathy following lightning strike: A demyelinating process. Acta Neuropathol 1988; 77:104-108

26. Morocutti C, Spadaro M, Amabile G: TRH treatment in cerebellar ataxia following a lightning stroke (Letter). Ital J Neurol Sci 1989; 10:531

27. Saddler MC, Thomas JE: Temporary bulbar palsy following lightning strike. Cent Afr J Med 1990; 36:161-162

28. Lehman LB: Successful management of an adult lightning victim using intracranial pressure monitoring. Neurosurgery 1991; 28:907-910

29. Weeramanthri TS, Puddey IB, Beilin LJ: Lightning strike and autonomic failure—Coincidence or causally related? J R Soc Med 1991; 84:687-688

30. Hawkes CH, Thorpe JW: Acute polyneuropathy due to lightning injury. J Neurol Neurosurg Psychiatry 1992; 55:388-390

31. Steinbaum S, Harviel JD, Jaffin JH, et al: Lightning strike to the head: Case report. J Trauma 1994; 36:113-115

32. Cherington M, Yarnell P, Lammereste D: Lightning strikes: Nature of neurological damage in patients evaluated in hospital emergency departments. Ann Emerg Med 1992; 21:575-578

33. Cherington M, Yarnell P, Hallmark D: MRI in lightning encephalopathy. Neurology 1993; 43:1437-1438

34. Cherington M, Martorano FJ, Siebuhr LV, et al: Childhood lightning injuries on the playing field. J Emerg Med 1994; 12:39-41

35. Panse F: Electrical trauma, *In* Vinken PJ, Bruyn CW (Eds): Handbook of Clinical Neurology. Amsterdam, The Netherlands, North-Holland Publishing, 1975, pp 683-729

36. Cooper MA: Lightning injuries: Prognostic signs for death. Ann Emerg Med 1980; 9:134-138

37. Epperly TD, Stewart JR: The physical effects of lightning injury. J Fam Pract 1989; 29:267-272

38. Dollinger SJ: Lightning-strike disaster among children. Br J Med Psychol 1985; 58(pt 4):375-383

39. Lopez RE, Holle RL: Diurnal and spatial variability of lightning activity in northeastern Colorado and central Florida during the summer. Monthly Weather Rev 1986; 114:1288-1312

40. Orville RE: Lightning ground flash density in the contiguous United States—1989. Am Meteorol Soc 1991; 119:573-577

41. Duclos PJ, Sanderson LM: An epidemiological description of lightning-related deaths in the United States. Int J Epidemiol 1990; 19:673-679

42. Lopez RE, Holle RL, Heitkamp TA, et al: The underreporting of lightning injuries and deaths in Colorado. Bull Am Meteorol Soc 1993; 74:2171-2178

43. Cherington M, Vervalin C: Lightning injuries—Who is at greatest risk? Physician Sportsmed 1990; 18:58-61

44. Noel LP, Clarke WN, Addison D: Ocular complications of lightning. J Pediatr Ophthalmol Strabismus 1980; 17:245-246

45. Hayashi Y, Aihara T, Takano H, et al: Unilateral perihilar opacification caused by lightning. Pediatr Radiol 1993; 23:559-560

46. Dendooven AM, Lissens M, Bruynincky F, Vanhecke J: Electrical injuries to peripheral nerves. Acta Belg Med Phys 1990: 13:161-165

47. Farrell DF, Starr A: Delayed neurological sequelae of electrical injuries. Neurology 1968; 18:601-606

48. Hyslop GH: Effects of electrical injuries with particular reference to the nervous system. Occup Med 1946; 1:199-236

49. Bird CR, Drayer BP, Gilles FH: Pathophysiology of 'reverse' edema in global cerebral ischemia. AJNR 1989; 10:95-98